

Omental torsion: a case report

Chaudhary D¹, Rajkarnikar R¹, Joshi MR², Thapa P², Singh DR³, Sharma SK⁴

¹HO, ²Lecturer, ³Consultant Surgeon, ⁴HoD, Department of Surgery, Kathmandu Medical College Teaching Hospital

Abstract

Omental torsion is a rare cause of acute abdomen. Most often it presents with sign and symptoms of acute appendicitis. It is seldom considered in the differential diagnosis preoperatively based on clinical findings and the diagnosis is only established during surgery. We present a case of omental torsion in a middle aged male patient who presented with findings suggestive of appendicular perforation and underwent emergency laparotomy.

Key words: acute abdomen, omentum, torsion, appendicitis

Torsion of the omentum is a condition in which the organ twists along its long axis to such an extent that its vascularity is compromised. Although omental torsion is rarely diagnosed preoperatively, knowledge of the entity is important to the surgeon because it mimics the common causes of acute surgical abdomen.

Case report

A Forty year old male presented to Kathmandu Medical College Teaching Hospital emergency room with the complaints of pain abdomen since four days. According to the patient, pain initially started around the central abdomen. However since the last one day it got diffuse and more severe towards the right lower abdomen. This was associated with loose motion of 15-20 episodes, vomiting and mild fever. There was also a history suggestive of reducible right inguinal hernia since the last one year.

On physical examination, he was ill looking with pyrexia of 101⁰ F, was dehydrated, tachycardic and mildly icteric. Abdomen was distended with guarding and rigidity. It was diffusely tender with maximum tenderness around right lower abdomen. Rebound tenderness was present throughout. Bowel sound was sluggish. Hernial sites looked normal with no bulging and cough impulse was absent.

Blood investigations revealed neutrophilic leucocytosis and slightly raised bilirubin level. Other investigations including abdominal X-ray was within normal limit. The diagnosis of appendicular perforation was made and planned for exploratory laparotomy. Prior to his arrival at KMCTH, he was also seen at another private hospital, where he was diagnosed as appendicitis and planned for appendectomy.

Midline laparotomy was performed.

There was haemorrhagic fluid collecting in the peritoneal cavity. Greater omentum was rotated

around its longitudinal axis at the base with 3 complete rotations making a knot. The knot and the omentum distal to it was black showing necrosis (Fig. 1). Tip of the omentum was adherent around right hernial orifice internally. Hernial sac was empty. Other organs including appendix was normal. Omentectomy was performed and peritoneal lavage was done. Herniorrhaphy was done through right inguinal approach.

Post operative period though uneventful was prolonged due to post operative ileus persisting for 5 days. Patient was discharged on the 7th post operative day. Histopathological examination revealed infarcted omentum.

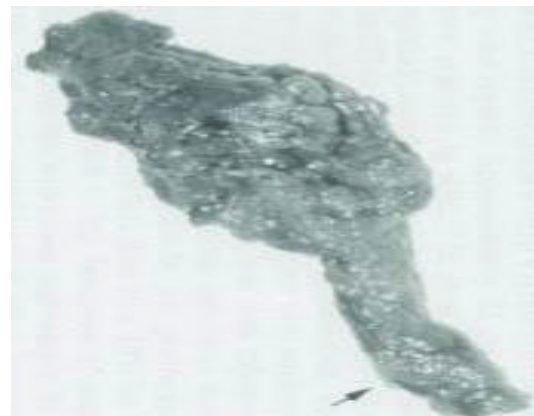


Fig. 1

Discussion

Omental torsion is of two types- primary and secondary. Primary omental torsion was first described by Eitel in 1899¹ and since then, fewer than 250 cases have been reported.

Correspondence

Dr. Dipendra Chaudhary,
Kathmandu Medical College, Sinamangal, Kathmandu
E-mail: dipen262@gmail.com

The aetiology of primary torsion is unknown, but several predisposing factors have been described e.g. anatomical variations including tongue like projections from the free edge of the omentum, bifid omentum, accessory omentum². Judy et al in their article describe that obesity is an important risk factor for omental torsion in children³.

Precipitating factors are those that cause displacement of the omentum e.g. heavy exertion, sudden change in body position, coughing, straining and hyperperistalsis². Secondary omental torsion is due to an acquired attachment following hernia repair, a surgical scar, tumours or perforated bowel⁴. Our case was secondary to adhesions around the hernial orifice. The greater omentum, which is a two layered fold of peritoneum between the greater curvature of the stomach and the transverse colon, has no attachments except on its superior aspect, hence is very mobile. Torsion is usually caused by partial or total rotation around its main axis, causing compromised perfusion of the omentum and infarction⁵. The right side of the omentum is more prone to torsion due to its larger size.

The clinical symptoms of omental torsion are of acute abdomen and are due to ischemia and infarction. It can mimic other acute abdominal states such as acute appendicitis, cholecystitis, and torsion of appendix epiploica or diverticulitis⁵. Goti et al reported that symptoms simulate acute appendicitis in 66% of cases and cholecystitis in 22%. Progressive peritonitis usually dictates laparotomy and an accurate diagnosis is rarely made before surgery⁷. Left sided primary omental torsion could possibly be diagnosed as acute diverticulitis and managed non-operatively. Hence, left sided torsion may be seldom seen because they are less often operated on and less frequently diagnosed⁸. The diagnosis based on clinical signs and physical examination alone is difficult and in most of the reported cases is established at laparotomy^{5,9}.

Clinically, primary and secondary torsion of the omentum are similar and occur in the fourth and fifth decades, males being affected twice as commonly as females. The most frequent presentation is pain in the right iliac fossa which is usually sudden in onset, and is constant with a gradual increase in severity as in our case. There may be a past history of similar but less severe pain¹⁰. Nausea and vomiting occur in less than 50% of cases. Moderate leucocytosis and fever are usually present. Tenderness with peritonism is invariably present. A mass may be felt if a large segment of omentum is involved². Escartin Villacampa et al in their retrospective review of 15

cases of omental torsion describe that, symptomology was similar to that of acute appendicitis with certain peculiarities such as a longer period of evolution at the moment of diagnosis, lower temperature and leucocytosis lower than would be expected in appendicitis at the same time of evolution and absence of vomiting¹¹.

Ultrasound shows an echogenic and non-compressible oval-shaped mass adherent to the abdominal wall in the region of maximum tenderness. CT-scan is very sensitive for showing an omental mass but not specific for making a diagnosis of torsion¹². Classical signs of omental torsion on CT scan are of a hazy fatty mass with concentric linear strands in the greater omentum, as described by Ceuterick et al¹³ (Fig. 2). These strands are twisted blood vessels whirling around a central rod. However, there are other differential diagnosis of hazy fatty mass with associating stranding, such as omental hernia, inflammation of epiploic appendages, pancreatitis and fat containing neoplasms⁵.

Treatment consists of resecting the infarcted omentum and treating the underlying etiological condition in patients with secondary omental torsion. Miguel Perello et al stressed on the greater use of USG and CT-scan in the emergency department leading to preoperative diagnosis and hence avoiding surgery in selected patients.

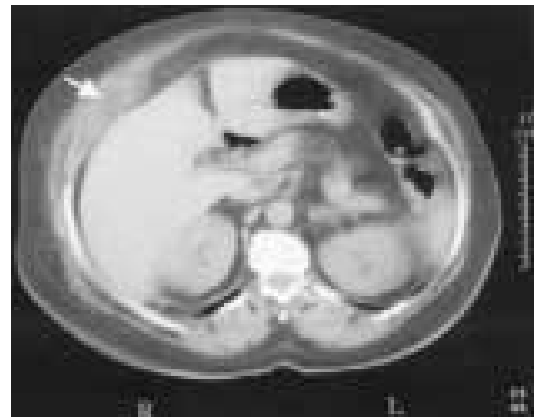


Fig. 2 Unenhanced CT scan through upper abdomen demonstrating a mixed fatty density, between the liver and the anterior abdominal wall, with curved linear densities (arrow).

Conservative management in selected cases of acute abdomen diagnosed as primary omental torsion is also advised¹⁴. Performance of diagnostic laparoscopy for acute abdominal pain of an undetermined origin may lead to an increased

detection of this condition and subsequent therapeutic intervention. Laparoscopic management of primary omental torsion has also been described in literature¹⁵.

Conclusion

Omental torsion may be much more common than the number of case reported in the literature. The condition should be considered in the differential diagnosis of acute abdomen. Even though it is a rare condition which presents with diagnostic difficulties preoperatively it poses no problems of a therapeutic nature.

References

1. Eitel GG. Rare omental torsion. *N Y Med Rec* 1899; 55:715-6.
2. Leitner MJ, Jordon CG. Torsion, infarction and haemorrhage of the omentum as a cause of acute abdominal distress. *Ann Surg* 1952; 135: 103.
3. Judy A Theriot, Jon Sayat et al. Childhood Obesity: A Risk Factor for Omental Torsion. *Pediatrics* 2003; 112(6): 460-62
4. Cervellione RM, Camoglio FS, Bianchi S et al. Secondary omental torsion in children: report of two cases and review of the literature. *Pediatr Surg Int* 2000; 18(2): 184-6
5. Eli Atar, Pearl Herskovitz et al. Primary greater Omental Torsion: CT Diagnosis in an Elderly Woman *IMAJ* 2004; 6: 57-58
6. Lipsett PJ. Torsion of the greater omentum: report of 2 cases. *Ann Surg* 1941; 114: 1026-34
7. Goti F, Hollmann R, Stieger R, Lange J. Idiopathic segmental infarction of the greater omentum successfully treated by laparoscopy: report of case. *Surg Today* 2000; 30(5): 451-3
8. Basson SE, Jones JA. Primary torsion of the omentum. *Ann Coll Surg Engl* 1981; 63: 132-4
9. Karayiannakis AJ, Polychronidis A, Chatzigianni E, Simopoulou. Primary torsion of the greater omentum: report of a case. *Surg Today* 2002; 32(10): 913-15
10. R Jeganathan, E Epanomeritakis, T Diamond. Primary torsion of the Omentum. *Ulster Medical Journal* 2002; 71(1):L 76-77
11. Escartin Villacampa R, Elias Pollina J, Esteban Ibarz JA. Primary torsion of the greater omentum. *An Esp Pediatr* 2001 March; 54(3): 251-4
12. Cooper C, Jeffrey RB, SilvermanM, FedeleMP, Chur GH. Computed tomography of omental pathology. *J Comput Assist Tomogr* 1986; 10: 62
13. Ceuterick I, Baert AL, Marchal G et al. CT diagnosis of primary torsion of greater omentum. *J Comput Assist Tomogr* 1987; 11: 1083-4
14. Miguel Perello J, Aguayo Albasini JL et al. Omental torsion: imaging techniques can prevent unnecessary surgical interventions. *Gastroenterol Hepatol.* 2002 Oct; 25(8): 493-6
15. Steyaert H, Valla JS. Laparoscopic approach to primary infarction of the greater omentum. *Surg Laparosc Endosc.* 1997 Apr; 7(2): 97-8
16. Tompkins RK, Sparks FC: Primary torsion of the omentum: mimic of appendicitis. *Am Surg* 1966; 32: 399-402.
17. Zager JS, Gadaleta D, De Noto G: Primary omental torsion in adults: a small series of cases. *Contemp Surg* 1999; 55;5: 261-63.