

Assessment of The Relationship of Incisive Papilla to Maxillary Central Incisor and Canine-Papilla-Canine Line among the Dentate population of Central Nepal

Sapkota B, Chettiar RS, Srivastava S, Marla V, Koju S

Department of Dentistry
Kathmandu University School of Medical Sciences
Dhulikhel, Nepal

Corresponding Author

Binam Sapkota
Department of Dentistry
Kathmandu University School of Medical Sciences
Dhulikhel, Nepal.
E-mail: drdilislam@gmail.com

Citation

Sapkota B, Chettiar RS, Srivastava S, Marla V, Koju S. Assessment of The Relationship of Incisive Papilla to Maxillary Central Incisor and Canine-Papilla-Canine Line among the Dentate population of Central Nepal. *Kathmandu Univ Med J Online First*.

ABSTRACT

Background

Incisive papilla has been used as a fixed anatomical landmark to guide in teeth arrangement.

Objective

To assess the relationship of distance from central incisor to incisive papilla with various types of arch forms, shapes of incisive papilla and types of canine-papilla-canine relation.

Method

Two hundred maxillary stone casts were prepared. Eighteen casts were excluded as they had voids and the final study was carried out in 182 participants. The arch form was assessed according to Testut L. and shape of incisive papilla was recorded according to Filho IE et al. A digital Vernier caliper was used to measure the distance from posterior point of incisive papilla to the mesio-incisal edge from the labial side of maxillary central incisor. The inter-canine line was drawn and its position with incisive papilla was assessed. The analysis was done using SPSS version 20.0. One way ANOVA was done.

Result

Result showed that parabolic type of arch was the most common i.e. 76.4%. Mean distance of central incisor to incisive papilla was 11.093 ± 1.894 mm. No significant difference was observed in the distance of Central incisor to Incisive Papilla among different arch forms ($p=0.854$) and various shapes of incisive papilla ($p=0.091$). The mean distance of central incisor to incisive papilla was significantly greater when canine-papilla-canine line passed from the middle than from posterior part of incisive papilla.

Conclusion

These results suggest that incisive papilla is a reliable biometric guide which would help to reduce the clinical time of both the dentist and the patients in placement of the anterior teeth.

KEY WORDS

Central incisors, canine-papilla-canine line (CPC), incisive papilla (IP)

INTRODUCTION

Restoration of the natural appearance of an edentulous patient is a vital part of prosthodontic treatment. Rehabilitation through prosthodontic treatment following the loss of teeth has become an essential part to improve the quality of life of patients.¹ The position of tooth plays an important role in restoring the appearance in the edentulous state. Hence, for the proper positioning of denture teeth, to achieve a proper speech, lip support, and harmonious incisal guidance certain anatomical landmarks are required, which are called as biometric guides. Some of the proposed biometric guides are labial gingival margin, incisive papilla (IP), canine-papilla -canine (CPC) line, scar line and the inner surface of maxillary denture border corresponding to cephalometric point subspine.² Among these biometric guides, the most reliable anatomical landmark is the incisive papilla. It covers the incisive foramen and is located on median line behind and between central incisors (CI). Many authors have proposed that the incisive papilla remains at a constant position even after tooth loss.¹ Watt et al. pointed out that as a result of alveolar ridge resorption following extraction of upper anterior teeth the papilla moved forward about 1.6 mm and 2.3 mm upward. To compensate for this alteration, they suggested using the posterior border of the papilla as it appears to be intact.^{3,4}

The labial fullness of maxillary anterior edentulous ridge is dependent on alveolar resorption and bone remodeling following the extraction of upper anterior teeth.⁵ Alveolar resorption and atrophy cause the lip to move inward resulting in loss of facial contour.⁶ The horizontal relationship between the incisive papilla and the maxillary central incisors in a dentulous individual serves as a guide to position the central incisor as nearly as possible to their original location and restore labial contour in edentulous subjects.⁷ Some studies have also suggested that shape of IP affects the distance between CI and IP and the shape and location of the papilla show a wide range of variation between the individuals.^{8,9}

The present study aims to assess the relationship of distance from central incisor to incisive papilla with various types of arch forms, shapes of incisive papilla and types of canine papilla canine relation.

METHODS

This cross sectional study was conducted in the Dental Department of Dhulikhel Hospital, Kathmandu University Hospital. A total of 200 subjects were selected by random sampling. Dentulous individuals between 20 to 40 years with fully erupted permanent teeth, no anterior tooth restoration, Angle's Class I molar relation were included in the study. Individuals with partially edentulous maxillary arch, individuals with the past or current history of orthodontic treatment and those who refused to participate were excluded.

Maxillary jaw impression of 200 study participants (49 males and 151 females) was made using metallic stock impression tray and irreversible hydrocolloid impression material following the manufacturer's instructions. In order to record the incisive papilla and soft tissues properly, the impression was made under minimal pressure. Impression was poured with Type III dental stone using a dental vibrator and allowing it to set according to the manufacturer's instructions. Any defect like voids or air bubbles were examined and those casts were excluded (n=18). Therefore, the study was carried out in 182 casts. Standardization was done by making the base of the cast using a base former.

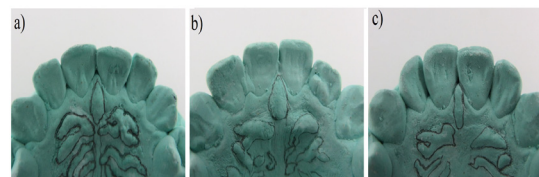


Figure 1. Shape of incisive papilla; a) Elliptical, b) Triangular, c) Thin



Figure 2. Digital Vernier Caliper

The arch form was then assessed on the cast and recorded according to Testut L.¹⁰ The incisive papilla was identified and then its boundaries were marked by using an HB bonded lead pencil. According to Filho et al. it was evaluated as elliptical (egg-shaped, larger than longer); triangular (triangular-shaped with the vertex directed toward the incisors); or thin (thin and narrow shape) (fig. 1).¹¹ The anterior, middle and posterior point of incisive papilla were also marked along with the tip of the canine and mesio-incisal edge from the labial side of the maxillary central incisor. A digital Vernier caliper (fig. 2) was used to measure the distance from the posterior point of incisive papilla to the mesio-incisal edge from the labial side of maxillary central incisor (fig. 3). The mean of three readings was recorded to decrease the measuring error. A scale was placed horizontally from tip of one canine to next canine forming the CPC line and its orientation was assessed with relation to the incisive papilla as posterior, middle and anterior to CPC.(fig. 4).

All the measurements were made by a single investigator. Statistical analysis was performed using SPSS version 20.0. Level of significance was set at $p=0.05$. Normality was checked using Shapiro Wilk test and the data was found

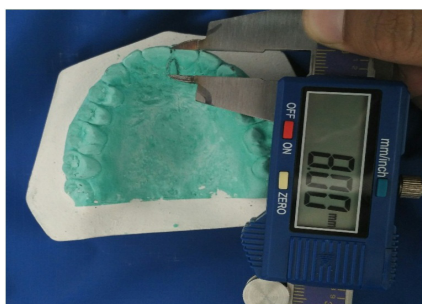


Figure 3. Measurement of distance from posterior point of incisive papilla to the mesio-incisal edge from labial side of maxillary central incisor

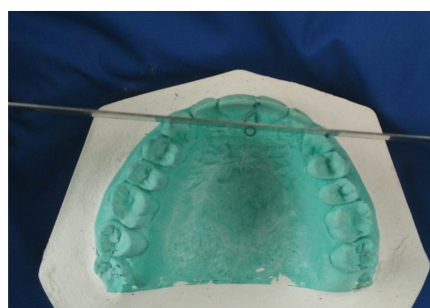

Figure 4. CPC line and its orientation with relation to the incisive papilla

to be normally distributed. One way ANOVA was used to assess the relationship of distance from central incisor to incisive papilla (continuous variable) with various (categorical variable): 1. type of arch forms (parabolic, ellipsoidal and hyperbolic), 2. The shape of incisive papilla (elliptical, thin and triangular) and 3. Type of canine papilla canine relation (anterior, middle and posterior).

RESULTS

Mean distance of central incisor to incisive papilla was 11.093 mm with a standard deviation of 1.894 mm. 95% Confidence interval lies between 10.816 mm and 11.370 mm. The results of the study are shown in table 1-4.

One way ANOVA revealed that there were three types of arch form in our study (Table 1), out of which parabolic type was the most common i.e. 76.4% and least common was ellipsoidal i.e. 8.2%. Measurement of CI to the posterior border of IP among all three forms of arch showed almost similar mean distance from CI to IP with p value= 0.854 (Table 1) which showed no significant differences of CI to IP distance among different arch form.

Similarly, three different shapes of IP were seen, out of which the most common was the triangular shape (47.3%) and thin one being the least (19.8%) (Table 2). One way ANOVA test showed that the distance of central incisor to incisive papilla was not affected by the shape of the incisive papilla. No significant difference was seen (p=0.091).

Among the 182 participants, 43.4% of CPC line passed through posterior third of IP, 33.0% through middle and 23.6% passed through anterior third of IP (Table 3). One way ANOVA p-value was 0.009 (<0.05), suggesting there is a significant difference in mean distance of central incisor to incisive papilla amongst the 3 types of CPC line (middle, posterior and anterior) (Table 3). Therefore, post hoc Tukey HSD test was done to identify which of the pairs of groups are significantly different from each other. Significant differences were observed between middle and posterior (Table 4). Thus, the mean distance of CI to IP was significantly greater when CPC passed from the middle than from posterior of the incisive papilla.

Table 1. Relationship of various arch forms with distance of CI to IP

Variable	Types	N (%)	Mean distance of CI to IP± Standard Deviation	95% Confidence Interval		F (df)	Significance
				Lower bound	Upper bound		
Shape of arch	Parabolic	139(76.4%)	11.089 ± 1.835	10.781	11.397	0.158 (2)	0.854
	Ellipsoidal	15(8.2%)	10.885 ± 2.073	9.738	12.033		
	Hyperbolic	28(15.4%)	11.226 ± 2.138	10.397	12.056		
Total		182(100%)	11.093 ± 1.894	10.816	11.370		

One Way ANOVA ; p <0.05

Table 2. Relationship of various shapes of IP with distance of CI to IP

Variable	Types	N (%)	Mean distance of CI to IP± Standard Deviation	95% Confidence Interval		F (df)	Significance
				Lower bound	Upper bound		
Shape of arch	Elliptical	60(33.0%)	11.327 ±1.902	10.836	11.819	2.434 (2)	0.091
	Thin	36(19.8%)	10.488 ±1.834	9.867	11.108		
	Triangular	86 (47.3%)	11.184 ±1.883	10.780	11.588		
Total		182 (100%)	11.093 ±1.894	10.816	11.370		

One Way ANOVA ; p <0.05

Table 3. Relationship of various canine papilla canine relation with distance of CI to IP

Variable	Types	N (%)	Mean distance of CI to IP± Standard Deviation	95% Confidence Interval		F (df)	Significance
				Lower bound	Upper bound		
Canine papilla canine relation	Middle	60(33)	11.521±1.801	11.056	11.987	4.870 (2)	0.009*
	Posterior	79(43.4%)	10.606±1.685	10.229	10.984		
	Anterior	43(23.6%)	11.391±1.685	10.714	12.068		
Total		182 (100%)	11.093±1.894	10.816	11.370		

One Way ANOVA ; p <0.05

Table 4. Post Hoc analysis between Pairs of CPC groups

CPC groups		Mean Difference	Std. Error	Significance
Middle	Posterior	0.915	0.318	0.012*
	Anterior	0.131	0.371	0.934
Posterior	Anterior	-0.784	0.352	0.069

Tukey Test ; p <0.05

DISCUSSION

This study aimed to assess the relationship between CI and IP with the various types of arch forms, shapes of IP and relationship of it with CPC in Nepalese adults. In this study, there was no significant difference in the distance of CI to IP with various shapes of IP or types of arch forms. However, in this study, the mean distance of central incisor to incisive papilla was significantly greater when CPC line passed from the middle than from posterior part of the incisive papilla.

Replacing the missing structures and restoring the natural appearance is the main aim of prosthodontic treatment. Tooth position is the most important tooth factor in producing a natural appearing artificial restoration.¹² Various anatomical landmarks have been proposed as a guide to position the denture teeth and are called biometric guide.¹³ The most obvious landmark that seems to survive relatively intact from the dentate state is the incisive papilla, which does not change its position up to 7 years after teeth extraction.^{7,14} It has been observed that the longer the teeth had been absent, the more anteriorly the papilla was situated because of resorption pattern of the maxilla.¹⁵ Hence the posterior border of the incisive papilla was used as a point of reference as it seemed to be relatively stable even after bone resorption.¹⁶ This has been noted in various studies where the posterior point of incisive papilla was used.^{5,6} However, measurement had also been done from the middle and anterior part of incisive papilla.^{3,9}

The assessment of arch form has been done by their geometrical description as described in previous literature.¹¹ Similar to the result from the study by Filho et al., here in this study we had observed that parabolic form of arch was the commonest, which seems converse to the earlier result by Kook and Nakatsuka where they stated that square and round square respectively to be most common.^{11,17,18}

This study found that there was no significant difference between the distances of incisive papilla to central incisor among different arch forms. This could be due to the lesser number of subjects in ellipsoidal arch form. These results are similar to another study carried out in Nepalese population by Shrestha et al. in 2016.¹⁹ However, the findings are contrary to studies carried out by Zia et al. and Avhad et al. done in other Asian population.^{1,2}

In our study, the mean distance of central incisor to incisive papilla was 11.093 mm with a standard deviation of 1.894 mm. 95% Confidence interval lies between 10.816 mm and 11.370 mm which suggests, in 95% of the Nepalese population the distance between maxillary CI to IP lies in this range. This is similar to studies done by Ortman et al., Shrestha et al. and Paul et al.^{6,19,20} However, this distance was observed but from posterior third of incisive papilla to central incisor instead of from middle third.

Regarding the shape of the incisive papilla, triangular shaped papilla was found to be the commonest similar to the study by Filho et al.¹¹ No significant difference was found in relation to the shape of the IP and distance of CI to IP. Another study suggested that cylindrical shape of IP had maximum distance and round shape had the minimum distance.⁸ These findings differ due to the difference in the classification used to assess shape of incisive papilla.

In this study, CPC line passed through the posterior third of incisive papilla in a maximum number of subjects. This was similar to the studies done by Po-Sung et al. and Mavroskoufis et al.^{7,21} In another study done in Nepalese population by Shrestha et al. the percentage of individuals with anterior, middle and posterior CPC slightly differed from our study.¹⁹ This could be due to a different number of individuals in both the studies with relation to the types of CPC. Also, there was barely any previous literature comparing the distance of CI to IP with the CPC line in Nepalese population.

This study found that IP can be used as clinical practice guideline for the setting of maxillary anterior teeth in patients with Angle's Class I molar relation. Furthermore, studies need to be carried out for other skeletal and dental malocclusions on a larger sample size and equal gender distribution which are the limitations of this study.²⁰

Although dentists can select appropriate artificial teeth based on their knowledge, the anterior teeth selection also depends on the patients' demands. Thus anterior try-in should precede the full arrangement try in.²² The positioning of the maxillary central incisor in an edentulous individual can be aided by the results obtained in this study carried out in dentate individuals which assess the relationship of the central incisor with the shape of IP, types of arch forms and CPC line.

CONCLUSION

In this study, parabolic arch form and triangular shaped incisive papilla were found to be most common. The mean distance of central incisor to incisive papilla was significantly greater when CPC line passed from the middle than from posterior part of the incisive papilla. The mean distance of central incisor to incisive papilla in Nepalese population was 11.093 ± 1.894 mm. This can be used as a guide for placement of anterior teeth and for fabrication of occlusion rim which will help to reduce the chairside time.

REFERENCES

- Zia M, Azad AA, Ahmed S. Comparison of distance between maxillary central incisor and incisive papilla in dentate individuals with different arch forms. *J Ayub Med Coll Abbottabad*. 2009 Dec 1;21(4):125-8.
- Avhad R, Tembhumne J, Sar R. Evaluation of the relation of maxillary canine and edge of central incisor to incisive papilla in Indian population with respect to arch form. *The Journal of Indian Prosthodontic Society*. 2014 Sep 1;14(3):228-32.
- Khalaf HA. Evaluation of the incisive papilla as a guide to the maxillary central incisors and canine teeth position in Iraqi and Yemenian samples. *J Fac Med Baghdad*. 2009;51(2):146-50.
- Shah M, Verma AK, Chaturvedi S. A comparative study to evaluate the vertical position of maxillary central incisor and canine in relation to incisive papilla line. *Journal of forensic dental sciences*. 2014 May;6(2):92-6.
- Erlich J, Gazit E. Relationship of the maxillary central incisor and canine to the incisive papilla. *J Oral Rehabil*. 1975;2:309-12.
- Ortman HR, Tsao DH. Relationship of the incisive papilla to the maxillary central incisors. *The Journal of prosthetic dentistry*. 1979 Nov 1;42(5):492-6.
- Fu PS, Hung CC, Hong JM, Wang JC, Tsai CF, Wu YM. Three-dimensional relationship of the maxillary anterior teeth to the incisive papilla in young adults. *The Kaohsiung journal of medical sciences*. 2007 Oct 1;23(10):519-25.
- Agarwal KS, Singhal R, Pagia S. Evaluation of papillo-incisal distance with different shapes of incisive papilla. *International Journal of Science and Research*. 2016;5(3):1341-2.
- Watt DM, Likeman PR. Morphological changes in the denture bearing area following the extraction of maxillary teeth. *British dental journal*. 1974 Mar 19;136(6):225-35.
- Testut L. *Tratado de Anatomia Humana*. Barcelona: Salvat Editores; 1944.
- Filho IE, Sales-Peres SH, Sales-Peres A, Carvalho SP. Palatal rugae patterns as bioindicator of identification in forensic dentistry. *RFO*. 2009;14(3):227-33.
- Krajicek DD. Achieving realism with complete dentures. *The Journal of Prosthetic Dentistry*. 1963 Mar 1;13(2):229-35.
- Karthigeyan S, Ali SA, Koruthu AV, Mohan K. Incisive papilla as a biometric guide in the arrangement of teeth. *Pakistan Oral & Dental Journal*. 2012 Aug 1;32(2).
- Harper RN. The incisive papilla. *J Dent Res*. 1948;27:661-8.
- Klemetti E, Lassila L, Lassila V. Biometric design of complete dentures related to residual ridge resorption. *The Journal of prosthetic dentistry*. 1996 Mar 31;75(3):281-4.
- Grave AM, Becker PJ. Evaluation of the incisive papilla as a guide to anterior tooth position. *The Journal of prosthetic dentistry*. 1987 Jun 1;57(6):712-4.
- Kook YA, Nojima K, Moon HB, McLaughlin RP, Sinclair PM. Comparison of arch forms between Korean and North American white population. *Am J Orthod Dentofacial Orthop*. 2004;126:680-8.
- Nakatsuka M, Iwai Y, Jue Ss, Oh Sh, Guo L, Tominaga Y, Kumabe S. A morphological study on the classification of maxillary dental arches. *Okajimas folia anatomica Japonica*. 2004;81(1):5-14.
- Shrestha S, Joshi SP, Yadav SK. Relationship of Incisive Papilla to Maxillary Incisors and Canines. *The journal of contemporary dental practice*. 2016 Apr;17(4):306-12.
- Paul T, Kurian BP, Raj P, George R. Evaluation of incisive papilla as a guide for maxillary anterior teeth positioning: a study among dental students. *Int. J Dent Health Sci*. 2016;3(1):53-62.
- Mavroskoufis F, Ritchie GM. Nasal width and incisive papilla as guides for the selection and arrangement of maxillary anterior teeth. *The Journal of prosthetic dentistry*. 1981 Jun 1;45(6):592-7.
- Bing C W, Kwan LL, Isa M Z. Incisive papilla and hamular notches as guides to maxillary anterior teeth size in edentulous patients. *Dentik Dental Journal* 2009;14(2):109-14.