

Mandibular reconstruction

Nath S¹, Joshi KD², Shakya S³, Shrestha S⁴, Koirala U⁵

^{1,2}Professor Plastic and Reconstructive Surgery, ³Faciomaxillary Surgeon, Bir Hospital, Kathmandu, ⁴Assistant Professor, ⁵Lecturer, Department of Surgery, KMCTH, Sinamangal, Kathmandu, Nepal,

Abstract

One of the most difficult problem in reconstructive surgery is the replacement of lost bone from trauma, tumour, infection or congenital anomaly. This is a case report of a 20 year old male who had suffered a blast injury of his lower jaw. From his first admission in the Plastic unit of Bir Hospital on Feb 19, 2003, he had undergone multiple operations until Nov 2003. This is a description of a follow up surgery done in Kathmandu Medical College (KMC), Sinamangal. Difficulties encountered and options available have also been discussed.

Key word: Mandibular reconstruction, Pedicle osteomyocutaneous flap

Case Report

Management in Bir Hospital (NAMS)

On 19th Feb 2003, a twenty year old male was admitted in the Plastic unit of Bir hospital following a blast injury of unknown cause. He had destruction of the lower jaw, both lips, a part of the nasal septum and nose (Fig. 1). He had emergency tracheostomy under sedation and local anaesthesia. Through the tracheostomy tube general anaesthesia (GA) was given and debridement was performed. With the help of Ryles tube, feeding was done and nutrition was maintained (Fig 2). After ten days the second procedure was performed where a minor debridement and placement of stainless steel plate was done to replace the missing lower jaw. The lip was also reconstructed.

After three weeks, in third session the tethered tongue was released from floor of the mouth creating a large defect which further added to his existing soft tissue defect. This defect was covered by Delto-Pectoral flap as well as split skin graft from the chest wall. Unfortunately, the distal part of flap was necrosed after one week which healed by fibrous tissue.

During the six month period (May to November, 2003) he had undergone another four sessions of operation using either GA or local. These were for further remodelling of lips and realignment of the local tissue. At the time of discharge he could swallow soft food.

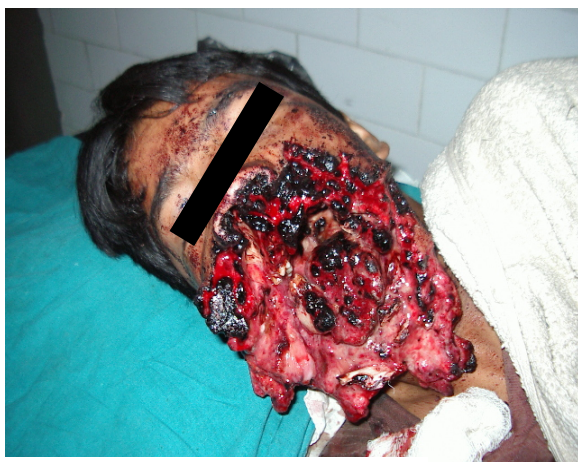

Fig 1: First admission at Bir Hospital

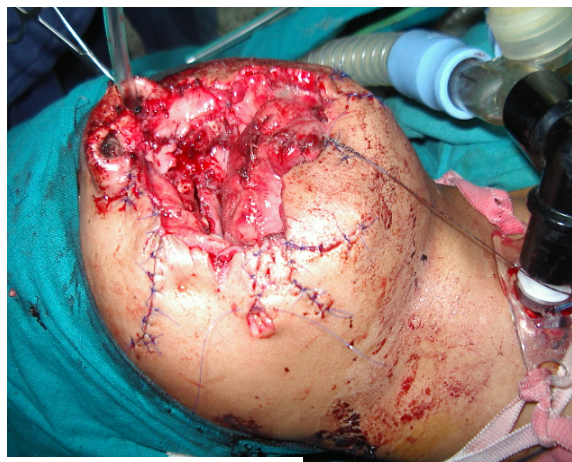

Fig. 2: After first surgery

Correspondence

Prof. Shambhu Nath
Dept. of Surgery
Kathmandu Medical College, Sinamangal, Kathmandu
Email: sambupare@wlink.com.np

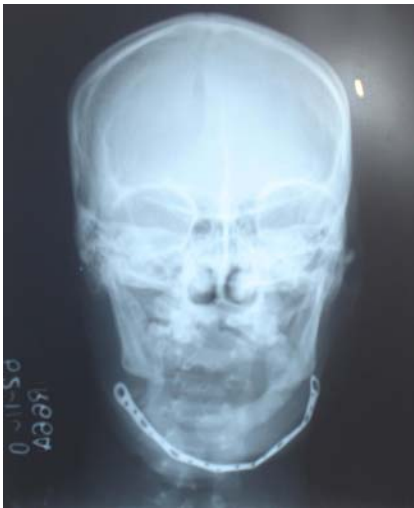

Fig 3: Stainless steel plate from previous surgery removed since it was loose

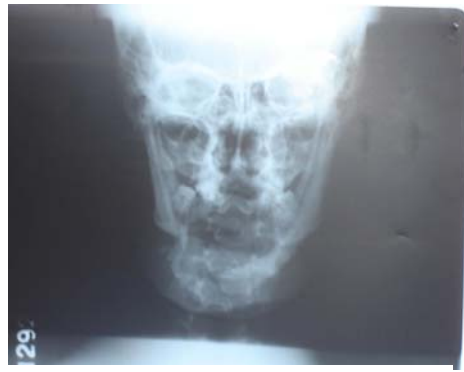

Fig 4: Heterotrophic calcification

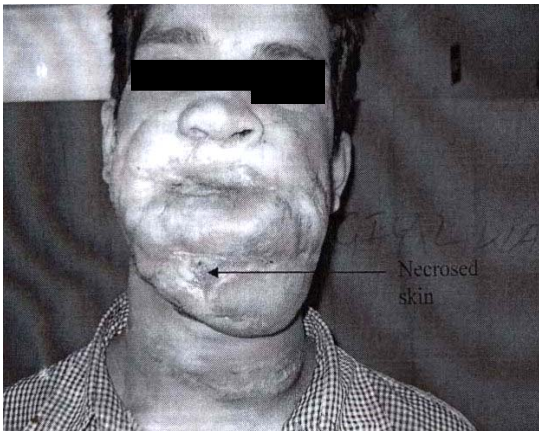


Fig 5: After the osteomyocutaneous flap (Small area of necrosed skin)

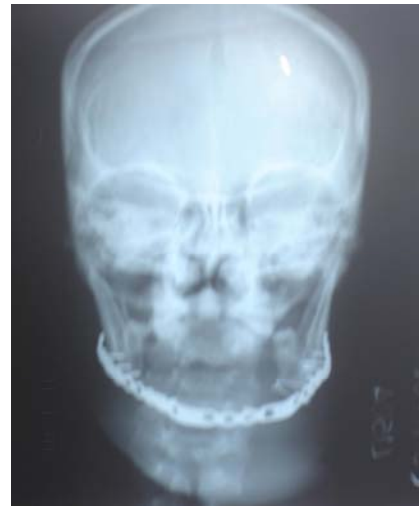

Fig 6: Second Plate applied below rib graft

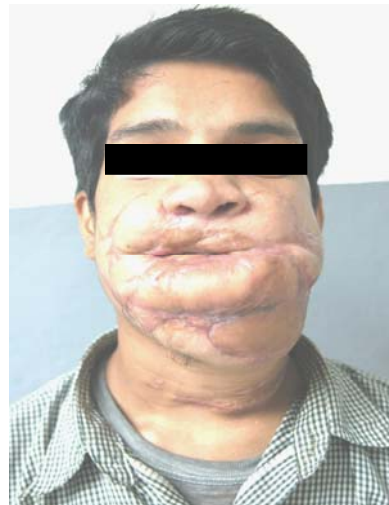

Fig 7: Before discharge

Management at KMCTH (Kathmandu Medical College Teaching Hospital)

After almost 2 years, on 6th November 2006, the same patient came to the KMC Surgical OPD with facial deformity of the lower third of the face including the alae of the nose, upper and lower lip and commissures. On examination, he had protruding stainless steel mandibular plate which was very loose and having difficulty in eating. In consultation with Faciomaxillary surgeon it was removed under local anaesthesia. There was a lot of heterotrophic calcification (Fig. 3 and 4). Later we used an osteomyocutaneous flap for reconstructing the defect of the lower jaw.

Operation

Mandibular reconstruction is a challenging surgery. Any surgery of this kind involves the input of the plastic surgeon, faciomaxillary surgeon and the anaesthetist.

1. Tracheostomy through previous scar.
2. Debridement and removal of heterotrophic bone through incision in the lower jaw creating a defect of more than 8 cm.
3. Using Right 5th rib and Pectoralis major muscle (osteomyocutaneous flap) with a long muscle pedicle was raised. Dissection was kept very close to posterior periosteum of the rib to avoid entry into the chest. The periosteum of the rib is preserved to ensure maximum blood supply. The lateral end of the rib was cut and then it was disarticulated from the sternum at the costo-chondral junction. It was lifted along with its attached muscle. The intercostal artery was ligated as it leaves the internal mammary artery. Rib can usually be elevated without damaging the pleura. Bleeders of perichondrium and periosteum were cauterised after elevation of the flap. After identifying and preserving the Thoraco-acromial artery a required portion of muscle was separated as a long pedicle.
4. This osteomyocutaneous flap with its neuro-vascular supply was tunnelled beneath the skin in the supraclavicular area and into the neck and mouth. While transferring the bone and muscle a figure of 8 thick silk suture was used to loop the tissue to avoid searing of skin during its transfer through the skin tunnel. Fixation of the ribs to the ends of the mandible was done with wire, plate and screw. For added strength and stability a steel plate was also used to fix the rib (Fig 6).
5. Both the lips and nose tip were reconstructed for better cosmesis. Another tiny piece of rib was also used to give nose tip projection.
6. Total time for surgery was 7 hours.

Post operatively, there was some skin necrosis on the right side which was desloughed and healed in three weeks without any bad effect (Fig 5). After 15 days the Ryles tube was removed and he was started on soft food. Tracheostomy was removed after one week. The patient still needs corrective surgery after one year with further softening of scar. Presently he can speak, and eat soft food (Fig 7).

Discussion

Mandibular reconstruction continues to be one of the most difficult challenges in reconstructive surgery. It plays a major role in airway protection, support for the tongue, muscles of the floor of the mouth, lower jaw dentition, articulation, deglutition and respiration. The goals of mandibular reconstruction are:

- i) Establishment of mandibular continuity with acceptable cosmetic result.
- ii) Establishment of osseous alveolar base and
- iii) Correction of soft tissue defect.

Therefore, a surgeon has to balance his procedure to achieve best possible cosmetic appearance with reliable function. The functions of chewing, swallowing, speech articulation and oral competence must be addressed. In order to achieve it, one must restore bony continuity, facial contour, tongue mobility and speech. Dental rehabilitation must also be kept in mind. .

For restoration of mandibular defects the use of autogenous bone is the preferred option. The other options are solely Alloplastic materials or Alloplast and bone graft together as we have used in this patient. Alloplastic materials are in the form of Stainless Steel wires, plates (alloy of iron, chromium and nickel) or Vitallium (alloy of chromium, cobalt and molybdenum). It has more tensile strength than of stainless steel and titanium, Titanium which is a pure material and is rigid, less prone to corrosion than of Stainless Steel or Vitallium.

Organic materials like calcium aluminate, calcium apatite, calcium sulphate (plaster of Paris) are also available. Hydroxyapatite is a major ceramic material. It is an inorganic constituent of bone. It is produced by coral and is available in block, granite and cement form. It is osseoconductive and allows creeping substitution. It has no osseoinductive or osteogenic properties. When mixed with water it rapidly hardens. It is mostly used for calvaria and facial skeleton.

Synthetic materials like Methylmethacrylate, Cyanoacrylate, Proplast and Teflon are available. Plates made of stainless steel (AO), Vitallium and Titanium (titorp plates) are also in the market. Advantages being – no donor site morbidity, ease of use, choice of contouring and even condyles could be easily reconstructed. The complications are plate-extrusion, plate-fracture and loosening of screws as we have seen in this patient.

The pectoralis myocutaneous flap is still the workhorse in head and neck reconstruction. There are very few complications and no disability from the loss of this flap¹. Locally, the defect can be primarily closed as in this patient. The pectoralis major osteomusculocutaneous flap is very reliable for reconstructing mandibular defects. Reconstruction of the soft palate, floor of the mouth and lateral pharyngeal wall can also be done with this flap^{2,3}. Delto-Pectoral is another option for simple cover for these areas.

Microvascular free flaps are now commonly used in centres with facilities and expertise. Pioneering work was done by Soutar et al², Serafen et al⁴, Daniel⁵. Their work made it possible to use various kinds of musculocutaneous flaps, cutaneous flaps like the radial forearm flap, and osteomyocutaneous free flaps from the iliac crest and radius- cutaneous from forearm.

When bone loss is minimal, cancellous bone graft, usually from the iliac crest helps to bridge the gap with good result. However, when the defect is 6 cm or more this bone graft may not unite. An excellent vascular bed to nourish the new osteoblasts is a must and thus vascularized living bone transfer was discovered. Taylor et al⁶ transferred vascularized contralateral fibula to fill a large tibial defect. Serafin et al⁷ reported the use of vascularized rib for mandibular non-union. With the proficiency in the use of microvascular tissue gaining wide acceptance and the use of free vascularized bone transfer has come to stay. This is now the time honoured method where the facilities are available. Sites of bone graft have been ribs, fibula, iliac crest, scapula and distal radius. The fibula for cortical bone and iliac crest for cancellous are still popular.

Conclusion

Within the last three decades major advances have been made in the field of microvascular and reconstructive surgery. In mandibular reconstruction the challenge is to restore airway support, oral incompetence, articulation, mastication, deglutition and acceptable cosmesis; thus, allowing the patient to resume his role in the society. Osteomyocutaneous flaps allow transfer of tissue with rich blood supply with osteogenic potential. It also tolerates radiation in cases of malignancy. In the end, the training and availability of a team of experts makes all the difference in the eventual result of this reconstruction.

Acknowledgement

Our thanks are due to the anaesthesia team of the KMCTH for their cooperation during the execution of this surgical procedure

References

1. Arriyan S: The pectoralis major myocutaneous flap: A versatile flap for reconstruction in the head and neck. *Plast Reconstr Surg*: 63:73 1979
2. Soutar D, Scheker LR, Tanner NSB, MaGregor IA: the radial forearm flap: A versatile method for intraoral reconstruction. *Br J Plas Surg*. 36:1, 1983.
3. Cuono CB, Ariyan S: Immediate reconstruction of a composite mandibular defect with regional osteomusculocutaneous flap. *Plast Reconstr Surg*: 65:477 1980
4. Serafin D, Villarreal – Rios A, Feorgiade N: A rib containing free flap to reconstruct mandibular defects. *Br J Plas Surg* 30: 263, 1977.
5. Daniel RK: Mandibular reconstruction with free tissue transfer. *Ann Plas Surg* 1: 346, 1978
6. Taylor G, Miller GDH, Ham FJ: The free vascularized bone graft. *Plast. Reconstr Surg* 55: 533 1975.
7. Serafin D, Villarreal – Rios A, Feorgiade N: A rib containing free flap to reconstruct mandibular defects. *Br J Plas Surg* 30: 263, 1977.