

Multiple tendons of abductor pollicis longus muscle: A cadaveric study with clinical implications

Paul S¹, Das S²

¹Director Professor of Anatomy, ²Associate Professor of Anatomy, Maulana Azad Medical College, New Delhi-110002, India

Abstract

Abductor pollicis longus (APL) muscle is known to exhibit numerous variations. Variations in the number of tendons of APL muscle may be asymptomatic and are often incidental findings. The present case report, detected in a 42 year male cadaver, describes the APL muscle having three tendons. The presence of accessory tendons may be important in De Quervain's stenosing tendovaginitis. Anatomical knowledge of such variations may be clinically important for surgeons performing reconstructive hand surgeries in the dorsolateral region of the hand. In a wider perspective, variations in the number of tendons of APL may also be important for anthropological correlation and academic studies.

Key Words: Abductor pollicis longus, muscle, variations, tendon, cadaver.

APL is an important muscle responsible for abduction of the thumb. The APL takes origin from the posterior surface of the radius, ulna and the interosseous membrane¹. It is inserted to the first metacarpal and may have an additional attachment to the trapezium bone¹.

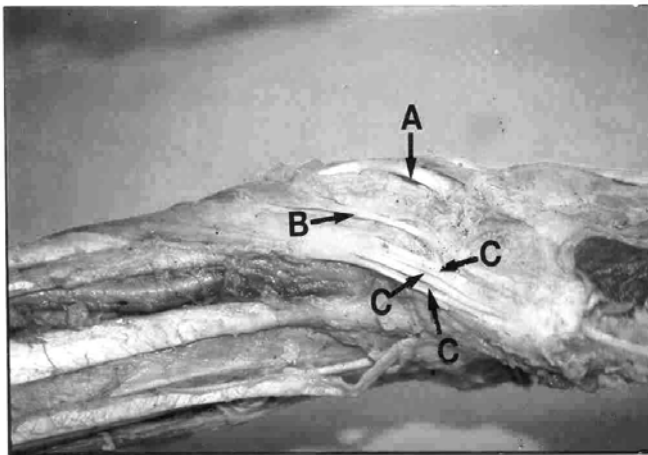
The functional role of APL in De Quervain's stenosing tendovaginitis have been well documented². Often the surgeon is exposed to the vagaries of the hand region only during operation and a prior anatomical knowledge of such variations may be

helpful in checking any inadvertent injury to the accessory tendons. Additional tendons may be used for reconstructive surgeries.

Case report

During routine cadaveric dissection in the department of anatomy, we detected anomalous APL muscle on the left side of a 42 year male cadaver. The APL muscle was studied in detail with regard to its origin, insertion, attachments and innervation and was photographed (Fig.1).

Fig1: Photograph of dissected specimen



A: Extensor Pollicis Longus muscle

B: Extensor Pollicis Brevis muscle

C: Multiple tendons of Abductor Pollicis Longus muscle shown with arrows .

Correspondence

Prof. Shipra Paul,
D-II/A-75, Nanak Pura,
MotiBagh-South
New Delhi-110021, India
E-mail: drshipra14@yahoo.com

Observations

The origin of the APL was as usual from the posterior surface of radius, ulna and interosseous membrane. The APL thereafter split into three tendinous slips at the level of wrist which were close to each other and joined near its insertion as a flattened aponeurosis before it finally inserted into first metacarpal. (marked as 'C' in Fig.1). The innervation was by posterior interosseous nerve.

Discussion

It is exceptional to find a single tendon or insertion of APL muscle³. Considering the fact that multiple tendon variation is more frequent, the clinical importance of such variations cannot be neglected. The variations of the tendons have been reported by many research workers. A maximum of seven tendons of APL have been reported by researchers². The multiple tendons of APL may alter the force component thereby altering the mechanics of the thumb.

During any surgery, the existence of multiple tendons of APL is bound to confuse any surgeon. The variations in the number of APL tendons and the corresponding osseo-fibrous canals have been reported to be involved in the aetiology and subsequent decompression of De Quervain's Syndrome⁴. Many a times, lack of prior anatomical knowledge may lead to inadequate surgical decompression of De Quervain's Syndrome⁴.

The APL is known to have split insertion in chimpanzees, gorillas and gibbons⁵. The existence of such anomalies in the human beings may be a result of atavism. Hence the presence of such anomalies also underlines the anthropological importance.

The presence of multiple tendons may be important for surgeons performing grafting operations in the dorsolateral compartment of the hand. The present case report is a humble submission to highlight the existence of multiple tendons of APL and its clinical importance in day to day clinical practice.

References

1. Standring Susan. Gray's Anatomy - The Anatomical Basis of Clinical Practice. 39th. ed. Elsevier Churchill Livingstone, New York, 2005, pp. 881.
2. Melling M, Wilde J, Schnallinger M, Schweighari W, Panholzer M. Supernumerary tendons of the abductor pollicis. Acta Anatomica 1996 ; 155 : 291-294.
3. Coleman S.S, D.K. McAffe, B. J. Anson. The insertion of the abductor pollicis muscle. An anatomical study of 175 specimens. Q. Bull. Northwest. Univ. Med School 1953; 27: 117-122,.
4. Giles, K.W. Anatomical variations affecting the surgery of De Quervain's disease. J. Bone J. Surg 1960 ; 42 : 352-355,.
5. Lacey T.L.A, Goldstein C.E & Tobin. Anatomical and clinical study of the variations in the insertions of the abductor pollicis longus tendon associated with stenosing tendovaginitis. J.Bone Joint Surg. [Am] 1951; 33: 347-350.