

Topiramate induced bilateral angle-closure glaucoma

Singh SK, Thapa SS, Badhu BP

¹Medical Director, Mechi Eye Care Centre, Birtamod, Jhapa, Nepal, ²Glaucoma Consultant, Tilganga Eye Centre, Kathmandu, Nepal, Additional Professor, Eye department, B.P.K. Institute of Health Sciences, Dharan

Abstract

Topiramate is a sulfamate-substituted monosaccharide and is used as an antiepileptic medication¹. It can also be used as a prophylactic agent for headache from migraine². The main purpose of this article is to create awareness among medical colleagues regarding severe ophthalmic side effect of topiramate. This is the first reported case of topiramate induced bilateral angle-closure glaucoma in Nepal. This case was managed successfully by discontinuing topiramate and by starting anti-glaucoma medication along with atropine eye drops which were tapered and eventually discontinued.

A 33 year old woman presented to the Emergency Department of Mechi Eye Care Centre with severe headache associated with vomiting and loss of vision for last 3 hours. She had a long history of headache every once or twice in a fortnight that was relieved after taking Nimesulide tablets. About one and a half years ago, she consulted a physician, who commenced her on tablets Migon (Flunarizine) with provisional diagnosis of migraine. She discontinued this medication about three months ago as it resulted in excessive weight gain. After the discontinuation of Migon, the headaches reoccurred for which she consulted a neuro-physician who prescribed her Topiramate. She was advised to take tablet Topiramate 25 mg once daily for one week and increased it to 50 mg once daily for one year. Her condition improved during initial small dose. However, when the dose was subsequently increased to 50 mg in the second week, she developed a severe headache associated with vomiting and diminished vision the next day. She took a tablet of diazepam (5 mg) which did not relieve her symptoms. She immediately consulted the emergency department of a general hospital with these complaints. She was admitted to the ward and commenced on intravenous analgesics and tablet Migon. Her vision worsened progressively for which she was referred to the emergency department of the Mechi Eye Care Centre.

Clinical findings and treatment

Her visual acuity recorded "no perception of light" in both eyes. Other ocular findings included mild corneal epithelial oedema, very shallow anterior chamber with peripheral irido-corneal touch (see the photographs) and a pupil of six-mm size, round and not reacting to light, in both eyes. Lens and vitreous were clear. The optic nerve head was normal with a

cup to disc ratio of 0.7:1 and a healthy neuroretinal rim. The intra-ocular pressure was 48 mmHg in both eyes. Gonioscopy revealed a closed angle with absence of angle structures which did not open on indentation. The patient was started on IV Mannitol 20%, 5 ml/kg, tablet acetazolamide 250 mg four times/day, Timolol 0.5% twice a day and pilocarpine 2% eye drops four times a day. By next morning, her vision improved to 3/60 and the intra-ocular pressure was 28 mmHg. Other ocular findings remained the same as the previous night. After one hour, the intra-ocular pressure increased again to 40 mm of Hg.

In order to control her deteriorating condition, the patient was referred to a glaucoma specialist. She was suspected to have developed bilateral angle-closure glaucoma secondary to the use of a systemic drug, Topiramate. Topiramate tablet and Pilocarpine eye drops were stopped while timolol eye drops and acetazolamide tablets were continued in the same dosages. Pilocarpine was discontinued to prevent further shallowing of the anterior chamber and instead atropine 1% was prescribed three times a day to relax ciliary muscle and displace lens-iris diaphragm posteriorly to relieve the angle closure.

Correspondence

Dr Sanjay Kumar Singh
Mechi Eye Care Centre, Birtamod, Jhapa, Nepal
Phone no: 023-541093, 023-541492, 023-540153
Email address: sanjaysinghnepal@yahoo.com

These resulted in gradual decrease in the intra-ocular pressure and progressive improvement in the visual acuity. The intraocular pressure measured 12 mmHg after three days of treatment and the visual acuity recorded 6/9 unaided in one week in both eyes. The anterior chamber returned to normal depth and the ciliary band could be viewed 360 degrees on gonioscopy. Visual field examination (automated

perimetry by Humphrey visual field analyzer 30-2) done after two weeks was within normal limits. Antiglaucoma medications were gradually tapered and finally discontinued in three weeks. Atropine eye drops were stopped after 2 weeks. The patient was thereafter advised not to take tablet Topiramate any more in the future.

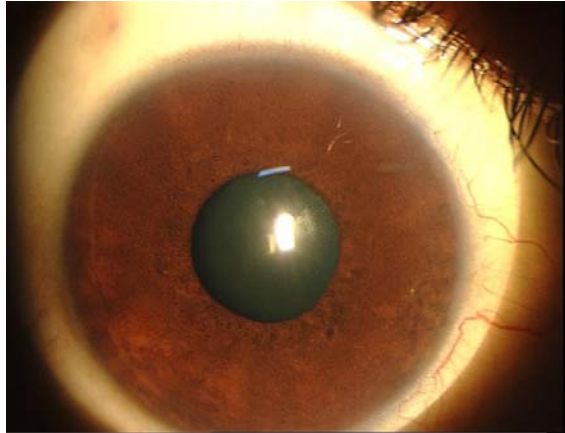


Fig 1: Relatively quiet eye at the time of presentation

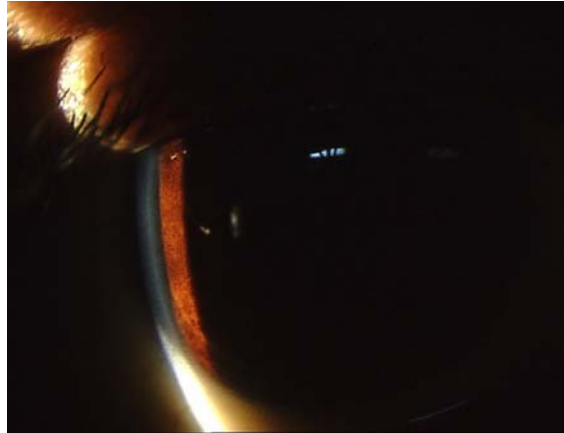

Fig 2: Very shallow anterior chamber at the time of presentation

Discussion

The patient was initially suspected as a case of Primary angle -closure glaucoma with an acute crisis in both eyes and was managed accordingly. However, some unusual features like bilateral and simultaneous presentation with relatively quiet eyes were noticed. Although simultaneous and bilateral acute presentation of Primary angle-closure glaucoma has been reported, it is rare. The congestion in both eyes was remarkably less when compared to a typical presentation of an acute variety of Primary angle closure. The congestion that the patient developed the following day may have resulted from frequent instillation of different eye drops. Topiramate is an antiepileptic drug with multiple mechanisms of actions¹. It is frequently used in conditions like migraine, bipolar post-traumatic stress disorders, post-herpetic neuropathy and other neurological conditions such as refractory partial seizures, seizures associated with the Lennox-Gestaut Syndrome and primary generalized tonic-clonic seizures^{1,3}.

Several reports have been published about Topiramate induced angle-closure glaucoma and

other ocular side effects which are reversible if the diagnosis is made early and the drug discontinued in time^{4,6}. The mechanism of action of Topiramate causing bilateral angle-closure glaucoma has been attributed to ciliochoroidal effusion which causes forward rotation of the lens-iris diaphragm leading to secondary angle-closure^{7,8}. Incongruous homonymous haemianopia has also been reported with the use of topiramate. Laser peripheral iridectomy has proven to be ineffective in the treatment for angle-closure caused by Topiramate^{5,9,10}.

Other reported complications are alteration in mood such as confusion, dizziness, drowsiness, generalized slowing of mental and physical activity, mental changes, agitation, nervousness and abdominal pain¹¹. Topiramate is a new drug with a potentiality for a common use for the treatment of migraine or cluster headache as seen in this patient. Many ophthalmologists may not be aware of the ocular side effects of this drug. This is the first reported case of topiramate induced angle-closure glaucoma in Nepal.

This case was managed successfully by discontinuing topiramate and by prescribing anti-glaucoma medication along with atropine eye drops which were tapered and eventually discontinued. Early identification of ocular side effects and immediate discontinuation of drug are associated with the reversal of symptoms.

References

1. Biton V MG, Ritter F, et al. A randomized, placebo controlled study of topiramate in primary generalized tonic clonic seizures. Topiramate YTC Study Group. *Neurology* 1999(52):1330-1337.
2. Storey JR CC, Hart DE, Potter DL. Topiramate in migraine prevention: a double-blind, placebo controlled study. *Headache* 2001(41:Supplement 1):S 3-11.
3. Sachdeo RC GT, Ritter F, et al. A double-blind, randomized trial of topiramate in Lenox - Gastaut syndrome. Topiramate YL study group. *Neurology* 1999(52):1882-1887.
4. Sen HA OH, Lee WB. Topiramate induced acute myopia and retinal striae. *Arch Ophthalmol* 2001(119):775-777.
5. Sankar PS PL, Grosskreutz CL. Uveal effusion and secondary angle closure glaucoma associated with topiramate use. *Arch Ophthalmol* 2001(119):1210-1211.
6. Rhee DJ GM, Parrish RK. Bilateral angle closure glaucoma and ciliary body swelling from topiramate. *Arch Ophthalmol* 2001(119):1721-23.
7. Craig JE OT, Louis DL, Wells JM. 2004.
8. Chen TC CC, Sorkin JA. Topiramate induced myopic shift and angle closure glaucoma. *BJO* 2003 May;87(5):648-9.
9. Banta JT HK, Budenz DL, Ceballos E, Greenfield DS. Presumed topiramate-induced bilateral acute angle-closure glaucoma. *AJO* 2001 July;132(1):112-4.
10. Fraunfelder FW FF, Keates EU. Topiramate-associated acute, bilateral, secondary angle-closure glaucoma. *Ophthalmology*. 2004 Jan;111:109-11.
11. Thompson PJ BS, Duncan JS, Sander JW. Effects of topiramate on cognitive function. *J Neurol Neurosurg Psychiatry* 2000(69):636-41.