

Crown augmentation using modified bilayered restoration for anchorage: A case report

Pai V¹, Kundabala M², Dixit P³, Gautam S⁴

¹Associate Professor, ²Professor and HoD, ³Lecturer, ⁴Specialist Resident, Dept. of Conservative Dentistry M.C.O.D.S, Manipal University, Attavar, Mangalore, India

Abstract

An ankylosed tooth can be suitable for obtaining orthodontic anchorage. However, if such a tooth lacks adequate clinical crown height, the anchorage will not be effective. In those situations surgical luxation or restorative crown augmentation is suggested. This case report is about the restorative treatment of an ankylosed, infraoccluded tooth to enhance the anchorage for forced orthodontic eruption of impacted maxillary canines. A crown augmentation in the form of a modified bilayered (sandwich) restoration using GIC, Composite resin and Silver amalgam on left maxillary first molar (26) was successful in sustaining the anchorage for forced eruption and alignment of impacted canines.

Ankylosis of permanent teeth is the direct fusion between root cementum and surrounding alveolar bone. Apart from trauma and replantation, pulp space therapies, orthodontic movement, certain endocrinal and congenital disorders have been implicated in its aetiology, which at times is obscured. Clinically it is characterized by submergence (infraocclusion), metallic sound on percussion and immobility. Radiographically the alveolar bone fades into the root without any intervening periodontal ligament space. First molars, cuspids and incisors are the most commonly ankylosing permanent teeth^{1,2,4}.

The long term prognosis of an ankylosed tooth is uncertain, as it is destined to root resorption and exfoliation and poses certain deterrent problems especially during the attainment of functional occlusion. Hence open method of extraction and prosthetic replacement is a practical choice. However, an ankylosed tooth due to its immobility can provide effective anchorage for orthodontic traction, but if the tooth is submerged, the anchorage may go futile for the want of clinical crown height. In such circumstances, surgical luxation or restorative therapy is indicated^{1,3,4}. This case report is about the restorative management of an ankylosed, infraoccluded left maxillary first molar (26), using a modified bilayered restoration to enhance the anchorage during orthodontic treatment.

Case Report

A male patient aged 15 years, undergoing orthodontic treatment was referred to the department of Conservative Dentistry and Endodontics, MCOADS, Mangalore, with a problem of frequent debonding of Transpalatal Arch (TPA) appliance. On examination,

this patient had fully erupted right maxillary first (16) and second molar (17) in relation to partially erupted left maxillary first (26) and second molar (27). The TPA appliance was banded on 16 and 26, for molar stabilization and anchorage, and had a modified cantilever spring for forced eruption of bilaterally impacted maxillary canines (Fig.1&2). On clinical examination and observation of models, IOPA and Occlusal radiograph, 26 was found to be partially ankylosed and infraoccluded lacking sufficient clinical crown height. Further, 26 was poorly root canal treated and had faulty amalgam restoration sealing the access opening and 27 was showing signs of delayed eruption (Fig.3&4).

Thus fully erupted 16 in relation to partially erupted 26 led to asymmetric fulcrum and debonding of the TPA appliance from 26 and loss of anchorage. To facilitate orthodontic anchorage clinical crown augmentation of 26 using GIC, Composite resin and Silver amalgam in the form of a modified bilayered restoration was planned out.

Correspondence

Dr. A. R Vivekananda Pai
Associate professor
Dept. Of Conservative Dentistry,
M.C.O.D.S, Manipal University
Attavar, Mangalore, India
E-mail: paivivekananda@yahoo.co.in

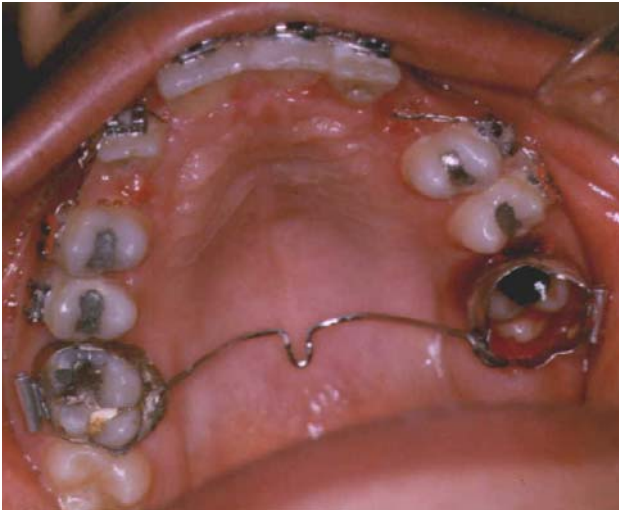

Fig 1: Debonded TPA appliance from 26 & bilaterally impacted maxillary canines.

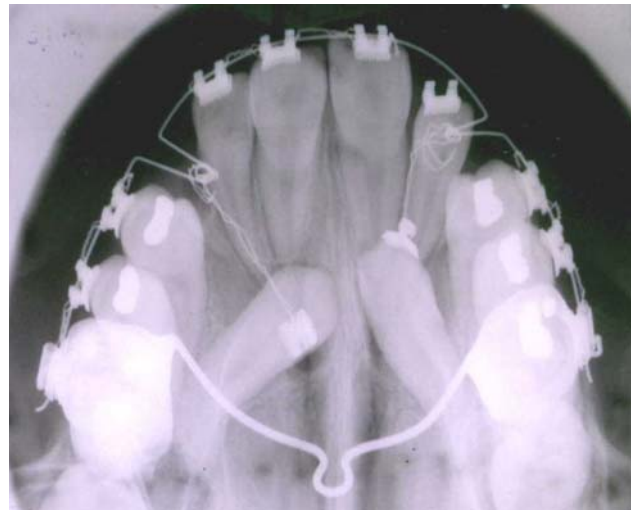


Fig 2: Occlusal Radiograph showing impacted canines.

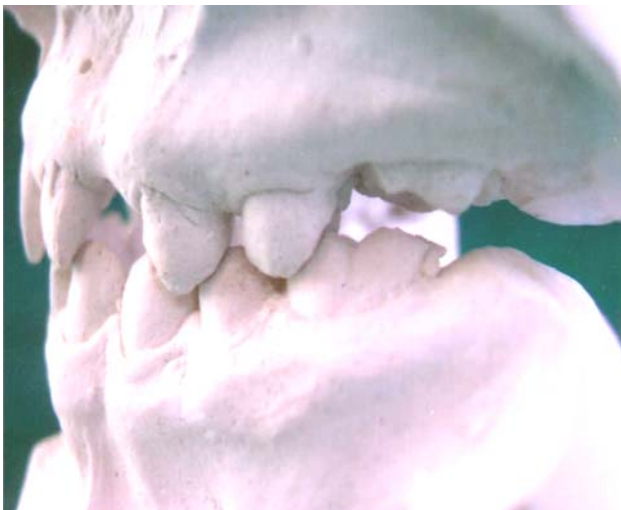

Fig 3: Model view of 26 and 27

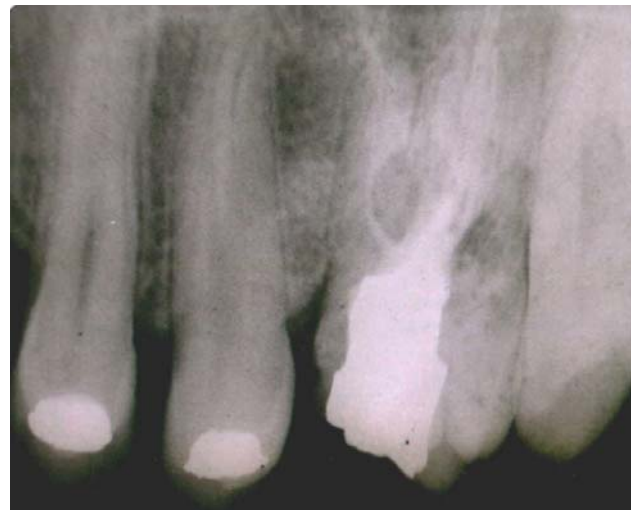

Fig 4: IOPA radiograph of 26

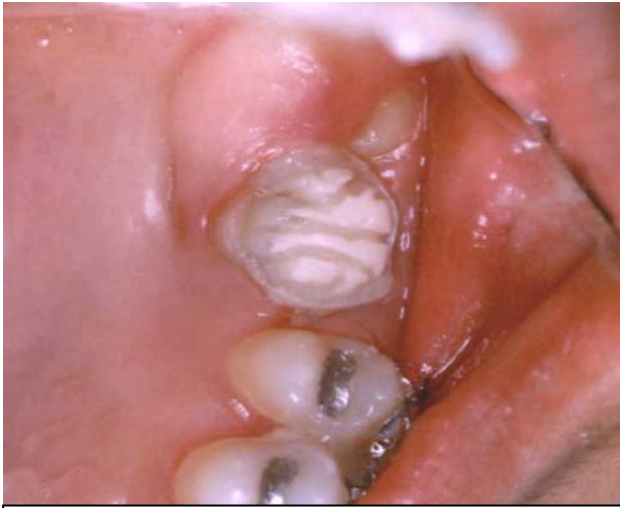

Fig 5: GIC build up on 26

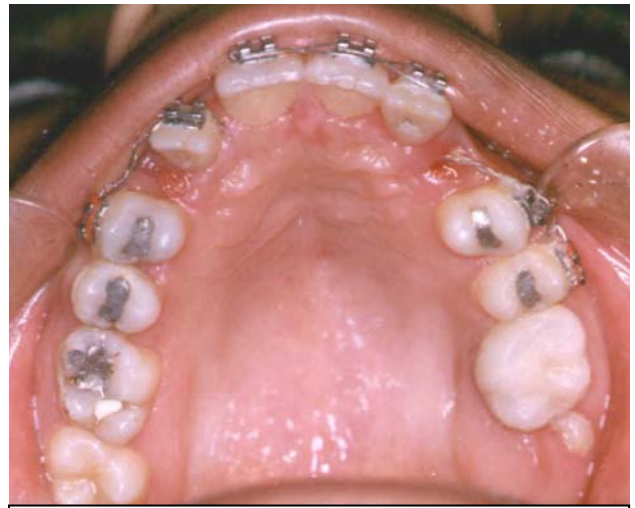

Fig 6: Crown augmentation using composite resin on 26.

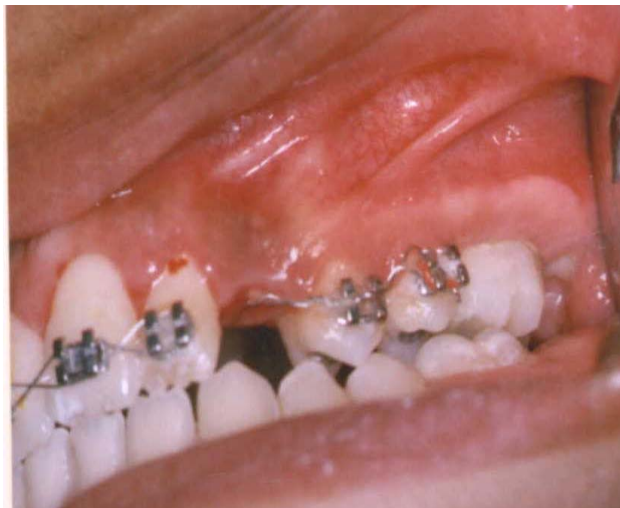

Fig 7: Buccal view of crown augmented 26.

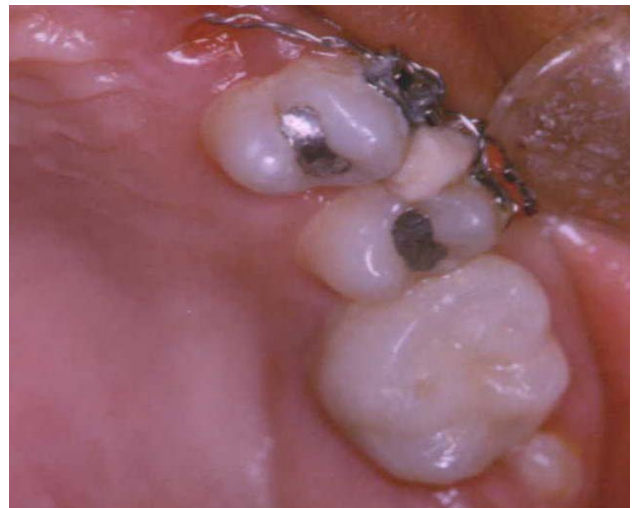

Fig 8: Amalgam cavities in composite crown augmentation.

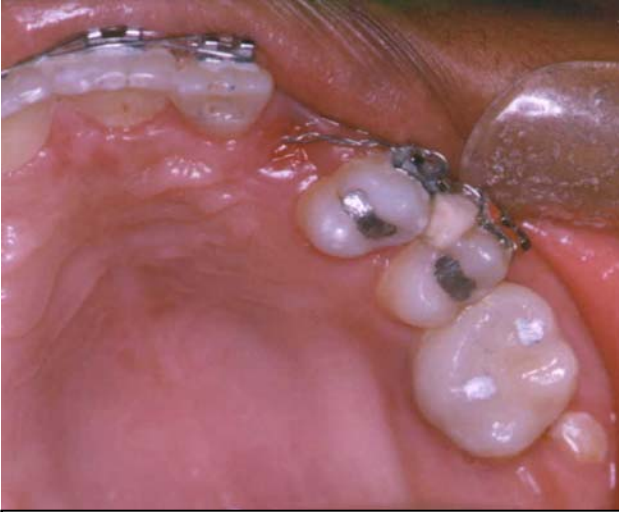

Fig 9: Amalgam occlusal stops.

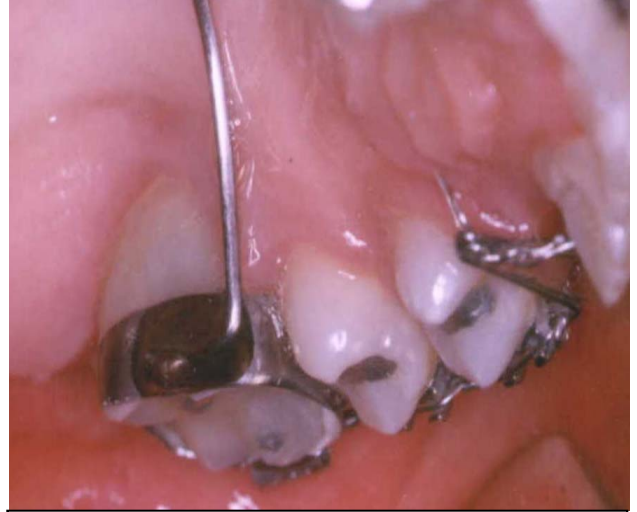

Fig 10: Recemented TPA on 26

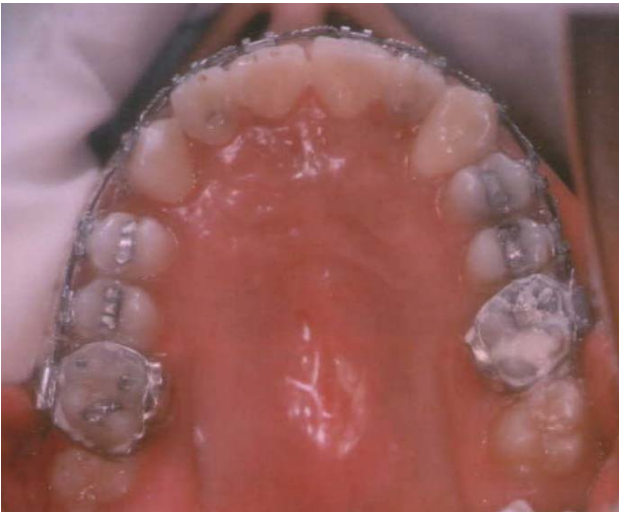

Fig 11: 2 year follow up -Canines erupted and aligned in the arch.

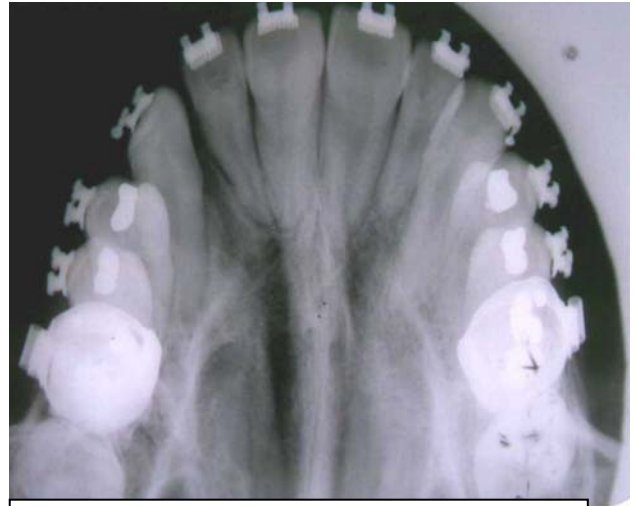


Fig 12: Occlusal radiograph showing aligned canines

Clinical Technique

A part of the faulty amalgam restoration along with all the residual caries was removed from 26 and replaced with GIC (Fuji II, GC Corp.), built in the form of a mound, slightly above the occlusal surface. Criss cross pattern grooves were cut in GIC to increase the surface area for mechanical interdigitation with composites to be overlaid (Fig.5).

A minimal tooth preparation, in the form of circumferential chamfer was carried out around the occlusal surface to freshen up and expose the enamel rods transversely, to increase surface area for acid etching, to have good peripheral seal and to have definite margin for finishing. Following cotton roll isolation, application of customized matrix band and wedging, the preparation including GIC was acid etched and bonded (Single bond, 3M). The crown augmentation was done using various shades of direct posterior composite resin (Z100, 3M), priorly selected by shade mapping (Fig. 6& 7). Following occlusal adjustment, finishing and polishing of the restoration, pit cavities were made (Fig 8), in the centric and eccentric contacts marked on the restoration and filled with Silver amalgam (Dispersalloy, Dentsply), using All bond 2 (BISCO) to act as occlusal stops (Fig.9).

Finally the TPA appliance was recemented on 16 and composite augmented 26 using GIC (Fuji I, GC corp) and reactivated in the same appointment (Fig. 10). Following two years of recall, the canines were completely erupted and well aligned in the arch and 26 was asymptomatic with intact restoration (Fig.11&12).

Discussion

Ankylosis of permanent tooth, in prepubertal period leads to cessation of alveolar growth, infraocclusion and its aftermath i.e. occlusal disharmony (crowding, tipping, supraeruption etc) and periodontal problems. Hence extraction of such a tooth is indicated. However, untimely or premature extraction before the completion of skeletal growth, can also lead to alveolar atrophy and tipping of molars, erupting distal to it. On the other hand, an ankylosed tooth due to its immobility can provide effective anchorage for orthodontic traction and serves as a natural stop gap till the ceasing of growth spurts and attainment of functional occlusion. Such advantages can be exploited by surgical orthodontics or restorative means^{1,4}.

In this patient, 27 was partially erupted and use of left maxillary premolars for anchorage would have led to loss of space. Hence infraoccluded 26 was the only

molar available and more suitable for anchorage due to its ankylosis and resultant immobility but the lack of adequate clinical crown height was an obstacle. Increasing the crown height in this patient by surgical luxation with or without orthodontic repositioning would have been traumatic and time consuming. Also the possibility of reankylosis or fracture of embrittled 26 (due to the root canal treatment) always existed. Hence crown augmentation of 26 by restorative means was preferred.

Though 26 was poorly obturated, no retreatment was attempted as it was asymptomatic and the long term prognosis was uncertain. Also an interim restoration was opted instead of the definitive one for crown augmentation to facilitate orthodontic treatment. Apart from withstanding orthodontic forces during anchorage, the other objectives of this crown augmentation on 26 were to, facilitate early reactivation of the appliance, serve as a post endodontic restoration and prevent drifting of the adjacent and opposing teeth. Further it had to serve as a suitable core in case of any crown requirement and be less expensive, as the longevity of the tooth was questionable. In this context, a bilayered (sandwich) restoration using both direct composite resin and GIC was considered for crown augmentation⁵. Though aesthetic was not of prime concern, the bulk of augmentation consisted of composites due to its micromechanical bonding and tooth reinforcement, good compressive strength, single visit procedure, immediate functioning and less expense when compared to indirect restorations⁶. GIC was used to overcome the deficiencies of composites like polymerization shrinkage, micro leakage and lack of anticariogenicity⁵. Further this posterior bilayered restoration was modified by using silver amalgam to avoid composite wear and act as occlusal stop to prevent unwanted drifting of the opposing tooth during the orthodontic treatment.

Conclusion

An ankylosed tooth due to its immobility can provide effective anchorage for orthodontic treatment. The crown augmentation of an ankylosed, infraoccluded 26 using modified bilayered restoration improved the anchorage and successfully withstood the orthodontic traction forces employed for forced eruption and alignment of bilaterally impacted maxillary canines.

References

1. Moyers RE. Handbook of Orthodontics, 4th ed, Year book of medical publishers, Inc.388-447
2. Cohen C, Burns RC. Pathways of pulp, 8th ed, 2002, Mosby, Inc.603-649 and 765-795

3. Graber TM, Vanarsdall RL. Orthodontics current principles and techniques, 3rd ed, Mosby, Inc. 829-836
4. McNamara TG, O'Shea D, McNamara CM et al. The management of traumatic ankylosis during orthodontics: A case report. Clin. Paed. Den 24:2000, 265-267.
5. Parmeswaran A, Kathikeyan KS. Materials in restorative dentistry. 1998, CBS. 191
6. Roberson TM, Heyman HO, Swift Jr EJ. Sturdevant's Art and science of operative Dentistry, 4th ed, 2002, Mosby, Inc. 473-650