

Primary tuberculosis of the thyroid gland

Dawka S¹, Jayakumar J², Ghosh A³

¹Associate Professor in Surgery, ²Assistant Professor in Medicine, ³Assistant Professor in Pathology, Manipal College of Medical Sciences, Pokhara, Nepal.

Abstract

Tuberculosis of the thyroid is rare even where tuberculosis *per se* is common. We report a case of primary tuberculous goitre in a young man from mid-western Nepal.

Key words: thyroid tuberculosis, tuberculous goitre.

Tuberculosis of the thyroid gland is rare. Despite the high incidence of tuberculosis in the Indian subcontinent, there have been few cases reported from this part of the world. Tuberculosis is rarely considered in the differential diagnosis of goitre or midline neck swellings. We report a case of a 26 year old man presenting with primary thyroid tuberculosis.

Case report

NP, a 26 year old male from Benibazaar, Myagdi presented with a mildly painful swelling in front of the neck for 1 month. There were no symptoms of thyrotoxicosis, weight loss, cough, fever or hemoptysis. There was no past or family history of tuberculosis.

Examination revealed a WHO grade II goitre measuring 4.5cm in its maximal transverse diameter with a nodule palpable on the right. Tenderness was mild and subjective. There was no cervical lymphadenopathy. BCG scar was absent.

FNA revealed: "Epithelioid granulomas in a background of extensive caseous necrosis along with neutrophils, lymphocytes and histiocytes suggestive of tuberculous etiology". Even on repeating, AFB were not identified by Ziehl-Neelsen stain. The haemogram and ESR were normal. Mantoux test

showed induration of 15 mm at 72 hours. The chest x-ray as well as thyroid profile were normal and sputum samples were negative for AFB.

The ultrasound scan showed a normally vascular goitre with no echogenic focus and no cervical lymphadenopathy.

A diagnosis of tuberculosis of the thyroid was considered and the patient was counseled and started on ATT category 3. Six months later the goitre had regressed totally.

Correspondence

Dr. Sushil Dawka
Department of Surgery,
Manipal Teaching Hospital, Phulbari
Pokhara, Nepal.
Email: sushil.dawka@gmail.com

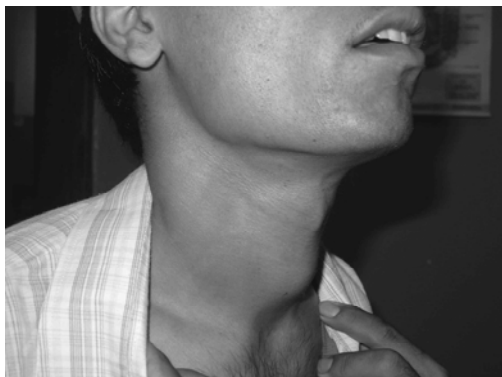

Fig 1: Tuberculous goitre in a 26 year old male

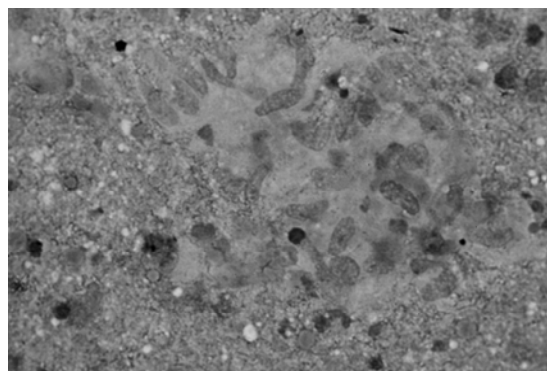


Fig 2: Epithelioid granuloma with caseous necrosis - (H&E, 400X)

Discussion

Thyroid tuberculosis is rare even in countries where tuberculosis is common, and primary disease is even rarer.^{1,2,3} In a comprehensive review of the English language literature in 2006 Bulbuloglu et al tabulated 76 cases reported by various studies worldwide.¹ While ten of these studies originated in India, to the best of our knowledge, no case has heretofore been reported from Nepal (Bulbuloglu, personal communication).

Traditional teaching states that the thyroid, like the pancreas and striated muscle, is resistant to tuberculosis. This has been attributed to high vascularity, rich lymphatics, strong capsule, cellular paucity and enhanced phagocytosis as well as the bactericidal effect of colloid and iodine.^{1,4}

In a study of 1283 thyroid FNAs over two years, Das et al reported tuberculosis in eight (0.6 %).⁵ However, Sahoo et al reported 2 cases (0.006%) of thyroid tuberculosis out of 32,030 thyroid FNAs from 1992-2004.⁴ In his review Simkus quoted the range in the literature as being from 0.1-1%.³

Thyroid tuberculosis may be primary or result from contiguous or hematogenous spread. Five patterns have been described: multiple lesions associated with miliary tuberculosis, goitre with caseation, cold abscess formation, chronic fibrosing tuberculosis and acute abscess.^{1, 3, 6, 7} Symptoms are usually mild and nonspecific. Thyroid function is rarely altered and a high ESR or a positive tuberculin test may be the only indicators.¹

Thyroid tuberculosis is rarely suspected clinically unless the patient has known tuberculosis or there is an associated sinus or tuberculous lymphadenopathy. Most often it is diagnosed from histopathology specimens or by FNA⁴ where the characteristic epithelioid cell granulomas with Langhans giant cells, caseous necrosis and peripheral lymphatic cuffing are strong evidence.⁷ It may not be possible to stain or culture AFB from aspirated material.^{2,8}

Treatment is primarily medical, with the role of surgery confined to abscess drainage to prevent parenchymal destruction. Aspiration is preferred as incision may cause sinus formation. A correct diagnosis will avert unnecessary surgery for suspect cold nodules, as the response to ATT is rapid.⁹

Conclusion:

In our case, despite being unable to demonstrate AFB, the diagnosis was based on the cytology as well as the positive tuberculin test and was confirmed by the rapid response to antituberculous chemotherapy.

Acknowledgement:

We thank Dr Renju Kurian for his help with the microphotography.

References

1. Bulbuloglu E, Ciralik H, Okur E, Ozdemir G, Ezberci F, Cetinkaya A. Tuberculosis of the Thyroid Gland: Review of the Literature. *World J Surg* 2006; 30: 149-155

2. Abdulsalam F, Abdulaziz S, Mallik AA. Primary Tuberculosis of the Thyroid Gland. *Kuwait Med J* 2005; 37: 116-118
3. Šimkus A. Thyroid tuberculosis. *Medicina* 2004; 40: 201-204
4. Sahoo M, Kaushik S, Bhatnagar A, Kashyap R. Role of Fine Needle Aspiration Cytology, Ultrasound and Tc99m Scan in the Diagnosis of Thyroid Tuberculosis. *IJNM* 2005; 20: 83-87
5. Das DK, Pant CS, Chachra KL, Gupta AK. Fine needle aspiration cytology diagnosis of tuberculous thyroiditis. A report of 8 cases. *Acta Cytol* 1992; 36: 517-522
6. Parmar H, Hashmi M, Rajput A, Patankar T, Castillo M. Acute tuberculous abscess of the thyroid gland. *Australas Radiol* 2002; 46: 186-188
7. Balsarkar D, Joshi MA, Dhareshwar J, Satoskar RR, Awsare N, Mahey R, Kumar V. Primary Thyroid Tuberculosis. *Bombay Hosp J* 1999; 41 (2). http://www.bhj.org/journal/1999_4102_apr99/case_333.htm
8. Khan EM, Haque I, Pandey R, Mishra SK, Sharina AK. Tuberculosis of the thyroid gland: a clinicopathological profile of four cases and review of the literature. *Aust N Z J Surg* 1993; 63: 807-10
9. Talwar VK, Gupta H, Kumar A. Isolated Tuberculous Thyroiditis. *JACM* 2003; 4: 238-9