

Empyema thoracis

Singh DR¹, Joshi MR², Thapa P², Nath S³

¹Assistant Professor, ²Lecturer, ³Professor, Department of Surgery, Kathmandu Medical College Teaching Hospital

Abstract

Objective: To review the management of Empyema Thoracis in the surgical department of Kathmandu Medical College Teaching Hospital.

Methods: Thirteen cases with Empyema thoraces treated in the surgical department of the hospital with different modalities of treatment was taken for study and analyzed for morbidity, mortality, and hospital stay.

Results: there was a single mortality in the thoracotomy group. Video assisted thoracic surgery or VATS debridement or deloculation was successful in the eight of the patients with shorter stay in the hospital. One patient who refused surgery was treated with streptokinase with good result.

Conclusion: Streptokinase may be effective in the treatment of empyemas. Video assisted thoracic surgery or VATS has definite advantage over traditional surgery in terms decreased morbidity, mortality, earlier hospital discharge and cosmesis in the treatment of empyema.

Keywords: Empyema thoracis, VATS, Decortications, Streptokinase

Empyema is collection of infected fluid in the pleural cavity which can be either loculated or diffuse. The American Thoracic Society (1962) have divided Empyema Thoracis in three stages viz. Exudative or (Stage I) in which empyema is of low viscosity and the lung expands easily following chest tube drainage, Fibrinopurulent or (Stage II) in which there is abundant leucocytes and fibrin deposition in the visceral and parietal pleura and Organizing or (Stage III) empyema in which there are features of chronic inflammation and the wall of the empyema organizes with the ingrowths of capillaries and fibroblasts (Fig.1).

Parapneumonic effusion is the commonest cause of Empyema. Twenty to sixty percent of hospitalized patients for pneumonia develop parapneumonic effusion and of those five to ten percent go on to develop empyema. Mortality rate is high at 25- 75% in the elderly¹. With the advent of antibiotics, there has been a dramatic decline in the incidence of empyema with resurgence in recent years in immune compromised patients in the western population². Though there are no statistics for our country, we can reasonably assume that the incidence is higher due to rampant malnutrition and poverty. It is a neglected disease since it occurs in poor and elderly patient population. Moreover thoracic surgery facilities are limited in the country.

Materials and methods

Retrospective study was done on all the 13 patients that were referred for the management of empyema

to the surgical department of Kathmandu Medical College Teaching Hospital (KMCTH) from paediatrics and medical departments. Cases referred from the paediatric department simply for chest tube insertion and got better with it were excluded from this study. Patients were analyzed according to age, sex, type of treatment and morbidity and mortality. One 26 year old male patient was treated with Intrapleural instillation of streptokinase because he absolutely refused any kind of surgery. 250,000 units of streptokinase dissolved in 100ml of normal saline was instilled through the chest tube and was clamped for 3 hours and released for three consecutive days.

Video Assisted Thoracic Surgery (VATS) deloculation or debridement was carried out in 9 patients. One patient needed to be converted to open thoracotomy due to failure of expansion of the lung. VATS debridement was done under general anaesthesia with double lumen tube, single lung ventilation in lateral position. We have been using 0° lens system while others recommend 30° lens system for better visualization of the recesses³. The lung is ventilated intermittently both to facilitate the peeling off up the fibrinous adhesions and assess the adequacy of lung expansion (Fig 2).

Correspondence

Dr. Deepak Raj Singh
Assistant Professor,
Department of Surgery,
Kathmandu Medical College, Sinamangal, Kathmandu
Email: drsingh5@yahoo.com

The camera port is placed in the previously inserted chest tube site as all of our patients were referred from the medical ward after failure of thoracostomy drainage. Debridement is done by suction irrigation system and sponge holder through a separate port site. Single chest tube was left in the dependent site under vision for water seal drainage and other port sites were closed.

Decortication was carried out under general anaesthesia with double lumen tube, single lung ventilation on 4 patients. Three of these patients were before we started doing VATS procedure in the

department. One patient needed conversion to formal thoracotomy. The incision was over the 6th rib with rib resection. Both the parietal and visceral pleura were removed with intervening infective material. Two chest tube one at the apex and another at the base were inserted in situ for water seal drainage before the incision was closed.

Chest tube drain was removed in all cases when the drain was less than 150ml in 24 hours. Chi square statistical test was applied to find the statistical significance of duration of chest tube drainage and mortality in the VATS group and thoracotomy group.

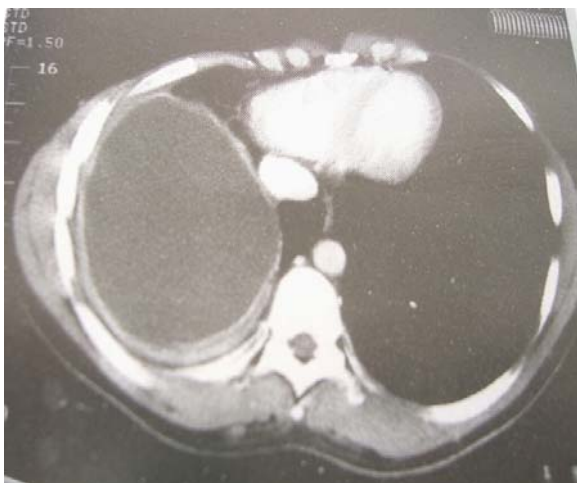


Fig 1: CT of the Empyema of the Right Chest

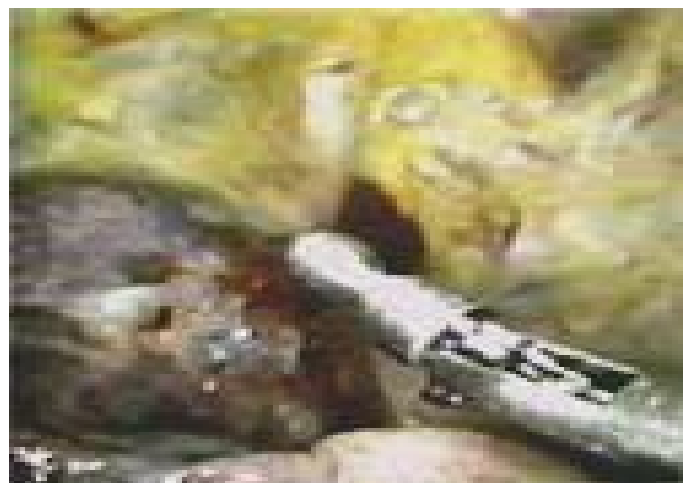

Fig 2: VATS Deloculation

Results

The patient population age ranged from 14 years to 72 years. Only three of the patients were under thirty whereas the rest were above 60 years old (Fig 3). Only one of the patients was a girl of 14 and all the rest were males (Fig 4). Two of the patients had tubercular empyema of which one of them presented with Empyema necessitatis. Rest of the others had pyogenic empyema (Fig 5). There was no major morbidity or mortality in the VATS group though one required conversion to thoracotomy and formal decortication due to dense attachment of visceral pleura to the lung.

Duration of chest tube drainage varied between 2 to 4 days in the VATS group and they could be discharged earlier. Chest tube drainage in

thoracotomy group ranged from 5 to 12 days. In the case of one patient with streptokinase instillation, drainage was copious after instillation of streptokinase and the drain was left for a period 11 days (Fig 6). Chi square analysis was done as to the duration of drainage and mortality between the VATS group and thoracotomy group. Both were found to be statistically significant in favour of the VATS group (Table 1).

Conversion to open thoracotomy was done in one patient as the lung did not expand due to dense visceral pleural trapping. One 72 year old patient died due to recalcitrant arrhythmia in the first post-operative day. This is an ongoing study and since the sample is small, firm conclusion cannot be drawn.

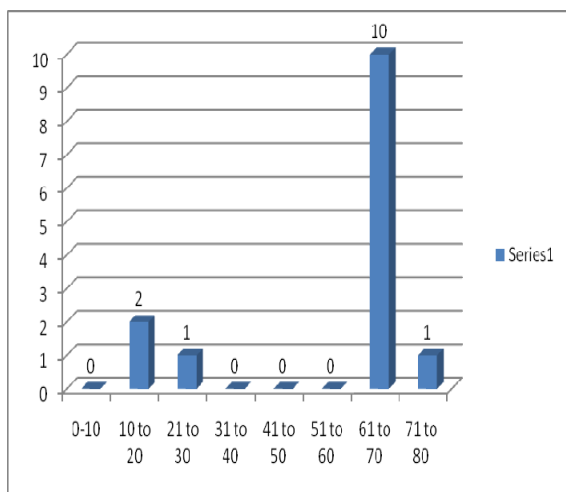


Fig 3: Age distribution

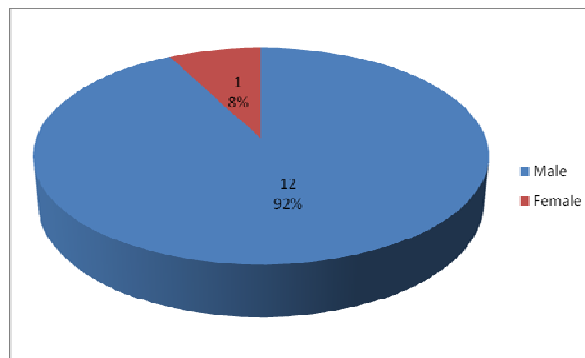


Fig 4: Sex distribution

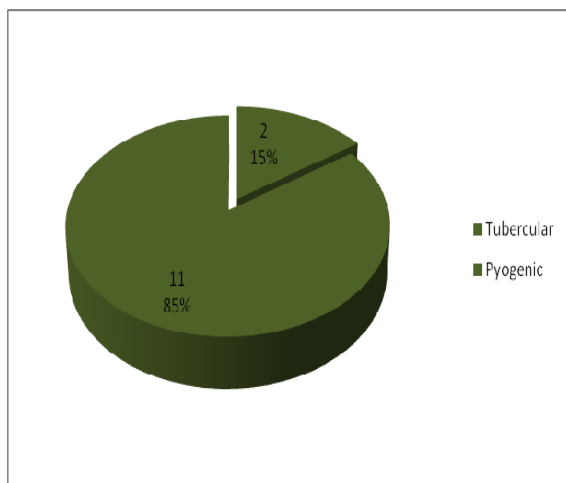


Fig 5: Distribution according to pathology

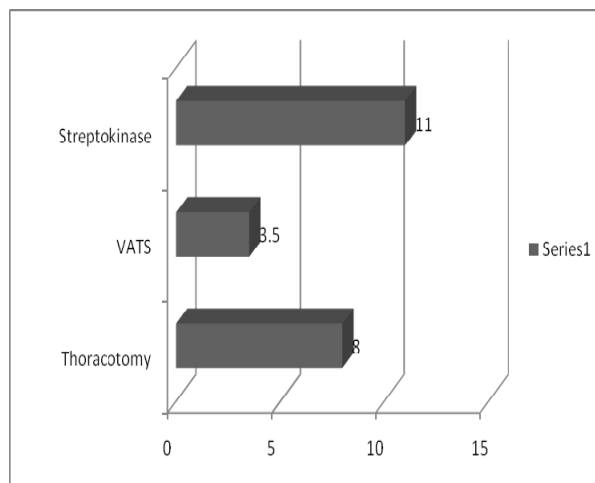


Fig 6: Duration of chest tube drainage

Table 1: Distribution and Analysis of patients according to chest tube drainage and mortality

Treatment Modality	Number of Patients	Average duration of chest tube drainage	Chi square test	Mortality	Chi square test
Streptokinase Instillation	1	11days		0	
VATS Debridement	8	3.5days	P <0.05	0	P <0.05
Thoracotomy Decortications	4	8days		1	

Discussion

This is an ongoing study in the department and the preliminary data on the 13 patients show the advantage of Video assisted thoracoscopic surgery or VATS debridement for empyema thoracis. Overwhelming number of our patients were males. 77% of the patients were aged over 60 years. We had two tubercular empyemas in this series accounting for 15% of the patients. Whereas literature report 3% of empyema thoracis to be tubercular as opposed to pyogenic⁴

Instillation of Intrapleural fibrinolytic as streptokinase could be an attractive alternative to those refusing surgery but with only one case in our series, we cannot make a definite statement. The two commonest side effects of streptokinase mentioned are fever and hypotension. Our patient did not suffer from either. Robinson presented a series of 13 consecutive patients treated with fibrinolytic instillation and reported success in 10^{5,6}.

Following the success of laparoscopic cholecystectomy in the 1980s, video assisted thoracic surgery or VATS in short followed suit. With the improvement in instruments, VATS procedures have progressed in leaps and bounds. One of the best indications for the applications of VATS is in the treatment of empyema⁷. This is because VATS is a minimally invasive procedure for these critically ill patients who can ill tolerate thoracotomy⁸. In a prospective randomized trial comparing VATS with tube thoracostomy with Intrapleural streptokinase, Wait et al reported superior results with VATS debridement⁹. After considerable experience with laparoscopy, our preliminary experience with VATS has been satisfying. Out of the 9 patients subjected to VATS for empyema, one needed conversion to thoracotomy due to dense adhesion. Rest had good expansion of the lung and could be discharged within 7 days.

Conversion to open method may be called for and should not be taken as failure of thoracoscopy⁷. Many centres are undertaking VATS decortications for Stage III empyema as well^{8,9} though this has not been the standard practice as yet.

In the thoracotomy decortication group, we lost one patient. This 72 year old man died in the 1st post-operative day due to arrhythmia that did not respond to treatment.

Our early experience with VATS debridement of empyema has been encouraging. We did not

encounter any major morbidity or mortality. Over 70% of our patients were above 60 years; indeed minimally invasive surgery is the treatment of choice for these elderly ill patients who find it hard to withstand the trauma of more invasive thoracotomy and formal decortication⁸.

Conclusion

Video assisted thoracic surgery or VATS is treatment of choice for empyema provided it is in the Fibrinopurulent stage. It causes less physiological trauma, very little pain compared to thoracotomy, less duration of chest drainage and better cosmetic results.

Our hospitals should embrace VATS debridement of empyema to avoid open decortication which is a formidable surgery in these sick elderly patients with substantial mortality.

Physicians caring for empyema patients should refer these patients at an early stage before Organizing or Stage III empyema ensues when VATS debridement may not be possible.

References

1. Robert B. Lee: Empyema Thoracis. In Stephen C. Yang et al editors: Current Therapy in Cardiovascular and Thoracic Surgery, Mosby 2004:293-296
2. Delarue NC: Empyema: Principles of management – an old problem revisited. In Deslauriers et al ed. : International Trends in General Thoracic Surgery, Vol 6. St.Louis, Mosby-Year Book 1990.
3. Cristopher B. Komanapalli: Thoracoscopic Decortication. CTSNet 19-Oct-2006
4. Raveenthiran V : Empyema thoracis: controversies and technical hints. Journal of Indian Association of Pediatric Surgeons 2005;10:3:191-194
5. Robinson LA et al: Intrapleural fibrinolytic treatment of multiloculated empyemas. Ann Thorac Surg 1994;57:803
6. Cameron R. et all. Intrapleural fibrinolytic therapy versus conservative management in the treatment of parapneumonic effusions and empyema. Cochrane Database Syst Rev. 2004(2):CD002312
7. Francisco Paris et al: Empyema and Bronchopleural Fistula. In F. Griffith Pearson et

- al editors – Thoracic Surgery 2nd ed. Churchill Livingstone 2002:1171-1190
8. Roberts JR. Minimally invasive surgery in the treatment of empyema:intraoperative decision making. *Annals Thoracic Surgery* 2003;76:225-30.
 9. Wait MA, et al: A randomized trial of empyema therapy. *Chest* 1997;111:1548
 10. Waller DA, Rengarjan A. Thoracoscopic decortications: a role for video-assisted surgery in chronic postpneumonic empyema. *Ann Thorac Surg* 2001;71:1813-6.
 11. Andrew J Drain et al: Definitive management of Advanced Empyema by Two-Window Video-Assisted Surgery. *Asian Cardiovasc Thorac Ann* 2007;15:238-239