

Chilaiditi's syndrome

Hazra NK¹, Panhani ML¹, Tiwari PK², Gupta A¹

¹Department of General Surgery, ²Department of Radiodiagnosis, Manipal Teaching Hospital, Pokhara, Nepal

Abstract

Chilaiditi's Syndrome is an entity where a loop of the intestine gets interposed between the liver and the diaphragm on the right side and radiologically shows up as gas under the diaphragm, when there is no actual perforation. This causes concern for the treating surgeon and may result in laparotomies uncalled for. We present two cases of Chilaiditi's Syndrome out of which one had an interposed small bowel loop and was operated upon after making a diagnosis of perforation peritonitis. Other was associated with sigmoid volvulus and was managed conservatively. Review of literature regarding aetiology and associated causes has been done in this study.

Key words - Chilaiditi's sign, Chilaiditi's syndrome, cirrhosis, ascites, sigmoid volvulus.

Chilaiditi's syndrome known as the interposition of the intestine between liver and right diaphragm (Hepatodiaphragmatic interposition, HDI) is a rare entity. It is frequently experienced in aged people, particularly in men. An increased prevalence in elderly suggests that the disease is an acquired condition.

Usually this syndrome presents as an asymptomatic X-Ray finding (Chilaiditi's sign)², although occasionally it is associated with a broad range of gastrointestinal symptoms suggestive of intestinal obstruction. The hallmark of therapy is conservative, and rarely has surgical intervention been indicated.

There has been reports of colonic volvulus associated with this condition^{1,2}. Colonic elongation and laxity of colonic and hepatic suspensory ligaments are the principal predisposing factors to these two entities². Other probable contributing factors are: (a) a redundant bowel with increased mobility, (b) an enlarged lower thoracic outlet in conditions such as pregnancy, emphysema, and cirrhosis with ascites, (c) an atrophic liver of post-necrotic cirrhosis, which leaves adequate space for intrusion of adjacent bowel segment³.

Awareness of Chilaiditi's sign facilitated distinguishing this condition from free gas under the diaphragm due to bowel perforation and subphrenic abscess by gas forming micro-organisms⁴. Recognition is important because this syndrome can be mistaken for more serious abnormalities, which may lead to unnecessary surgical intervention.

We report two cases of Chilaiditi's syndrome one of whom presented with air under diaphragm and was

considered a case of perforation peritonitis and was operated. The second case was sigmoid volvulus associated with Chilaiditi's syndrome and was managed conservatively. Higher awareness and suspicion of this entity is needed to prevent unwarranted surgeries.

Case reports

Case 1 – A 64-year old woman presented to us in the Emergency department with a history of pain abdomen, vomiting and distension for 2 days. She was dehydrated and abdominal examination showed distension, minimal guarding and ascites. Haematological investigations were normal although biochemistry showed deranged renal function tests (blood urea: 103mg/dl, serum creatinine: 2.4mg/dl) X-ray of the abdomen (Fig 1) had shown multiple fluid levels and gas under the right hemi diaphragm. Ultrasound was suggestive of dilated bowel loops with free fluid in the abdomen. A provisional diagnosis of acute intestinal obstruction with perforation of hollow viscus was considered. After proper hydration an exploratory laparotomy was performed. Peroperatively, there was copious ascitic fluid, but no perforation of any hollow viscus was found. A loop of the ileum had interposed between the diaphragm and the right lobe of the liver in a recess. This was extricated out. Postoperative period was uneventful and the patient recovered with respect to her complaints. Ascitic fluid analysis was exudative with predominantly lymphocytes. There were no malignant cells. One month

Correspondence

Dr. N.K. Hazra
Department of General Surgery,
Manipal Teaching Hospital, Pokhara, Nepal
E-mail: niranjan_hazra@yahoo.com

post-operatively she was asymptomatic. She was lost to follow up after this.

Case 2 85 year old male presented with features of large bowel obstruction. Digital rectal examination did not reveal any rectal pathology. X-ray of the abdomen showed large amount of gas under the diaphragm and massive dilatation of the large bowel and gas fluid levels (Fig.2). X-ray also showed features of advanced

spondylosis, and scoliosis. USG abdomen showed mild ascites, with bowel loops interposed between the right hemi diaphragm and the liver. Provisional diagnosis of sigmoid volvulus with Chilaiditi's syndrome was considered. A flatus tube introduced yielded copious gas and small amounts of liquid stool resulting in amelioration of the condition. Subsequent sigmoidoscopy showed no pathology in the rectum or sigmoid colon. Patient remained asymptomatic in the follow up till the time of writing this paper.

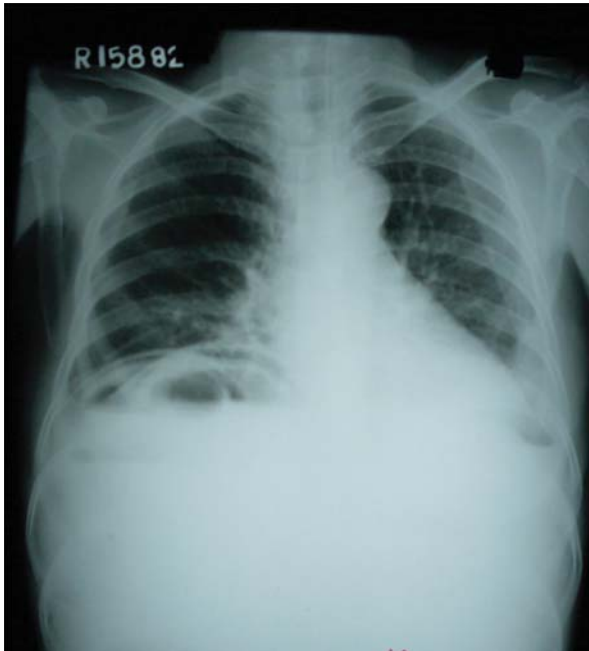


Fig 1: Air under right hemidiaphragm with air fluid level due to ileal loop interposition between diaphragm and liver.

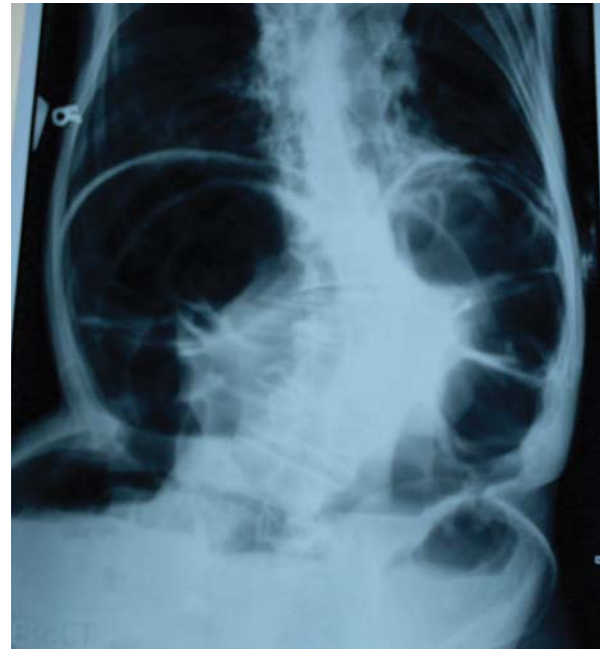

Fig 2: Dilated loops of large intestine with air fluid level due to sigmoid volvulus showing as gas under the diaphragm with scoliosis.

Discussion

Hepatodiaphragmatic interposition of the bowel is frequently an asymptomatic and rare clinical condition which remains asymptomatic and thus undiagnosed throughout one's life. It occurs in increased proportions in patients with ascites, chronic lung disease, and post necrotic cirrhosis. There are factors related to all the three components of this entity i.e. liver, diaphragm and intestine that induce progression of Chilaiditi's syndrome. The atrophic or small liver, post necrotic sudden liver shrinking, relaxation of suspensor ligaments are the various hepatic factors involved⁵. Absence of peritoneal attachments and redundant colon with a long mesentery, abnormal colonic motility, dilated colon and Colonic elongation are the principal predisposing intestinal factors⁶. A possible diaphragmatic factor is the abnormal position of diaphragm due to muscular degeneration caused by phrenic nerve injury⁶. Most of

them can be associated with various disorders including the colonic volvulus, supra-hepatic appendicitis, scleroderma, congenital hypothyroidism, melanosis coli, salmonellosis and obesity, which seem to be reasonably related or without clear relationship to the disease⁷.

Although it is usually asymptomatic and an incidental finding in the elderly population, several atypical presentations have been reported in the literature in the form of isolated case reports—and include nausea, vomiting, abdominal discomfort, substernal pain, constipation, partial obstruction, nocturnal vomiting, and recurrent volvulus involving transverse colon and both flexures. In plain X-ray of the chest, the appearance of air collection marking with haustral signs in the subdiaphragmatic area gives a strong hint

to diagnose. If there is uncertainty about the diagnosis then a contrast CT chest may help to confirm the diagnosis⁸. Once diagnosed this condition is mainly managed conservatively. But if there are signs of increased obstruction or there is development of signs of peritonism then surgical intervention may have to be done^{9,10}. The association of this entity with recurrent colonic volvulus¹¹(transverse colon¹², Sigmoid Colon volvulus¹³, obesity,¹⁴pancreatic malignancy,⁷ chest tube placement¹⁵ has been reported in the literature.

Conclusion

We report two cases of Chilaiditi's syndrome where the patients had presented with intestinal obstruction. First one had a loop of small intestine interposed between the liver and the right hemidiaphragm with ascites which may be the predisposing factor for the development of this condition. As the patient was showing some signs of peritonism she was operated upon. The second case had a sigmoid volvulus which was associated with gas under the diaphragm due to interposition of the gas filled, dilated colonic loop. This patient was managed conservatively.

As this condition rarely needs surgery and can be managed conservatively, increased awareness and higher degree of suspicion is required so that unwarranted surgeries can be avoided. Review of literature provides us the insight into the causes and the variety of associated conditions causing Chilaiditi's Sign and Chilaiditi's syndrome.

References

1. Orangio, Fazio VW, Winkelman E, McGonag BA. The Chilaiditi's syndrome and associated volvulus of the transverse colon An indication for surgical therapy. *Dis Colon Rectum*. 1986;29(10):653-6.
2. Plorde JJ, Raker EJ. Transverse colon volvulus and associated Chilaiditi's syndrome: case report and literature review. *Am J Gastroenterol*. 1996;91(12):2613-6.
3. VessalK, BorhanmaneshF. Hepatodiaphragmatic interposition of the intestine (Chilaiditi's syndrome). *Clin Radiol*. 1976;27(1):113-6.
4. Haddad CJ, Laclé J. Chilaiditi's syndrome. A diagnostic challenge. *Postgrad Med*. 199;89(4):249-50, 252.
5. Chan SC, Liu CL, Lo CM, Fan ST. Rapid onset Chilaiditi's sign on top of fulminant hepatic failure. *Hepatobiliary. Pancreat Dis Int*. 2004;3(3):476-7.
6. Saber AA, Boros MJ. Chilaiditi's syndrome: what should every surgeon know? *Am Surg*. 2005;71(3):261-3.
7. Demirbaş S, Kurt Y, Akin M, Oztürk A, Celenk T. Chilaiditi's syndrome with pancreatic malignancy. *Turkish J Cancer*. 2007;37(3):117-9.
8. Plorde JJ, Raker EJ. Transverse colon volvulus and associated Chilaiditi's syndrome: case report and literature review. *Am J Gastroenterol*. 1996;91:2613-6.
9. Altomare DF, Rinaldi M, Petrolino M, et al. Chilaiditi's syndrome. Successful surgical correction by colopexy. *Tech Coloproctol*. 2001;5:173-5.
10. Lohr CE, Nuss MA, McFadden DW, Hogg JP. Laparoscopic management of Chilaiditi's syndrome. *Surg Endosc*. 2004;18:348.
11. Matthews J, Beck GW, Bowley DM, et a. Chilaiditi's syndrome and recurrent colonic volvulus: a case report. *J R Nav Med Serv*. 2001;87:111-2.
12. Plorde JJ, Raker EJ. Transverse colon volvulus and associated Chilaiditi's syndrome: case report and literature review. *Am J Gastroenterol*. 1996;91(12):2613-6.
13. Chen SY, Liu CT, Tsai YC, Yu JC, Lin CH. Sigmoid volvulus and associated Chilaiditi's syndrome. *Rev Esp Enferm Dig*. 2007;99(8):482-3.
14. Murphy JM, Maibaum A, Alexander G, et al. Chilaiditi's syndrome and obesity. *Clin Anat*. 2000;13:181-4.
15. Gulati MS, Wafula J, Aggarwal S. Chilaiditi's sign possibly associated with malposition of chest tube placement. *J Postgrad Med*. 2008;54:138-9.