

Cervical Capillary Haemangioma: A Case Report

Sharma K,¹ Sharma UK,² Sigdel B³

¹Department of Neurosurgery

²Department of Radiodiagnosis

³Department of Pathology

B&B Hospital

Lalitpur, Nepal

Corresponding Author

Krishna Sharma

Department of Neurosurgery

B&B Hospital

Lalitpur, Nepal

Email: krishnasharma@yahoo.com

ABSTRACT

Capillary haemangioma is a common benign lesion occurring at multiple areas of body. They have unique radiological appearances and are confirmed by histological examinations. However capillary haemangioma of cervical region is a very rare condition. Such a case is presented here. It presented as an extramedullary intradural mass compressing the cord and corresponding root giving rise to myeloradiculopathic symptoms. Total enblock excision of the lesion gave a total cure.

KEY WORDS

Capillary haemangioma, cervical, enblock excision

Citation

Sharma K, Sharma UK, Sigdel B. Cervical Capillary Haemangioma: A Case Report. *Kathmandu Univ Med J* 2014;47(3):211-4.

INTRODUCTION

Capillary haemangioma in cervical region is a very rare entity but has a very typical radiological and histological character. They may have concurrent lesions in other parts of body. Such a case was encountered who presented with clinical features of a space occupying lesion in cervical region and is described here.

CASE-REPORT

A right handed 55 years' gentleman presented with complaints of 5 months' history of insidiously onset progressive pain on the back of head which started radiating to left upper limb up to the little finger since one month. The pain was associated with progressive numbness and paraesthesia of left sided limbs and stiffness of left shoulder. He had normal bladder and bowel habits. There was no history of fever, trauma or any other significant history. On examination, there was painful restriction of neck movement with no tenderness, deformity or bulge. The sensation was diminished along C7 dermatome with

spastic tone of the muscles of all four limbs. However there was no demonstrable weakness of the limbs. He had exaggerated deep tendon reflexes in all four limbs with positive Babinski's sign. There were no cutaneous or mucosal vascular lesions.

He was further investigated with MRI which revealed an intradural extramedullary mass at C7 level. The mass was isointense relative to cord on T1 weighted image and hyperintense on T2 weighted image and STIR. Intense enhancement of the lesion was seen in post contrast T1 weighted images. Associated cord edema was present showing hyperintensity on T2 weighted image at C5 to C7 level. The rest of the spinal cord including the conus medullaris and cauda equine regions were normal. The differential diagnosis thought were meningioma, schwannoma, metastasis or capillary haemangioma. Ultrasound of abdomen revealed small echogenic lesions in the liver, which was suggestive of haemangiomas or metastasis. He underwent triple phase CT scan of abdomen which revealed hypodense lesions in the liver,

showing early peripheral enhancement with centripetal filling of the contrast in delayed images, characteristic features for liver hemangiomas. CT scan brain was normal.

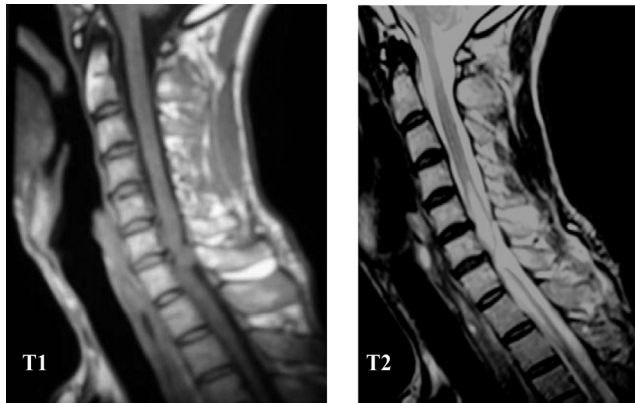


Figure 1. Contrast enhanced T1W1 sagittal image of cervical spine showing Capillary haemangioma at C7 level.

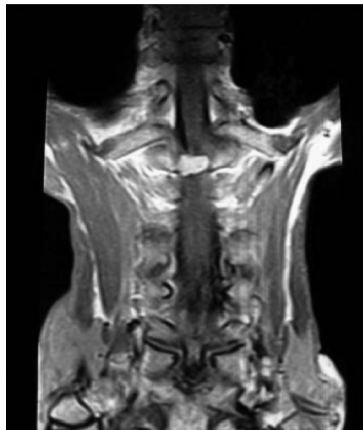


Figure 2. Contrast enhanced T1W1 coronal image of cervical spine showing Capillary haemangioma at C7 level.

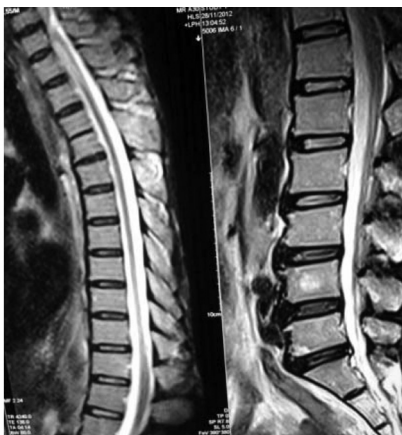

Figure 3. Sagittal images of dorsal and lumbar spine showing no other tumors.

He underwent laminectomy of C5 to C7 levels. A vascular 2cm by 2m by 4cm encapsulated soft, red, lobulated, intradural extramedullary mass, well demarcated from the underlying oedematous spinal cord was found at C6 to C7 level. It was not adherent to any root and had its vascular supply from small capillary twigs arising from vessels on posterior surface of spinal cord. It had no dural attachment. The lesion was totally excised in one piece. Postoperative

period was uneventful. However the paraesthesia and spasticity got only partially relieved.

Histopathology showed soft and dark brown colored tissue with blood clot on gross examination.

Microscopy revealed nodular circumscribed tumor with neoplastic proliferation of small capillary sized blood vessels containing red blood cells within their lumina. These were separated into vague lobules by myxoid stroma. Larger feeding vessels were also noted. No evidence of atypia or malignancy was seen. Based on these features histological diagnosis of Capillary Hemangioma was made.

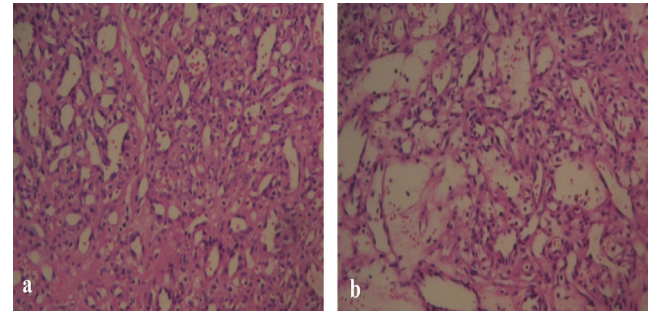


Figure 4. H & E stain of capillary hemangioma. (a) showing nodular circumscribed tumor with neoplastic proliferation of small capillary sized blood vessels. (b) High power view of the lesion.

No further immunohistochemistry was performed.

DISCUSSION

Intradural extramedullary capillary haemangioma of spinal cord are extremely rare tumors. Until now, 29 cases of spinal intradural extramedullary capillary haemangiomas have been reported. Moreover cervical region is a very rare site and only five cases have been so far documented in the literature.^{1,2} Hemangiomas are either capillary or cavernous types,³ more commonly involving skin and mucus membrane of head and neck region and are mostly cavernous type. Most of the spinal lesions have been described in the lower thoracic spinal cord, conus medullaris, and cauda equina.³ These are benign tumors or tumor-like vascular lesions, and have been labeled as malformations or hamartomas.⁴ They are usually located in the posterior part of the cord.⁵ They have been found more frequently in men and in elderly patients. Nonetheless, one of the types, capillary hemangiomas of infancy, occurs during infancy. They can be associated with other congenital anomalies and it is important to evaluate the patient specially the infants with cutaneous lumbosacral hemangiomas for underlying spinal cord abnormalities.⁶

Haemangiomas are well-defined, slow-growing vascular tumors. Haemangiomas of spinal cord present like a space occupying lesions (SOL). The common presentations are localized dull spine pain and mild tenderness, progressive myelopathy/radiculopathy leading to motor and sensory deficits along with gait and sphincter disturbances.^{3,5,7,8}

The haemangioma is a very friable mass and has tendency of recurrent bleeding (44% risk in intracranial location). They may present with sudden neurological deterioration due to bleeding, hematomyelia or subarachnoid hemorrhage.⁵ Review of literature revealed that, the first manifestations of the ten cases out of twenty-eight intra-dural extramedullary cavernous hemangioma was subarachnoid haemorrhage. Rarely there may be a concurrent intracranial lesion and may present with headache, dizziness, and bilateral sensorineural hearing loss caused by an intracranial superficial hemosiderosis as a result of chronic subarachnoid hemorrhage.² Even after total excision during surgery, symptoms remained in 25% of cases.¹

The investigation of choice is MR imaging.⁵ In MR images, the tumor showed isointensity relative to the spinal cord because of the slow blood flow on T1-weighted images and hyperintensity on T2-weighted images because of the high content of stagnant blood.⁹ There is also strong homogeneous enhancement on contrast-enhanced T1-weighted images and dural tail sign was observed in a few cases confusing it with meningioma. There is often ill-defined area of hyperintensity just above the tumor in the spinal cord, suggesting compressive myelopathy as seen in our case which mainly had cord compression effect. Two cases in the literature showed multiple intradural extramedullary lesions in the cauda equina nerve roots, conus medullaris, and lower spinal cord associated with perifocal edema.⁴ Multiplicity of lesions may be one of the features of capillary hemangiomas because multiple lesions often develop simultaneously in capillary hemangiomas of the skin and mucosa. The presenting case also had such a lesion in the liver which was confirmed to be haemangioma by triple contrast CT scan.^{4,10} Angiography demonstrated hypervascular lesions with subtly enlarged abnormal vessels but angiography was not performed in our case as MRI gave us the diagnosis quite precisely.¹ Spinal angiography is a useful investigation to differentiate non-vascular tumors from vascular tumors, and thus prevents the risk of intraoperative bleeding.¹

The differential diagnosis for intradural extramedullary tumors are neurinomas and meningiomas, both of which show marked enhancement on contrast-enhanced T1-weighted images. In neurinomas, the signal intensity usually is hypointense, less frequently isointense, on T1-weighted images, and hyperintense on T2-weighted images. Cystic change or necrosis could be seen within neurinomas. If there is no cystic change or necrosis within the tumor, neurinoma is difficult to differentiate from hemangioma. In meningiomas, the mass usually shows isointensity or slight hypointensity on T1-weighted images and isointensity or slight hyperintensity on T2-weighted images. It usually has broad-based dural attachment and frequently shows the dural tail sign on contrast-enhanced study. The signal intensity may be helpful to differentiate between meningioma and hemangioma, but the presence of the

dural tail sign appears to be not useful for the differentiation between these two, when the hemangioma arises from the inner surface of the dura matter. Intradural arteriovenous malformations can be differentiated by demonstrating vascular flow void radiologically. Hemangioendothelioma, which has been described to be intermediate between hemangioma and angiosarcoma, rarely occurs in the spinal intradural extramedullary space. The MR imaging findings of Hemangioendothelioma is similar to that of capillary hemangioma.⁹ Other intradural extramedullary tumors include paraganglioma, film terminale ependymoma, drop metastasis, sarcoidosis and lymphoma. They can be differentiated from capillary haemangioma by their typical MRI findings.

Capillary hemangioma are believed to originate from the abnormal development of periradicular vessels in the meningeal coverings or the vasa nervosum.⁹ The angiogenesis is governed by a complex interaction of proangiogenic and antiangiogenic factors. Basic fibroblast growth factor and VEGF are proangiogenic molecules and are often produced by tumor cells. It has been seen that the removal of the main lesion leads to decreased proangiogenic factors which has induced regression of the residual or concurrent other lesions. Corticosteroid drugs and IFN α are classified as antiangiogenic molecules, as are angiostatin, endostatin, and thalidomide. Use of these drugs could be effective in treating capillary hemangiomas of the CNS, as in capillary hemangiomas of the skin and soft tissues.

Capillary haemangioma are mostly located at the posterior or posterolateral portion of the thecal sac.⁵ Macroscopically they are well demarcated soft, red, lobulated, intradural extramedullary, vascular-rich masses not adherent to the root or the oedematous cord, with visible red veins around the mass. Evidence of hemorrhage could be associated with the lesion. Microscopically these lesions consist of numerous capillaries that are lined by flattened endothelium and are characterized by a lobular architecture, the lobules consisting of capillary-sized channels that are tightly aggregated into nodules, each of which is fed by a large artery. Stromal edema and occasional mitoses of endothelial cells and stromal fibroblastic cells were observed. Scattered stromal lymphocytes were present, but there was no evidence of foamy stromal cells. The reticulin stain highlighted the delicate network of reticulin fibers that surrounded the vessels.¹¹ Capillary hemangiomas of infancy are the immature form of capillary hemangiomas. The lumina of the vasculature in these lesions are narrowed by plump endothelial cells, which results in a solid appearance.³ Immunostaining is done with CD31, alpha-smooth muscle actin, vascular endothelial growth factor, and Ki-67 antigen.^{4,8}

Since the mass mostly presents as a space occupying lesion and with its inherent risk of bleed, early recognition and total en bloc surgical excision is the non-controversial first treatment.¹ With some report of benefit of steroid

resolving the residual and concurrent known or unknown lesions in spinal cord or brain, systemic administration of steroid drugs or interferon-alpha is an option.^{4,8} It has been reported that systemic administration of steroid drugs and IFN α before surgery could ameliorate and improve outcomes. Recurrence of capillary hemangiomas of the neuraxis has not yet been demonstrated. Nevertheless, because recurrence of capillary hemangiomas of the skin and soft tissues is not rare, follow-up imaging after resection is necessary.³

As is true in resection of any other intramedullary tumors, little neurological improvement or even worsening of

symptoms is possible and patient has to be explained about it and a written consent must be obtained before surgery.

CONCLUSION

Capillary haemangioma of cervical spine is a rare lesion, mimicking a variety of other lesions radiologically and histologically. The treatment is en bloc surgical excision but the symptoms may not always reverse by decompression. The role of steroid is not established but is promising. However early recognition and removal of the lesion gives the best chance for the patient to recover the most.

REFERENCES

1. Sonawane DV, Jagtap SA, Mathesul AA. Intradural extramedullary capillary hemangioma of lower thoracic spinal cord. *Indian J Orthop*. 2012 Jul;46(4):475-8.
2. Yong Jun Jin, Sang-Bong Chung, Ki-Jeong Kim, Hyun-Jib Kim. Spinal Intradural Extramedullary Cavernoma Presenting with Intracranial Superficial Hemosiderosis. *J Korean Neurosurg Soc*. 2011 June; 49(6): 377–80.
3. Chung SK, Nam TK, Park SW, Hwang SN. Capillary hemangioma of the thoracic spinal cord. *J Korean Neurosurg Soc*. 2010 Sep;48(3):272-5.
4. Abe M, Tabuchi K, Tanaka S, Hodozuka A, Kunishio K, Kubo N, Nishimura Y. Capillary hemangioma of the central nervous system. *J Neurosurg*. 2004 Jul;101(1):73-81.
5. Choi BY, Chang KH, Choe G, Han MH, Park SW, Yu IK et al. Spinal intradural extramedullary capillary hemangioma: MR imaging findings. *AJNR Am J Neuroradiol*. 2001 Apr;22(4):799-802.
6. Karikari IO, Selznick LA, Cummings TJ, George TM. Spinal capillary hemangioma in infants: report of two cases and review of the literature. *Pediatr Neurosurg*. 2007;43(2):125-9.
7. Rivierez M, Heyman D, Jouannelle A, Arfi S. Capillary hemangioma of the spinal cord. A new case. *Neurochirurgie*. 2002 Nov;48(5):440-4.
8. Roncaroli F, Scheithauer BW, Krauss WE. Capillary hemangioma of the spinal cord. Report of four cases. *J Neurosurg*. 2000 Jul;93(1 Suppl):148-51.
9. Mustafa Kemal Demir, MD, Huseyin Ozdemir, MD, Ercument Unlu, MD, Osman Temizöz, MD and Hakan Gençellac, MD. Differential Diagnosis of Spinal Epidural Meningioma and Hemangioma at MR Imaging. September 2007 *Radiology*, 244,933-934.
10. Abdullah DC, Raghuram K, Phillips CD, Jane JA Jr, Miller B. Thoracic intradural extramedullary capillary hemangioma. *AJNR Am J Neuroradiol*. 2004 Aug;25(7):1294-6.
11. Cetinkal A, Colak A, Topuz K, Atabey C, Berber U. Capillary hemangioma of the cervical intervertebral disc. *Eur Spine J*. 2011 Jul;20 Suppl 2:S157-60.