

# Leiomyoma of Broad Ligament Mimicking Ovarian Malignancy– Report of a Unique Case

Mallick D,<sup>1</sup> Saha M,<sup>2</sup> Chakrabarti S,<sup>2</sup> Chakraborty J<sup>2</sup>

<sup>1</sup>Department of Pathology

ESI PGIMSR & ESIC Medical College, Joka,

West Bengal, India

<sup>2</sup>ESI PGIMSR, Manicktala Kolkata,

West Bengal, India

## Corresponding Author

Debjani Mallick

Department of Pathology

ESI PGIMSR & ESIC Medical College, Joka,

West Bengal, India

Email: dr.debjani.m@gmail.com

## Citation

Mallick D, Saha M, Chakrabarti S, Chakraborty J. Leiomyoma of Broad Ligament Mimicking Ovarian Malignancy– Report of a Unique Case. *Kathmandu Univ Med J* 2014;47(3):219-21.

## ABSTRACT

Tumors of the broad ligament are uncommon. Leiomyoma, which is the commonest female genital neoplasm, is also the most common solid tumor of the broad ligament. Leiomyomas affect 30% of all women of reproductive age but the incidence of broad-ligament leiomyoma is <1%. These benign tumors are usually asymptomatic. A case is being described where a 52 year old presented with gradual abdominal swelling which was clinically and radiologically diagnosed as ovarian malignancy. On abdominal and bimanual palpation a soft cystic mass was noted in the right pelvic region. CA 125 was mildly raised. CEA, CA 19.9 levels were within normal limit. The radiological diagnosis was ovarian cyst with possibility of malignant changes. Staging laparotomy and histopathological examination of the resected specimen revealed a right sided broad ligament leiomyoma with cystic changes. The degenerative changes in the leiomyoma lead to the clinical and radiological diagnostic confusion. Thus, though uncommon, broad ligament leiomyoma should be considered during evaluation of adnexal masses for optimal patient management. The above description of leiomyoma in the broad ligament is a highly unique case and thus deserves appropriate attention.

## KEY WORDS

*Broad ligament mass, cystic changes, clinical and radiological diagnosis, leiomyoma.*

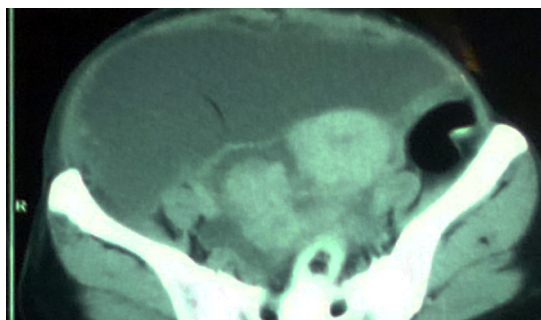
## INTRODUCTION

Extrauterine leiomyomas are rare and often present as a challenging diagnostic problem for the clinician and the radiologist.<sup>1</sup> Leiomyoma is the commonest female genital neoplasm, affecting 30% of all women of reproductive age. However incidence of broad-ligament leiomyoma is less than 1%.<sup>2</sup> Though benign, leiomyoma with additional degenerative changes may mimic malignancy of the adnexal organs, thereby leading to considerable diagnostic dilemma. One such case is being reported a broad ligament leiomyoma was clinically and radiologically mimicking malignancy.

## CASE-REPORT

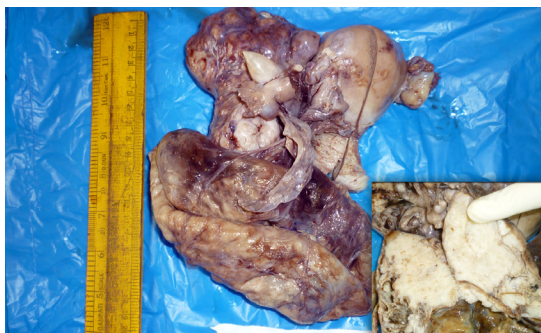A 52 years female presented with gradual swelling of abdomen. On abdominal palpation a soft cystic mass was

noted in the right pelvic region. No peripheral lymph node was enlarged. A bimanual pelvic examination revealed a large, immobile, lobulated mass in the right adnexal region measuring 18 cm x 9 cm. General examination showed mild pallor. There was no pleural effusion, no free fluid in the peritoneum, no retroperitoneal mass. Hemoglobin was 9.8 gm% and other hematological parameters were within normal range. Ultrasonography suggested a right ovarian cyst measuring 19 cm x 10 cm x 3.5 cm. To evaluate the possibility of an ovarian malignancy, serum CA 125, CEA, CA 19.9 levels were estimated. CA 125 was found to be mildly raised but CEA and CA 19-9 within normal limit (the values were 33.8 U/ml, 2.04 ng/ml, 32.5 U/ml respectively). Computer Tomography (CT) scan was done which reported bulky uterus with a giant complex cystic mass in abdomen arising from right adnexa suggesting an ovarian cystic mass



**Figure 1. Complex cystic right adnexal mass in Computer Tomography (CT) scan**

(figure 1), possibly adenocarcinoma could not be ruled out. Staging laparotomy with total abdominal hysterectomy and bilateral salpingo-oophorectomy was done which revealed a huge haemorrhagic tumor in right broad ligament. Grossly uterus and bilateral ovaries were normal. An ovoid mass arising from right broad ligament with hemorrhagic, variegated and bosselated appearance measuring 19 cm x 10 cm x 3.5 cm was noted. Cut section showed solid greyish white areas along with hemorrhagic cystic areas (Figure 2).



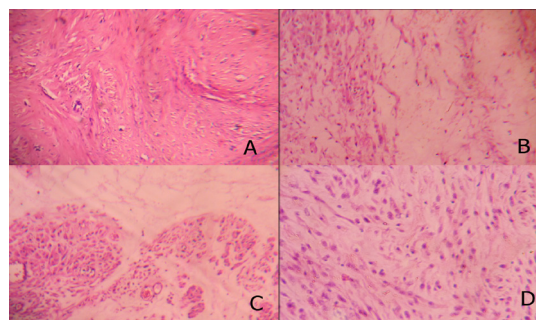
**Figure 2. Resected specimen showing a hemorrhagic bosselated broad ligament mass with uterus and bilateral ovaries grossly uninvolved. Inset showing cut section of the mass which is greyish white solid with cystic areas.**

Histologically, the mass showed features of leiomyoma with myxoid and hyaline degenerative changes (Figure 3A, 3B, 3C). No malignant changes were noted (Figure 3D). Right iliac lymph node showed sinus hyperplasia. Therefore final diagnosis of leiomyoma of the broad ligament was offered. Postoperative period was uneventful.

## DISCUSSION

Many women develop leiomyomas as they grow older. In one study, the prevalence of ultrasonographically identified tumors ranged from 4% in women aged 20–30 years to 11%–18% in women aged 30–40 years and 33% in women aged 40–60 years.<sup>3</sup> Our patient was 52 years old lady.

The broad ligament is a peritoneal fold that attaches the uterus, fallopian tubes, and ovaries to the pelvic sidewall. Disorders of the broad ligament are rare. Tumors of the broad ligament are uncommon. Leiomyoma is the most common solid tumor of the broad ligament.<sup>2</sup>



**Figure 3. Microphotographs of the tumor from different areas showing**

**A: Short interlacing bundles of smooth muscle cells. (H&E, X 100)**

**B: Smooth muscle cells with adjacent areas showing myxoid degeneration. (H&E, X 100)**

**C: Smooth muscle cells in cross section with hyaline degenerative changes. (H&E, X 100)**

**D: Spindle shaped cells with ovoid nuclei with no atypia or mitoses. (H&E, X 400)**

The most common presentations of leiomyomas are menstrual disturbances and dysmenorrhea. Broad-ligament leiomyomas are usually asymptomatic. However, these lesions can present with pressure symptoms, such as bladder and bowel dysfunction. If broad-ligament leiomyoma reaches a significant size, it can distort the anatomy of the pelvis, pushing the uterus to the contralateral side and it can potentially compress the ureter, which leads to hydronephrosis.<sup>2</sup> This patient presented with gradual swelling of abdomen.

A preoperative disease classification for patients with adnexal masses, in particular discrimination between benign and malignant ovarian tumors, is important for optimal patient management.<sup>2</sup> CA 125 level estimation is important in this respect. An elevated CA-125 serum level of at least 30 U/mL often indicates the presence of malignancy.<sup>4</sup> The level of serum CA-125 is often elevated in women with endometriosis and leiomyomas.<sup>5</sup> In our case CA 125 level was mildly raised ( 33.8 U/ml.)

Pattern recognition by ultrasound examination is another modality for discrimination between benign and malignant adnexal masses are considered superior to serum CA 125 estimation.<sup>6</sup> But this too has limitations as in our case the broad ligament leiomyoma mimicked ovarian cyst sonographically. The degenerative changes in the leiomyoma can lead to this confusion.

Hyaline degeneration is the most common of all the secondary changes in leiomyomas. Hyaline degeneration can involve broad areas and can also occur in broad ligament leiomyomas. Such changes can be associated with cystic degeneration of the tumor simulating an ovarian cyst. Myxoid degeneration may also occur in broad ligament fibroid causing error in diagnosis.<sup>7</sup> In the present case both hyaline and myxoid degenerations were present

leading to cystic areas in the mass. The CT findings were a giant cystic mass arising from right adnexa filling the abdominal suggesting an ovarian cystic mass, however could not rule out adenocarcinoma. Myxoid changes in benign smooth muscle tumors must be distinguished from myxoid leiomyosarcoma. Myxoid leiomyosarcoma shows infiltrative growth, extensive myxoid change and some degree of nuclear enlargement and pleomorphism.<sup>8</sup> However, histologically the cells were not pleomorphic and no nuclear atypia or mitosis was seen. Thus a benign broad ligament leiomyoma with degenerative changes can present with radiological diagnostic challenges.

Although nearly all women diagnosed with ovarian carcinoma initially present with an adnexal mass, only a small proportion of all adnexal masses detected are malignant. According to the literature a broad-ligament leiomyoma is not involved in the differential diagnosis of an adnexal mass as broad-ligament tumors have been

defined as that “occur in or on the broad ligament, but are completely separated from and in no way connected with either the uterus or the ovary”.<sup>9</sup> However due to anatomical close proximity, broad ligament tumors may be confused clinically as well as radiologically with adnexal neoplasms as happened in our case where the tumor, although located in the broad ligament, completely separated from uterus or ovary, was diagnosed as ovarian malignancy preoperatively.

## CONCLUSION

This case is unique in the respect of rare location of the leiomyoma in the broad ligament and also the diagnostic challenges that were created due to the degenerative changes in the leiomyoma which mimicked ovarian malignancy for which staging laparotomy was done. Leiomyoma though benign may be considered during pre-operative evaluation along with careful clinico-radiological correlation of patients with adnexal masses for their optimal management.

## REFERENCES

- Huang KG, Adlan AS, Lee CL, Lertvikool S. Isolated broad ligament leiomyomatosis. *J Obstet Gynaecol Res* 2011;37:1510-14.
- Yıldız P, Cengiz H, Yıldız G, Sam AD, Yavuzcan A, Çelikbaş B et al. Two unusual clinical presentations of broad-ligament leiomyomas: a report of two cases. *Medicina (Kaunas)* 2012;48:163-5.
- Lurie S, Piper I, Woliovitch I, Glezerman M. Age-related prevalence of sonographically confirmed uterine myomas. *J Obstet Gynaecol* 2005;25:42-4.
- Paramasivam S, Tripcony L, Crandon A, Quinn M, Hammond I, Marsden D et al. Prognostic importance of preoperative CA 125 in International Federation of Gynecology and Obstetrics stage I epithelial ovarian cancer: an Australian multicenter study. *J Clin Oncol* 2005;23:5938-42.
- Tsao KC, Hong JH, Wu TL, Chang PY, Sun CF, Wu JT. Elevation of CA 19-9 and chromogranin A, in addition to CA 125, are detectable in benign tumors in leiomyomas and endometriosis. *J Clin Lab Anal* 2007;21:193-6.
- Van Calster B, Timmerman D, Bourne T, Testa AC, Van Holsbeke C, Domali E et al. Discrimination between benign and malignant adnexal masses by specialist ultrasound examination versus serum CA-125. *J Natl Cancer Inst* 2007;99:1706-14.
- Godbole R R, Lakshmi K S, Vasant K. Rare case of giant broad ligament fibroid with myxoid degeneration. *J Sci Soc* 2012 ; 39 : 144-146.
- Chaouki M, Marouen N, Najet B M, Zied K, Anis B A, Hedhili O. An unusual presentation of uterine leiomyoma: Myxoid leiomyoma. *IJCRI* 2012;3:1-3.
- Gardner GH, Greene RR, Peckham B. Tumors of the broad ligament. *Am J Obstet Gynecol* 1957;73:554-555