

# Acetabular Fracture: Retrospective Analysis of Thirty Three Consecutive Cases with Operative Management.

Shrestha D, Dhoju D, Shrestha R, Sharma V

Department of Orthopaedic and Traumatology  
Dhulikhel Hospital, Kathmandu University Hospital  
Dhulikhel, Kavre

## Corresponding Author

Dipak Shrestha  
Department of Orthopaedic and Traumatology  
Dhulikhel Hospital, Kathmandu University Hospital  
Dhulikhel, Kavre  
E-mail: dsmsortho@gmail.com

## Citation

Shrestha D, Dhoju D, Shrestha R, Sharma V. Acetabular Fracture: Retrospective Analysis of Thirty Three Consecutive Cases with Operative Management. *Kathmandu Univ Med J* 2014;48(4):279-87.

## ABSTRACT

### Background

With the development of better imaging modalities including 3D CT scan and availability of technical expertise, operative management is increasingly performed for acetabular fracture but many patients in developing countries like Nepal, are still being treated with prolonged skeletal traction.

### Objective

To analyse epidemiology, types of acetabular fracture and functional and radiological outcome of patients with acetabular fracture treated with open reduction and internal fixation (ORIF).

### Method

Inpatients hospital records of patients treated with ORIF in between June 2007 to June 2014 were evaluated. Patient's demographic data, mode of injury, injury hospital interval, injury surgery interval, associated injuries, surgical approach, total hospital stay and peri and post-operative complications were recorded and radiological and functional outcomes were evaluated.

### Result

Thirty three patients (Male: 24 Female: 9) with average age 39 years (range: 21 to 65 years) were operated for acetabular fracture. Twenty one patients (63%) had injury related with motor vehicle accidents and nine (24%) of them had motorbike accidents. Injury hospital interval ranges from 7 to 36 days. Average injury-surgery interval was 21 days and average hospital stay was 22 days. Bicolumnar fractures were found in 15. Nine patients had dislocation of hip and 15 had concomitant other injuries. Bicolumnar fixation was performed in 15 patients, posterior column and or wall in nine with Kocher Langenbeck approach and anterior column and or wall in other nine with ilio-inguinal approach. Radiological reduction was anatomical in 18; excellent/good functional outcome was in 26 and radiological outcomes were excellent in 14. Three patients had developed Hypertopic ossification. Follow up period ranged from 6 to 48 months and 15 patients (45%) had follow up >2 years.

### Conclusion

Acetabular fracture can be effectively managed with ORIF and have predictable and comparable functional and radiographic outcomes. Upgrading the existing facilities and training of orthopedic surgeon for acetabular fracture management is important to shorten injury-surgery interval due to lack of such facilities.

## KEY WORDS

*Acetabulum, internal fixation, open reduction*

## INTRODUCTION

Acetabular fractures are increasing in developing countries as a result of rise in incidence of high energy trauma such as road traffic accidents.<sup>1-3</sup> Acetabular fracture needs well-planned treatment algorithm for optimal outcome in both conservative and operative protocols. Certain type of acetabular fractures can be treated with conservative management with good outcome, but many patients who would have been benefitted with open reduction and internal fixation (ORIF), in the absence of facilities to get operated, are treated with skeletal traction and prolonged bed rest leading to morbidities like joint stiffness, deep vein thrombosis, hypostatic pneumonia etc.<sup>4</sup> With the availability technical expertise and better imaging facilities including 3D CT Scan, operative options are increasingly available in developing countries as well. But operative management of acetabular fracture demands high level of technical skill, better understanding of three dimensional of pelvi-acetabular anatomy and team of orthopedic, general surgeon and anesthetist and supportive care of intensive care unit for effective management of fracture itself and concomitant other major abdominal visceral injuries and other complications if any.

Current study evaluates epidemiology, types and outcome of the acetabular fracture treated with ORIF in Dhulikhel Hospital and other hospitals where senior author (DS) is invited for acetabular fracture surgery and compares the results with other similar circumstances.

## METHODS

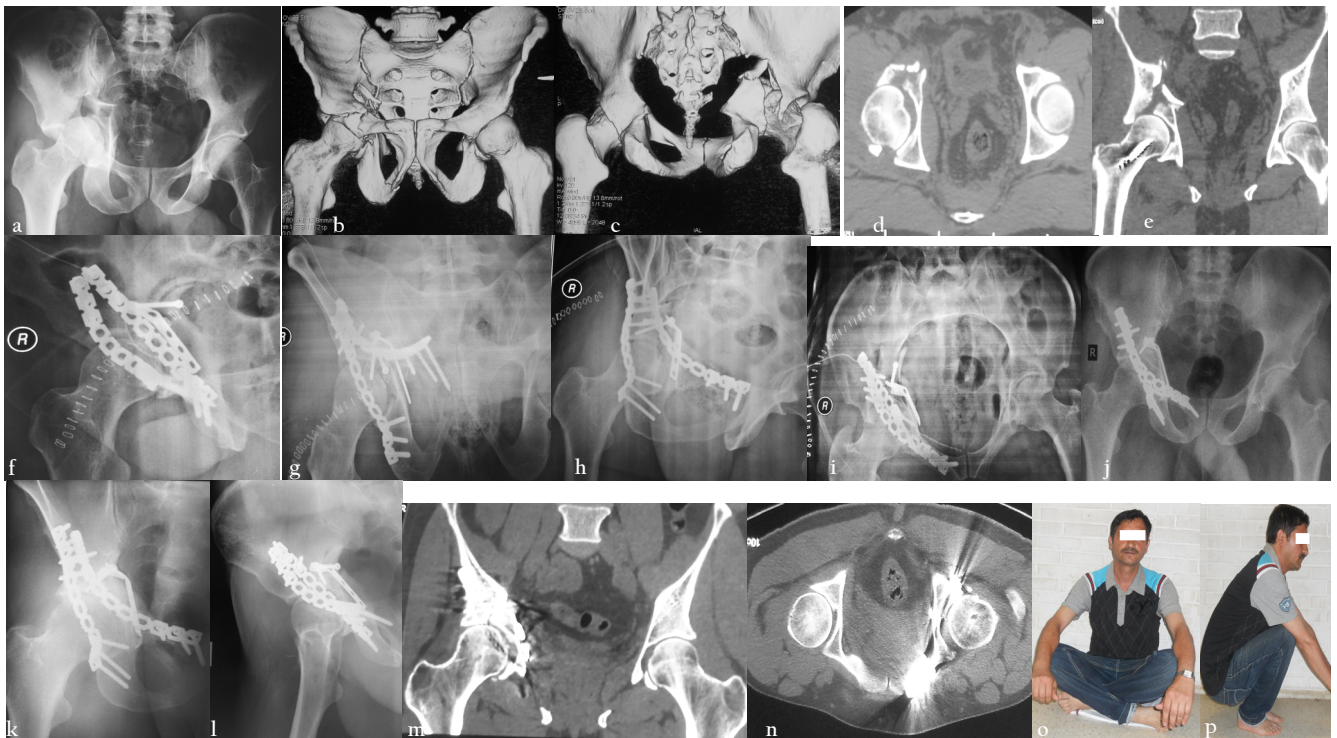Inpatients hospital records, treated for pelvi-acetabular fracture in Dhulikhel Hospital, Kathmandu University Hospital in between June 2007 to June 2014 were evaluated. There were 86 patients with pelvi-acetabular injury managed conservatively or operatively in Dhulikhel Hospital. Data of 21 patients from Dhulikhel Hospital and 12 from other hospitals (patients operated by DS as a visiting surgeon) who had undergone open reduction and internal fixation for various types of acetabular fracture were retrieved for analysis. Patient's demographic data were collected, mode of injury, injury hospital interval, injury surgery interval, associated injuries, surgical approach, total hospital stay and peri and post-operative complications were recorded.

### Surgical technique

Patients were initially stabilized if required, with intravenous fluid or blood transfusion or temporary stabilization of pelvis, supra pubic catheterization or emergency laparotomy for any associated visceral or pelvis injuries. Closed reduction of hip dislocation was achieved in patients with fracture dislocation of hip, stability was tested and reduction was maintained with skeletal traction. All patients were examined with one antero-posterior and two Judet

45° iliac and obturator oblique radiographs of the pelvis and CT scan including 3D reconstruction of pelvis. Patients with unstable fracture dislocation of hip and fracture involving weight bearing area, displaced fracture > 2mm within superior articular surface, fracture involving >25% surface of posterior wall, retained intra articular fragments and lack of secondary congruence or loss of congruence of joint on any view (AP or Judet x-rays) were considered for indication for surgery unless contraindicated by underlying medical conditions.

Kocher-Langenbeck approach on lateral decubitus position was used for posterior wall and posterior column and Ilio-inguinal approach was used for anterior wall or anterior column fracture of acetabulum. For bicolumnar fracture, either simultaneous or staged surgery with interval of 2 to 5 days was performed depending upon surgical time and patient's general condition. Trochanteric osteotomy was not required in all 33 patients. Pre operatively applied upper tibial skeletal traction was used for assisting reduction, joint distraction and better visualization of fracture fragment and at the end of surgery, tractions were removed. Wherever necessary a Steinman pin was used as a joy stick for manipulation of fracture fragment. Depending upon fracture configuration, single or double 3.5 mm reconstruction plates were used for fracture fixation. A lag screw or Spring plate were used for small osteochondral fragments which were not possible to fix with plates. Pre-drilling of posterior wall fragment for lag screws or neutralization plate placement prevented screws entering into the joint. For comminuted quadrilateral plate or comminuted fracture involving sciatic notch, a buttress effect was achieved with bent reconstruction plate or bent and flattened one third tubular plate or contoured reconstruction plate across the quadrilateral plate just below the pelvic brim (Fig 1). For middle and high anterior column fracture, a long screw across anterior column, known as LC II screw, starting from anterior inferior iliac spine heading towards sacro-iliac joint and above sciatic notch was used (Fig 2). Utmost care was paid to avoid intra-articular placement of screws with the help of C arm fluoroscopy and a bony model of pelvis inside operation theatre during surgery that was helpful for deciding screw trajectories. Quality of fracture reduction was assessed with X rays, which included antero-posterior views and two 45° oblique Judet views and CT scans wherever feasible in subsequent follow up. Radiological reduction was evaluated by criteria given by Matta et al which measured residual post-operative displacement on AP and two 45° oblique Judet views where maximum displacement (in mm) of any of normal radiographic lines or innominate bone was measured and categorized into anatomical (0 to 1mm displacement), imperfect (2 to 3mm displacement), poor (>3mm displacement) or surgical secondary congruence.<sup>5</sup> Functional outcome were assessed by Harris Hip Score and Merle d'Aubigné and Postel score.<sup>5,6</sup>

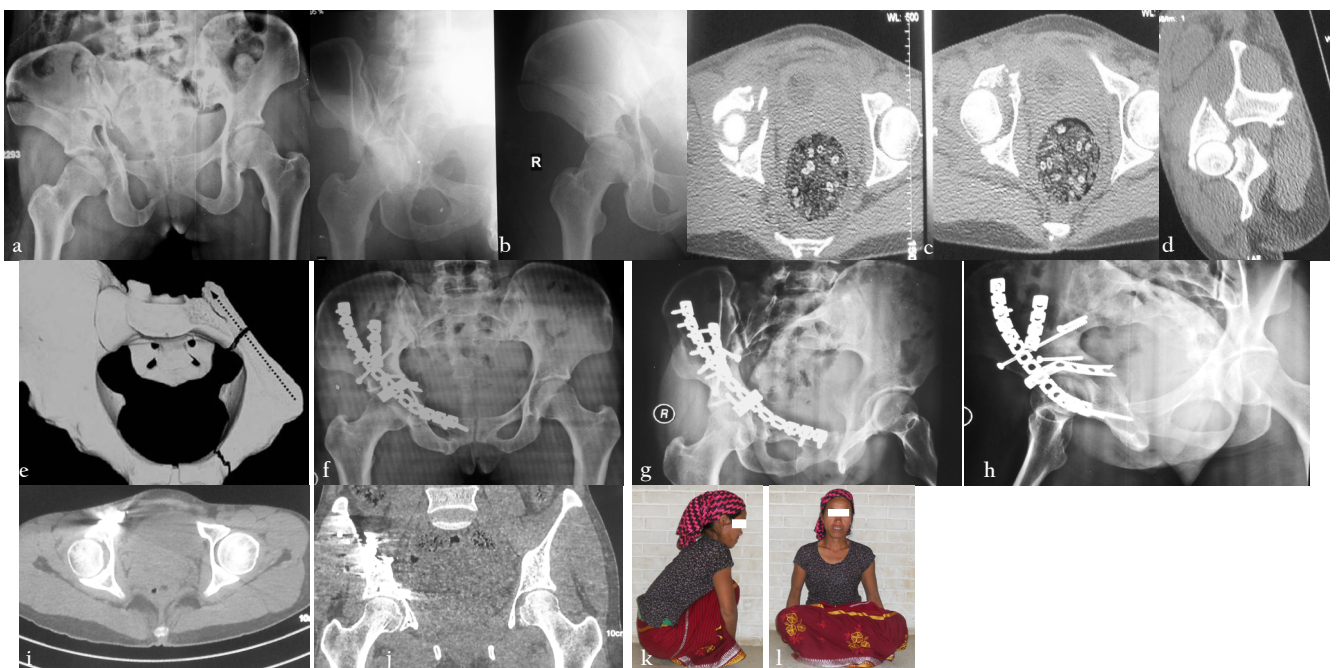


**Figure 1.** Anterior column with posterior hemitransverse fracture with central dislocation and bicoulmnar fixation. a to e: Pre-operative X ray and CT scan , f to i: Post operative X-rays (Note buttress plate for quadrilateral plate fracture), j to m: follow up X-rays and CT at 24 months, o to p: Clinical outcome at 24 months

All patients received pre-operative antibiotic prophylaxis according to hospital protocol. Post operatively indomethacin was used as a prophylaxis of Heterotopic ossification. Similarly, mechanical prophylaxis with graduated stockings in bilateral lower limbs and chemical prophylaxis in the form of subcutaneous low molecular weight heparin (enoxaparin) was routinely used for deep vein thrombosis (DVT) prevention unless contra indicated. Post operatively, range of movement exercise was started

on second post-operative day after removal of drain and allowed for non weight bearing mobilization. Weight bearing was allowed once radiographic sign of fracture healing was evident.

Patients were subsequently followed up for radiological and functional assessments in 6 weeks, 12 weeks, 3 months, 6 months, one year and yearly or whenever necessary. Radiological outcomes were assessed according to Matta's radiological outcome criteria.<sup>5</sup>



**Figure 2.** Bicolmnar fracture with high/middle anterior column with pregnancy fixed with LCII screw. a to d: Pre operative X-rays and CT scan, e: Trajectory of screw for LC II screw, f to i: Follow up X-rays and CT scan and clinical picture at 24 months

Table 1. Demographics data of 33 cases of acetabular fracture

S. No.	Age	Sex	Mode of injury	Injury Hospital interval (Days)	Injury Surgery Interval (Days)	Hospital stay (Days)	Types of Acetabular Injury (Letournel and Judet)	Site	Dislocation	Associated injuries
1	25	F	RTA: Bike	1	10	18	Anterior column	Right		
2	54	F	Fall from cliff	2	6	25	Anterior column	Left		Multiple Ribs fracture, blunt trauma abdomen
3	33	M	RTA: Bus	1	10	35	Bicolumnar	Right		Cut injury of neck and face
4	45	M	RTA: Bike	15	18	8	Anterior column	Right		Right superior pubic rami fracture
5	35	M	Burried by mud	1	7	26	Bicolumnar	Right		Right femur fracture
6	40	M	Burried by mud	1	8	14	Posterior column	Right		
7	70	M	Fall from cliff	2	5	20	Bicolumnar	Right	Central	Rt distal radius fracture
8	55	M	RTA: Bike	4	10	16	Posterior column with posterior wall	Right	Posterior	
9	22	M	RTA : Bus	1	2	16	Bicolumnar	Left		
10	35	M	Fall from cliff	1	26	37	Tranverse	Left		Left shaft femur and ipsilateral neck femur fracture
11	45	M	RTA: Bike	7	6	33	Anterior column with posterior hemitransverse	Right	Central	
12	42	F	Fall from cliff	24	27	9	Bicolumnar	Right		Right clavicle fracture
13	65	M	RTA: Car	1	5	15	Posterior wall	Right	Posterior	
14	60	M	RTA: Bike	2	12	14	Anterior column	Right		
15	32	M	RTA : Car	1	3	30	Bicolumnar	Right		
16	28	F	RTA : Pedestrian	1	13	46	Posterior wall	Left	Posterior	Head injury
17	21	M	RTA: Bike	1	2	17	Tranverse with posterior wall	Right		
18	42	M	RTA: Bike	1	6	22	Anterior column	Left		
19	32	M	RTA : Car	4	5	16	Bicolumnar	Right		
20	26	M	RTA : Bike	1	6	14	Anterior column	Right		
21	22	M	RTA: Bike	1	2	35	Posterior wall and column	Right	Central	Right shaft tibia and femur fracture
22	35	M	RTA: Bike	3	5	22	Bicolumnar	Right		
23	65	M	RTA	1	42	16	Bicolumnar	Right		
24	34	M	RTA: Bike	1	23	46	Posterior column with posterior wall	Left		Right lower limb mangled extremity
25	40	M	Fall injury	2	10	20	Posterior wall	Left	Posterior	
26	43	M	RTA : Bus	1	4	15	Anterior column	Left		
27	28	M	RTA: Car	1	16	29	Bicolumnar	Right		Right femur supracondylar fracture
28	41	F	Fall from cliff	2	12	15	Posterior column with posterior wall	Right	Posterior	Right distal radius, femoral head fracture
29	36	F	RTA: Bus	1	15	40	Bicolumnar	Left		Bladder injury
30	36	M	Fall injury	14	18	20	Bicolumnar	Left		
31	60	F	Burried by mud	1	8	13	Posterior column with posterior wall	Right	Posterior	Femoral head fracture
32	42	F	Fall injury	1	11	17	Tranverse	Right		
33	25	F	Fall from cliff	3	13	22	Tranverse	Left		Right sacro iliac joint disruption

RTA: Road Traffic Accident



Fixation	Radiological reduction (Matta's Criteria)	Follow up period (Days)	Harris hips score	Merle d'Aubinge and Postel score	Radiological outcome (Matta's Criteria)	Complications
Anterior column	Anatomical	48	100	18	Excellent	
Anterior column	Anatomical	48	96	16	Good	
Bicolumnar	Imperfect	39	100	18	Excellent	
Anterior column	Anatomical	36	100	18	Excellent	
Bicolumnar (Staged)	Poor	36	72	13	Moderate	Osteo-arthritis of hip
Posterior column	Anatomical	36	95	17	Good	
Bicolumnar (Staged)	Secondary congruence	36	68	13	Moderate	Osteo-arthritis of hip
Posterior wall and column	Anatomical	36	90	14	Good	Heterotopic ossification
Bicolumnar (Staged)	Anatomical	32	94	15	Good	
Bicolumnar (Staged)	Anatomical	26	97	17	Excellent	
Bicolumnar (Staged)	Anatomical	24	100	18		
Anterior wall, column and LC II screw fixation	Anatomical	24	100	18	Excellent	
Posterior wall and column	Anatomical	24	90	14	Moderate	Heterotopic ossification
Anterior column	Anatomical	24	100	18	Excellent	
Bicolumnar (Staged)	Anatomical	24	100	17	Excellent	
Posterior wall and column	Imperfect	22	94	16	Good	
Bicolumnar (Staged)	Imperfect	18	100	18	Good	Heterotopic ossification towards pelvic brim
Anterior column	Poor	18	70	12	Moderate	
Bicolumnar (Staged)	Anatomical	18	98	17	Good	
Anterior column	Imperfect	16	94	17	Moderate	
Posterior wall and column	Anatomical	14	93	15	Good	
Bicolumnar (Staged)	Imperfect	12	96	18	Good	
Bicolumnar	Imperfect	12	100	17	Good	
Posterior wall and column	Imperfect	12	88	15	Good	
Posterior wall and column	Anatomical	12	100	18	Excellent	
Anterior wall and column	Imperfect	12	90	15	Moderate	
Bicolumnar (Staged)	Secondary congruence	9	86	12	Fair	
Posterior wall and column	Anatomical	8	89	15	Excellent	
Bicolumnar (Staged)	Imperfect	8	90	16	Excellent	Femoral artery injury
Bicolumnar (Staged)	Imperfect	6	86	14	Fair	
Posterior wall and column	Anatomical	6	90	15	Excellent	
Bicolumnar (Staged)	Anatomical	6	89	15	Excellent	
Anterior wall and column and percutaneous sacroiliac joint	Imperfect	6	89	15	Excellent	

**RESULTS**

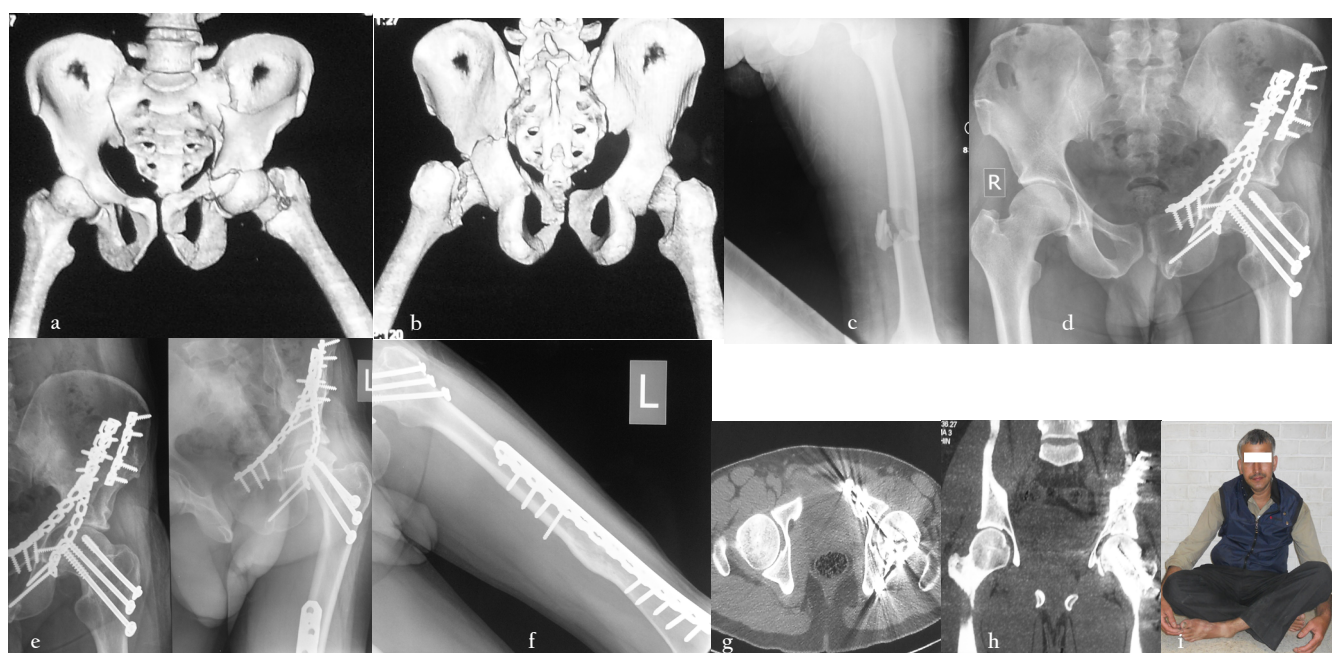
Thirty three patients (Male: 24 Female: 9) with average age 39 years (range: 21 to 65 years) were operated for acetabular fracture. Twenty one patients (63%) had acetabular injury related with motor vehicle accidents and nine (24%) of them had motorbike accidents (Table 1). Fall related injury was associated in eight patients. Patients were brought to hospital or near-by health care center within 72 hours of injury but four patients who came late (7 to 36 days after injury) were primarily managed in other centers with traction and referred to Dhulikhel Hospital for further treatment. Average injury-surgery interval was 21 days with range of 2 days to 42 days. Fourteen patients (42%) were operated with in one week of injury. A patient with bicolumnar fracture who had delayed surgery on 42 days was initially managed with skeletal traction but developed severe pain on attempt of mobilization and hence referred to Dhulikhel Hospital for further treatment. He had inadequate reduction of both column for which he underwent bicolumnar fracture fixation. Average hospital stay was 22 days (range: 8 to 46 days)

Bicolumnar fractures were found in 15 patients. Other types of acetabular fracture are shown in table 2. Thirteen patients who required both posterior and anterior surgical approach were planned for stage surgery and two patients had undergone both surgeries on the same setting including intra medullary interlocking nail of femur in one patient. Nine patients had hip dislocation; six were posterior and three were central fracture dislocation. Fifteen patients had concomitant other injuries. Three patients had polytrauma. A patient with multiple rib fracture and blunt trauma abdomen along with anterior wall and column fracture presented with shock and needed laparotomy and other patient required bladder repair. One

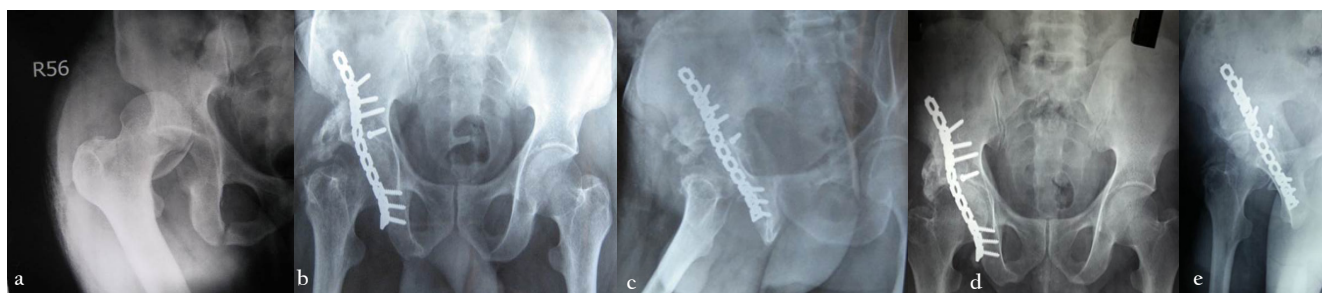patient had ipsilateral neck and shaft femur fracture (Fig 3) and another had ipsilateral shaft femur and tibia fracture. A patient who had contralateral mangled lower extremity underwent above knee amputation. Two patients who had posterior dislocation also had femoral head fracture. Qualities of post-operative radiological reduction was based upon Matta’s radiological criteria are shown in table 2. One patient had iatrogenic femoral artery injury during anterior ilio-inguinal approach that was repaired with help of vascular surgeon and she had eventless post-operative recovery.

Except one patient with head injury, all patients received deep vein thrombosis prophylaxis with low molecular weight heparin along with graduated stockings. No patient developed deep vein thrombosis. Two patients had superficial infection of anterior wound which was controlled with daily dressing and intravenous antibiotics. Similarly, two patients had foot drop after surgery but both completely recovered in subsequent follow up. Follow up period was from 6 months to 48 months. Fifteen patients (45%) could be followed up for more than two years. According to Harris Hip score, three patients had poor/ fair outcome whereas according to Merle d’Aubigné and Postel score seven patients had poor/ fair outcome at final follow up. Similarly, according to Matta’s radiological outcome criteria, two patients had fair result. Other functional and radiological outcomes are tabulated into table 2.

Heterotopic ossification of Brooker class III was found in two patients with posterior wall and column fracture with posterior dislocation of hip I but gradually size of heterotopic mass decreased (Brooker class II) allowing good range of movement of hip (Fig 4). A patient who had communicated quadrilateral plate fracture developed heterotopic ossification towards pelvic brim which did not



**Figure 3.** Transverse fracture with ipsilateral neck and shaft femur fracture. a to c: Pre operative X-rays and CT Scan, d to i: Follow up X-rays and CT scan and clinical picture at 26 months



**Figure 4.** Posterior dislocation with posterior wall fracture. a: Pre operative X ray, b,c: Hypertrophic ossification Brooker Class III at 12 months, d,e: Hypertrophic ossification Brooker Class II at 48 months

**Table 2.** Fracture type, surgery performed, functional and radiological outcomes

Fracture Type		
<b>Elementary</b>		
Anterior wall		1
Anterior column		6
Posterior wall		3
Posterior column		1
Transverse		3
<b>Associated</b>		
Posterior column with posterior wall		5
Transverse with posterior wall		1
Anterior column with posterior hemi transverse		1
Bicolumnar		12
<b>Reduction</b>		
Anatomical		18
Imperfect		11
Poor		2
Secondary congruence		2
<b>Surgery performed</b>		
Anterior column fixation		6
Anterior wall and column		3
Posterior column fixation		1
Posterior wall and column fixation		8
Bicolumnar		15
<b>Outcome</b>	Harris hips score	Merle d'Aubinge score
Excellent	24	9
Good	6	17
Fair	2	5
Poor	1	2
<b>Radiographic grade (Matta's criteria)</b>		
Excellent		14
Moderate		6
Good		11
Fair		2

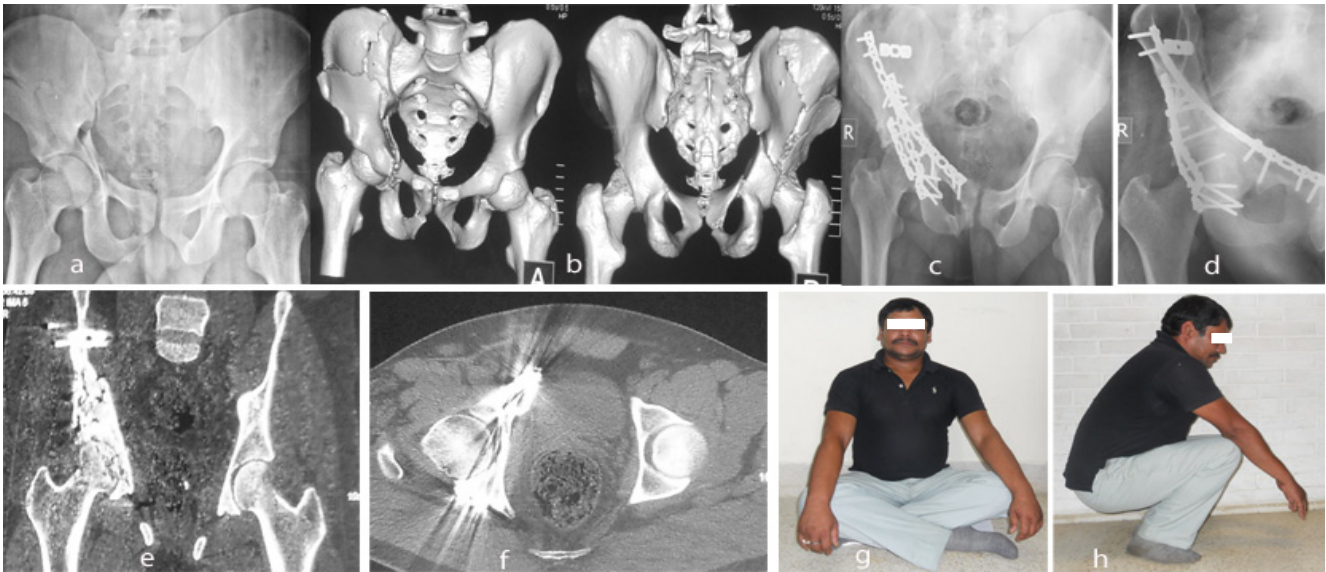
affect in functional outcome. Two patients had radiological evidence of osteoarthritis in hip with reduced joint space and peripheral osteophytes. There were no hardware related complications.

### DISCUSSION

Acetabular fracture is intra-articular fracture. Anatomical reduction and stable fixation are two important variables which affect final outcome. Till 1960, acetabular fracture were treated conservatively but with development of columnar concept as described by Judet and Letournel and availability of better imaging modalities, surgical treatment opinion are increasingly followed and have shown better results.<sup>7-9</sup> Various surgical approaches and techniques have been described for better anatomical reduction and stable fixation of acetabular column. But open reduction and internal fixation of acetabular fracture is technically challenging and very few selective centers in Nepal offer such treatment options to the patients. Only one literature available from Nepal reported 31 patients with operative management among 41 patients with acetabular injury.<sup>3</sup> Similarly study from India by Gupta RK et.al. revealed that lack of appropriate centers and trained personnel to deal with pelvi-acetabular surgery was the reason for patients presenting late with an average of 12.33 days and are associated with poor outcome.<sup>2</sup> The present study revealed average of 21 days of injury surgery interval and those patients who presented after two weeks of injury were initially managed in other hospitals where facilities for operative treatments for acetabular fracture were not available.

Epidemiological analysis of acetabular fracture revealed that incidence of acetabular fracture is increasing in developing countries contrary to the United States and Western Europe where it is stable and it affects young age group.<sup>1</sup> In the present study, 17 patients were at or below 40 years of age and 24 patients were male. Similar trends were also observed by Gupta RK et. al. and Magu NK et. al. in India and Khan SH et. al. in Pakistan which indicates that young male were more vulnerable for acetabular injury.<sup>2,10,11</sup> Since acetabular fracture are more commonly seen in young age group, it is not unusual to sustain injury





**Figure 5.** Bicolunar fracture with bicolunar fixation. a,b: Pre operative Xray and CT scan, c to h: Follow up X-rays and CT scan and clinical picture at 48 months (Note irregularity of acetabular cartilage)

in pregnant lady. We had 42 years lady with 18 weeks of pregnancy who had bicolunar fracture with fracture right clavicle. Though there are reports and case series of successful management of pelvi-acetabular fracture with normal delivery, this lady had already undergone medical termination of pregnancy before she presented to us.<sup>12,13</sup> In this particular case, we had used LC II screw to fix high anterior column fracture extending to posterior column along with anterior column and wall fixation.

The available three major approach for acetabular fracture are anterior ilio-inguinal approach, posterior Kocher-Langenbeck approach and extended ilio-femoral approach and some modification or special approach for specific configuration of fracture. Certain modification of approach such as Modified Stoppa approach is useful for better visualization of pelvic brim and quadrilateral plate. Each surgical approach has its own advantages and disadvantages and choice depends upon surgeon familiarity and fracture configuration. In the current series, we used Kocher-Langenbeck for posterior and ilio-inguinal approach for anterior procedures. We attempted both anterior and posterior fixation simultaneously in initial few cases with average surgical time was 300 minutes with blood loss of 2000 ml. But later on, staged surgery was done with interval of 2 to 5 days. It has advantage of less surgical stress to the patients and also reduces chances of post-operative infection.

Quality of reduction in acetabular fracture is independent variable in terms of final outcome. Incongruous reduction reduces contact area between femoral head and acetabulum leading to increase in force per unit area to the articular cartilage and promotes post traumatic osteoarthritis. Matta et. al. states that though capability of acetabulum allows limited change in distribution and perhaps reshape itself, every attempt should be made to achieve residual displacement no more than 1 mm.<sup>5</sup> In the current study, a 33 year old male patient with bicolunar

fracture with severely damaged acetabular cartilage and imperfect radiological reduction had unexpectedly excellent radiological and functional outcome(Harris hip score 100 and Modified Merle d’Aubigné scale 18) and till last follow up at 39 months post-operative (Fig 5) where as another elderly patient who had secondary congruence developed hip pain and osteoarthritic changes in first eight month of follow up. Besides quality of reduction, comminuted posterior wall fracture and femoral head injury play as important factors in clinical outcomes. The functional outcomes of various studies of acetabular

**Table 3.** Comparison of outcome with other studies

	No. of cases	Excellent/good (%)
Current study	33	78
Gupta RK et al <sup>2</sup>	63	74
Matta et al <sup>5</sup>	255	76
Kumar et al <sup>14</sup>	73	75

fractures managed with open reduction and internal fixation are compared in table 3.

There are conflicting reports of incidence of deep vein thrombosis (DVT) and pulmonary embolism in Asian population. In the absence of long term prospective studies, routine use of chemical prophylaxis for DVT is not recommended in routine orthopaedic procedures . But most of these recommendation are based upon study of hip fracture and arthroplasty. Sen R et. al. reported 16 cases of venous thromboembolism and 10 pulmonary embolism in 56 patients who had undergone pelvi- acetabular surgery without chemical prophylaxis and concluded that posterior injuries, patient operated on lateral decubitus position and Kocher Lagenbeck approach are risk factors for venous thromboembolism.<sup>15</sup> In the current study, all patients received mechanical prophylaxis and chemical prophylaxis unless contraindicated such as head injury



and none of them developed clinical features of DVT and pulmonary embolism. Depending upon condition of other associated co morbidities, patients in the current study were mobilized out of bed as early as possible once surgical drains were removed after 48 hours of injury.

Heterotopic ossification is another complication with variable incidence (over all 25.6%) depending upon surgical approach. Extended ilio-inguinal (35 to 57%) and tri-radiate approach (86%) have higher incidence as compare to low incidence in ilio-inguinal (4.8%) approach and moderate incidence in KocherLangenbeck approach.<sup>16</sup> Various factors have been reported to be associated with higher incidence of heterotopic ossification such as head or chest or abdominal injury, associated hip and femur fracture, T- type of acetabular injury and patient with mechanical ventilation.<sup>17</sup> In the current study, two patient developed Heterotopic ossification of Brooker class III and IV which was later resorbed to Brooker class II in subsequent follow up. Both the patients had posterior injury and was associated with posterior dislocation of hip and were operated with KocherLangenbeck approach in lateral decubitus position. Both of these patient had fair outcome according to Merle d'Aubigné and Postel score. Another young patient who had comminuted quadrilateral plate with buttressing with bent tubular plate developed Heterotopic ossification towards pelvic brim and did not affect the outcome. Indomethacin is routinely prescribed as a prophylaxis of Heterotopic ossification in the current study. Indomethacin is found to be equally effective as local radiation therapy to prevent Heterotopic ossification after acetabular surgery by Burd TA et. al. in prospective randomized trial of 166 patients.<sup>18</sup>

Iatrogenic nerve injury such as sciatic nerve, femoral nerve and lateral cutaneous nerve of thigh are possible complication during acetabular surgery. We found two cases

of post-operative foot drop; one with KocherLangenbeck and another with ilio-inguinal approach. Both of them recovered completely in subsequent follow up. Careful positioning of retractors during surgery and avoiding tension to nerve by keeping hip and knee in suitable position to avoid stretching of nerve can minimize risk of nerve injury. Incidence of femoral vessel injury is reported in 0.8 to 2% of ilio-inguinal approach.<sup>16</sup> The present series had a case of iatrogenic femoral artery injury for which immediate bleeding was stopped by compression and subsequently repaired by vascular surgeon. Post operative mobilization was delayed for her but had good final outcome and had no vascular complications. Specially for ilio-inguinal approach, help of general surgeon and vascular surgeon may be required for dissection and repair of inguinal and femoral canal.

Though the current study is retrospective in nature with limited number of patients, the current series of acetabular fracture managed with operative management along with analysis of functional and radiological outcomes has been reported first time in Nepal.

## CONCLUSION

Acetabular fracture, which is mainly due to high velocity injury involving young adults, can be effectively managed with open reduction and internal fixation and have predictable and comparable functional and radiographic outcomes. Team of trained orthopedic and general surgeon and support of anesthetist are necessary to deal with any possible complications and associated other injuries. Upgrading the existing facilities and training of orthopedic surgeon for acetabular fracture management is important to shorten injury-surgery interval because many patients are operated late due to lack of such centers and surgeons.

## REFERENCES

1. Mauffrey C, Hao J, Cuellar DO, Herbert B, Chen X, Liu B, Zhang Y, Smith W. The epidemiology and injury patterns of acetabular fractures: are the USA and China comparable? *Clin Orthop Relat Res.* 2014 Nov;472(11):3332-7.
2. Gupta RK, Singh H, Dev B, Kansay R, Gupta P, Garg S. Results of operative treatment of acetabular fractures from the Third World—how local factors affect the outcome. *International Orthopaedics.* 2009 33:347–352.
3. Sharma UK, Basnyat A, Rijal K, Shrestha BK, Banskota B, Banskota AK. CT Evaluation of Pelvic and Hip Fractures. *J Nepal Med Assoc.* 2013 Oct-Dec;52(192):586-90.
4. Rohilla R, Arora S. conservatively treated acetabular fractures: A retrospective analysis. *Indian Journal of Orthopaedics.* 2012; 46(1): 36-45
5. Matta JM. Fractures of the acetabulum: accuracy of reduction and clinical results in patients managed operatively within three weeks after the injury. *J Bone Joint Surg Am* 1996;78(11):1632–45.
6. Harris WH. Traumatic arthritis of the hip after dislocation and acetabular fractures: treatment by mold arthroplasty. *J Bone Joint Surg Am* 1969 Jun; 51 (4): 737-55
7. Judet R, Judet J, Lanzetta A, Letournel E. Fractures of the acetabulum: classification and guiding rules for open reduction. *Arch Orthop.* 1968; 81(3):119-58.
8. Letournel E. Fractures of the acetabulum: a study of a series of 75 cases. *Clin Orthop Relat Res.* 1994;(305):5-9.
9. Saterbak AM, Marsh JL, Turbett T, Brandser E. Acetabular fractures classification of Letournel and Judet: a systematic approach. *Iowa Orthop J.* 1995; 15:184-96.
10. Magu NK, Rohilla R, Arora S. Conservatively treated acetabular fractures: A retrospective analysis. *Indian Journal Of Orthopaedics* 2012 46: 1: 36-45,
11. Khan SH, Ara I, Raza S, Sipra S. Functional outcome of surgery in patients with acetabular fractures. *J Ayub Med Coll Abbottabad* 2013;25:1-2.
12. Kloen P, Flik K, Helfet DL. Operative treatment of acetabular fracture during pregnancy: a case report. *Archives of Orthopaedic and Trauma Surgery* 2005 April;125:3:209-12.
13. Yosipovitch Z, Goldberg I, Ventura E, Neri A. Open reduction of acetabular fracture in pregnancy. A case report. *Clin Orthop Relat Res.* 1992 Sep;(282):229-32.
14. Kumar A, Shah NA, Kershaw SA, Clayson AD. Operative management of acetabular fractures. A review of 73 fractures. *Injury* 2005;36: 605-12
15. Sen RK, Kumar A, Tripathy SK, Aggarwal S, Khandelwal N. Risk factors of venous thromboembolism in Indian patients with pelvic-acetabular trauma. *Journal of Orthopaedic Surgery* 2011;19(1):18-24
16. McMaster J, Powell J. Acetabular fracture. *Current Orthopaedics.* 2005 April;19: 140–154
17. Firoozabadi R, O'Mara TJ, Swenson A, Agel J, Beck JD, Routt M. Fractures of the Acetabulum Risk Factors for the Development of Heterotopic Ossification After Acetabular Fracture Fixation. *Clinical Orthopaedics and Related Research* 2014;472
18. Burd TA, Lowry K, Anlen JO. Indomethacin Compared with Localized Irradiation for the Prevention of Heterotopic Ossification Following Surgical Treatment of Acetabular Fractures. *J Bone Joint Surg Am* Dec;2001 83-A:12.