

A Study on Variations of Nutrient Foramen of Humerus with its Clinical Implications

Mansur DI, Manandhar P, Haque MK, Mehta DK, Duwal S, Timalisina B

Department of Anatomy
Kathmandu University School of Medical Sciences
Dhulikhel, Kavre, Nepal.

Corresponding Author

Dil Islam Mansur
Department of Anatomy
Kathmandu University School of Medical Sciences
Dhulikhel, Nepal
E-mail: drdilislam@gmail.com

Citation

Mansur DI, Manadhar P, Haque MK, Mehta DK, Duwal S, Timalisina B. A Study on Variations of Nutrient Foramen of Humerus with its Clinical Implications. *Kathmandu Univ Med J* 2016;53(1):78-83.

ABSTRACT

Background

Nutrient foramen is an opening into shaft of humerus which gives passage to the blood vessels of medullary cavity. The knowledge of nutrient foramen is important in surgical procedures like bone grafting and more recently in microsurgical vascularized bone transplantation.

Objective

To determine the number, location and direction of nutrient foramen and whether the nutrient foramens obey the rule of ossification, that is directed away from the growing end of the bone or not.

Method

The present study consisted of 253 (108 right and 145 left) dried humeri excluding any fracture or pathological abnormalities during the period of 15th December 2014 - 14th February 2015. Number and direction of nutrient foramen was observed in each humerus. Location of nutrient foramen in relation with surfaces and zones of humeri was determined.

Result

It has been observed that 60.87% of the humeri had a single nutrient foramen, 28.85% double foramen, 6.32% triple foramen and 1.98% of humeri had four nutrient foramina where as 1.98% humeri did not have any nutrient foramina. It was concluded that the majority (88.86%) of the nutrient foramina were present on the antero-medial surface, 6.52% on the anterolateral surface and 4.62% on the posterior surface of the shaft of humeri. It was also concluded that most (94.84%) of the foramina present in the zone II followed by zone III (4.62%) then by zone I (0.54%). All foramina were directed toward the lower end of humeri.

Conclusion

By knowing the number and location of the nutrient foramina in humerus would be useful in preventing intra-operative injury of nutrient artery during orthopedic, plastic and reconstructive surgery and will also be relevant in medico legal practice.

KEY WORDS

Clinical implications, foraminal index, humerus, nutrient foramen

INTRODUCTION

Nutrient foramen is an opening into the shaft of humerus bone. It leads to oblique nutrient canal passing through cortex and ultimately opens into the medullary cavity. The nutrient artery enters into the medullary cavity through nutrient foramen and the canal which is a rich source of blood supply to the medullary cavity and inner two-third of cortex of the humerus.¹

The nutrient blood supply is crucial for any long bones and it should be preserved in order to promote the fracture healing.² Moreover, the presence of preserved nutrient blood supply is essential for the survival of the osteocytes in cases of tumor resection, trauma, and congenital pseudoarthrosis.³

It is usually single in number and located on the antero-medial surface of the humerus a little below its midpoint close to the medial border. It is usually directed toward the lower end of humeri.⁴ The number and location of foramina remains are non-constant feature in long bones.⁵ Henderson RG also reported that their location in mammalian bones are variable and may alter during the growth.⁶ Knowledge of the number and location of nutrient foramina is useful in certain surgical procedures.⁷

Though studies on the vascularization of long bones of various populations were conducted analyzing the nutrient foramina morphometry and the vascular anatomy in reconstructive surgeries,⁸⁻¹¹ the nutrient foramina of humeri were rarely studied among Nepalese population.

Therefore, the aim of this study was to study the precise anatomy of nutrient foramina in adult human humeri of Nepalese subjects. This knowledge was of tremendous significance to orthopedic surgeons performing procedures involving bone grafts, fracture repair, joint replacement and vascularized bone microsurgery.

METHODS

The present study consisted of 253 (108 right and 145 left) dried and cleaned humeri which were available in the Department of Anatomy, KUSMS and others medical colleges in Kathmandu valley during the period of 15th December 2014 and 14th February 2015. All the humeri that were taken for the study were normal and with any fracture or pathological abnormalities were excluded from the study. Prior to the study, ethical permission was taken from IRC – KUSMS (100/14). The side determination was done for the entire humeri. In each humerus, nutrient foramen was observed and studied carefully under proper illumination.

The nutrient foramina were distinguished by the presence of a well-marked groove leading to the foramen, and by a well marked often slightly raised edge of the foramen at the commencement of the canal. Location of nutrient

foramen in relation with surface and zone were observed and recorded. Direction of nutrient foramen in relation with growing end of humerus was noted. The position of nutrient foramen was determined by calculating a Foraminal Index (FI) using the Hughes formula:¹² $FI = (DNF/TL) \times 100$ where DNF stands for distance from the proximal end of the bone to the nutrient foramina and TL stands for total length of the bone in millimeter. Determination of total length of the individual humerus was taken as the distance between the superior aspect of the head and the most distal aspect of the trochlea of each humeri in millimeter.

The position of foramina was divided into three types according to FI as follows:

Zone I: FI up to 33.33%, the foramen was in proximal third of the bone.

Zone II: FI from 33.33% to 66.66%, the foramen was in the middle third of bone.

Zone III: FI above 66.66%, the foramen was in the distal third of bone.

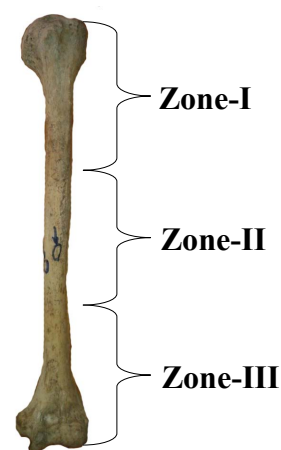


Figure 1. A photograph of humerus showing different zones.

All the numerical data were subjected to statistical analysis using SPSS 19.0. The observations and measurements were presented in descriptive statistics.

RESULTS

The following observations were found to conclude the results of the study.

Number of foramina

As shown in Table 1, the single nutrient foramen was present in 60.19% (65) of right humeri (Fig. 2D) and 61.38% (89) of left humeri, double nutrient foramina in 31.48% (34) of right humeri and 26.90% (39) of left humeri (Fig. 2A,B), triple nutrient foramina in 6.48% (7) of right humeri and 6.20% (9) of left humeri and quadruple nutrient foramina were found in 3.45% of left humeri whereas no any quadruple foramina were found in right humeri. The nutrient foramina were found to be absent in 1.85% (2) of right humeri and 2.07% (3) of left humeri.

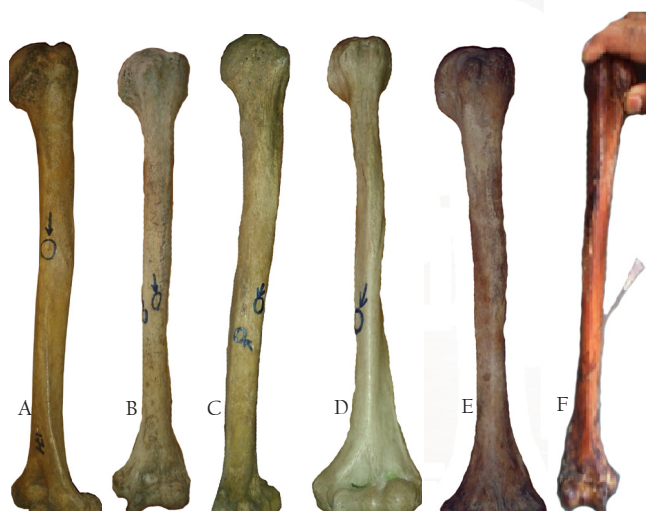


Figure 1. A photograph of humerus showing number, location and direction of NF

Table 1. Showing distribution of nutrient foramen of humeri.

No. of nutrient foramen	Right (n=108)		Left (n=145)		Total (n=253)	
	No. of humerus	%	No. of humerus	%	No. of humerus	%
0	2	1.85	3	2.07	5	1.98
1	65	60.19	89	61.38	154	60.87
2	34	31.48	39	26.90	73	28.85
3	7	6.48	9	6.20	16	6.32
4	-	-	5	3.45	5	1.98
Total	108	100	145	100	253	100

It has been concluded that 60.87% of the humeri had a single nutrient foramen. The double foramen was observed in 28.85% of the humeri. Triple foramen was found in 6.32% of the humeri and 1.98% of humeri had four nutrient foramina where as 1.98% humeri did not have any foramina.

Location of foramina

It has been observed that a total of 368 numbers of nutrient foramina were found to be present in all studied humeri. In relation to surfaces, it was found that antero-medial surface (AMS) had 85.71% (132) of nutrient foramina in right humeri (Fig 2A) and 91.12% (195) of nutrient foramina in left humeri, posterior surface (PS) had 7.79% (12) of nutrient foramina in right humeri and 5.61% (12) of nutrient foramina in left humeri and antero-lateral surface (ALS) had 6.49% (10) of nutrient foramina in the right humeri and 3.27% (17) of nutrient foramina in the left humeri were found on anterolateral surface of the shaft of humeri as shown in Table 2.

Therefore, it was concluded that the majority (88.86%) of the nutrient foramina were found to be present on the antero-medial surface of the shaft of humeri, followed by 6.52% of the nutrient foramina were concentrated on the

anterolateral surface and 4.62% of the nutrient foramina were located on the posterior surface of the shaft of humeri.

Table 2. Showing distribution of nutrient foramen in respect to surface of humeri.

Surfaces	Right (n=154 NF)		Left (n= 214 NF)		Total	
	Number	%	Number	%	Number	%
AMS	132	85.71	195	91.12	327	88.86
PS	12	7.79	12	5.61	24	6.52
ALS	10	6.49	7	3.27	17	4.62
Total	154	100	214	100	368	100

As shown in Table 3, the incidence of nutrient foramina present in Zone I of the shaft of humeri was found to be 1.30% (2) in right humeri whereas the nutrient foramina was found to be absent in Zone I of left humeri. It was observed that 147 nutrient foramina (95.45%) were present in Zone II of right humeri and 203 nutrient foramina (94.86%) in Zone II of left humeri (Fig 2B). It was also observed that 5 nutrient foramina (3.25%) were present in Zone III of right humeri and 11 nutrient foramina (5.14%) in Zone III of left humeri in relation to the zones.

Table 3. Showing distribution of nutrient foramen in respect to zone of humeri.

Zones	Right (n=154 NF)		Left (n= 214 NF)		Total	
	Number	%	Number	%	Number	%
Zone I	2	1.30	-	-	2	0.54
Zone II	147	95.45	203	94.86	349	94.84
Zone III	5	3.25	11	5.14	17	4.62
Total	154	100	214	100	368	100

Overall incidence of presence of nutrient foramina in the middle one-third or Zone II of the shaft of humeri were 94.84%, followed by the middle one-third or Zone II (4.62%) and by upper one-third or zone I (0.54%).

Direction of foramina

The direction of nutrient foramina was not showing any deviation from normal anatomical feature even in single case throughout the study. All the foramina were directed downward or toward the lower end of humeri as shown in Fig 2(E).

As shown in Table 4, the mean total length of humeri was found to be 270.56 mm in right and 269.97 mm in left humeri; and mean distance from proximal end of humerus to the nutrient foramen was found to be 149.17 mm for right and 150.11 mm for left humeri and the foraminal index was found to be 54.87% on right humeri and 55.44% on left humeri. Therefore, an average the total mean length of humeri was found to be 270.22 ± 20.54 mm; and mean distance from proximal end of humerus to the nutrient

foramen was found to be 149.71 mm and the mean foraminal index was found to be 55.20%.

Table 4. Showing mean values of statistical measurements of humeri.

Parameters	Right (n=108)	Left (n=145)	Total
Mean total length	270.56 mm	269.97 mm	270.22 mm
Distance from proximal end to NF	149.17 mm	150.11 mm	149.71 mm
Foraminal Index	54.87%	55.44%	55.20%

DISCUSSION

The knowledge of variations of nutrient foramina is significantly important for orthopaedic surgeons undertaking an open reduction of a fracture to avoid injuring the nutrient artery and thus lessening the chances of delayed or non-union of the fracture.¹³ Intact arterial supply is very important for healing of a fractured bone.¹⁴ It is well known fact that one of the causes of delayed union or non-union of fracture is lack of arterial supply.¹⁵

Number of foramina

The present study showed that single nutrient foramen was present in 60.87% of humeri. A similar finding (60%) was reported by Shaheen in Saudi Arabia.¹⁶ Almost similar trend also reported by Mysorekar et al. (58%) in Indian population and Joshi et al. (63%) among Gujarati population.^{7,13} Many studies reported high percentage of incidence of single foramina. A study done by Carroll et al. in 71 humeri collected from University of Western Ontario, London and observed that 67.61% of humeri had a single nutrient foramen.¹⁷ The incidence was found to be higher in a study conducted by Forriol et al. in 36 humeri collected from Medical School of Alcalá de Henares University who reported the incidence of 75% of humeri with single nutrient foramen as compared to the present study.¹⁸ Similarly, a study conducted by Peirera et al. reported the incidence of 88.5% in Southern Brazil and Bhatnagar et al. reported the incidence of 90% of humeri with single nutrient foramen in Uttar Pradesh (India).^{19,20}

The present study showed that the prevalence of double nutrient foramina were found in 28.85% of humeri which was similar to the findings observed by Carroll in London who reported 28.16% of humeri.¹⁷ Similar studies conducted by Bhatnagar et al. who reported 7.14% of humeri, Halagatti et al. (17.5%) and Solanke et al. (4%) found a lower incidence of double foramina in humeri to that of present study.²⁰⁻²² In contrast to this result, Joshi et al. reported 33% and 33.3% of double nutrient foramina observed by Shaheen.^{13,16}

Only few authors had observed the presence of triple nutrient foramina in the humeri. Similarly, the present study observed 6.32% of triple nutrient foramina in humeri which was almost similar to the studies conducted by Shaheen (6.7%) in Saudi Arabia and Kizilikant et al. (6.93%)

in Turkey whereas findings reported by Bhatnagar et al. (1.42%), Halagatti (2%) and Yaseen et al. (2%) which was comparatively lesser than the present result.^{16,20-24}

The present study also reported that quadruple nutrient foramina were present in 5 humeri (1.98%) which were comparatively higher to the study conducted by Kizilikant et al. in Turkey who reported the incidence of four nutrient foramina in 0.99% of humeri.²³

In the present study, it has been also observed that 1.98% of humeri did not have nutrient foramen which was similar to the study conducted by Kizilikant et al. who reported 1.98%.²³ A higher incidence of absence of the nutrient foramina (26% of humeri) was reported by Ukoha et al. in the humeri of Nigerians.²⁵ Absence of nutrient foramen in long bones is well known. In such cases, bones are supplied by periosteal arteries.²⁶ Knowing all these facts and anatomical details of nutrient foramen is important for surgeons involved in vascular surgery.²²

However, most of the authors in their study agreed that the majority of humeri had a single nutrient foramen at a higher incidence compared to that of the double or triple or the quadruple nutrient foramina.

Location of foramina

The nutrient foramina are situated a little below its midpoint on the antero medial surface close the medial border of humeri.⁴ However; the location of foramina may vary in position. The present study concluded that 88.86% of foramina were situated on antero-medial surface of the humeri which was in accordance to the findings of Halagatti et al. (87%) and Yaseen et al. (88.5%).^{21,24} In contrast to this, a study conducted by Khan et al. in humeri of Pakistan cadavers reported the higher incidence (96%) of nutrient foramina situated on the antero-medial surface of the shaft of the humeri.²⁷ But many authors reported the lesser incidence of the nutrient foramina on the antero medial surface of humeri. Such as Gopalakrishna et al. observed 70.97% of nutrient foramina and Vinay et al. reported only 30.23% of nutrient foramina on the antero-medial surface of humeri.^{28,29}

The present study also concluded that 6.52% of nutrient foramina were located on the posterior surface. Similar study was conducted by Ukoha et al. in humeri of Nigerian population and reported the incidence of 7.5% and Gopalakrishna et al. in their study observed 8.06% of nutrient foramina on posterior surface which were almost similar to the finding of the present study.^{25,28} However, a study conducted by Anusha et al. and observed the higher incidence (19%) of the presence of nutrient foramina on posterior surface than the present result.³⁰ Forriol et al. reported 15.55% of foramina in Spanish population and Kizilikant et al. (18.1%) in Turkish population which was comparatively also higher than the present result.^{18,23} But a study conducted in Pakistani cadavers by Khan et al. and reported that 2.66% of nutrient foramina were found to

be present on posterior surface which was comparatively lesser than the value of the present study.²⁷

The present study showed that the majority of nutrient foramina (94.84%) were found to be present in zone II (the middle one-third) of the shaft of the humeri which was correlated with the study conducted by Khan et al. who reported 96.20% of nutrient foramina on the middle one-third of humeri of Pakistan cadavers.²⁷ A study conducted by Ukoha et al. in humeri of Nigerian population found that 100% of the nutrient foramina were located on the middle one-third of the humeri and a similar trend also reported by Kumar et al. (100%) in Indian population which were higher than the present result.^{25,31} However, Halagatti et al. noticed that lower (84%) incidence of presence of nutrient foramina in the middle one-third of the shaft of humeri.²¹

Direction of foramina

Many studies had been conducted to observe the direction of nutrient foramina in humeri to determine that whether it follows the law of ossification or not. Berard reported that the direction of the nutrient foramina of humeri was constant and the nutrient canal was slanted towards that end at which the epiphysis was first united with the shaft of humeri.³²

The direction of the nutrient foramina were directed horizontally before birth but as the growth proceeds the direction of nutrient foramina were directed from the growing end of the humeri.³³

The present study observed that the direction of all the nutrient foramina of humeri was directed towards the lower end of humeri which was supported by many studies,^{21,27,28,31} which revealed that the direction of nutrient foramina were constant and obeys the law of ossification.^{20,24,25,30,34} Similarly, Kumar et al. reported that the direction of all nutrient foramina present in the humeri were directed away from the growing end of humeri except one which was directed towards the upper end.³¹ Similarly, Khan et al. also opined that 98.67% of the nutrient foramina were directed distally towards the lower end of humeri which was accordance with the present result.²⁷

The deviation from normal anatomical characteristics in which nutrient foramina were directed obliquely toward the elbow except one nutrient foramen which was directed horizontally.²⁴ Therefore, the present study concluded that the entire nutrient foramina present in the humeri was directed distally which indicates that it follows the law of ossification.

Pereira et al. reported the mean foraminal index was 55.2% and Pramard et al. also reported 55.2% which were in accordance with that of the present study.^{19,35} Ukoha et al. found that value of mean foraminal index for humeri was 56.28% in humeri of Nigerian population and Muralimanju et al. reported 57.6% among Indian population which were slightly higher in comparison to the present result.^{25,36} However, one study reported the lower value of mean foraminal index for humeri (52.65%).²¹

Limitation

The present study was retrospective study. Though the study was conducted on adult humeri, this may not be applicable for children. The exact determination of the gender was not studied. No any radiological methods were used.

CONCLUSION

The knowledge about the location of the nutrient foramina is highly important because of the increased chances of damage to the nutrient artery during open or close procedures. Damage to the nutrient artery may cause delayed union or non-union of the bone following fracture of humeral shaft. By having the knowledge of variations in the position of the nutrient foramina of humeri, placement of internal fixation devices can be appropriately done to limit the chances of delayed or non-union during fracture of the shaft of humeri. It will be helpful for the orthopedic surgeons to avoid this area during any surgical procedures such as bone repair, bone graft, microvascular bone surgery and during extensive stripping of the periosteum so that they can minimize the damage to the nutrient artery of humeri.

REFERENCES

1. Krishna Garg. BD Chaurasia's Hand Book of General Anatomy. Blood supply of bones. 4th ed. 2011. CBS Publishers and Distributors Pvt. Ltd:43-44.
2. Longia GS, Ajmani ML, Saxena SK, Thomas RJ. Study of diaphyseal nutrient foramina in human long bones. *Acta Anat.* 1980;107:399-406.
3. Sendemir E, Cimen A. Nutrient foramina in the shafts of lower limb long bones: situation and number. *Surg Radiol Anat.* 1991; 13:105-8.
4. Standring S. Gray's Anatomy, 40th ed. CHURCHILL LIVINGSTONE ELSEVIER, 2008:798.
5. Bokariya P, Gudadhe D, Kothari R, Murkey PN, Shende MR. Comparison of humerus and femur with respect to location and number of nutrient foramina. *Indian Journal of Forensic Medicine and Pathology.* 2012;5(2):79-81.
6. Henderson RG. The position of the nutrient foramen in the growing tibia and femur of the rat. *J Anat.* 1978; 125(3):593-9.
7. Mysorekar VR. Diaphysial nutrient foramina in human long bones. *J Anat.* 1967;101(4):813-22.
8. Nagel A. The clinical significance of the nutrient artery. *Orthop Rev* 1993; 22:557-61.

9. Dyankova S. Vascular anatomy of the radius and ulna diaphyses in their reconstructive surgery. *Acta Chir Plast* 2004; 46:105-9.
10. Choi SW, Kim HJ, Koh KS, Chung IH, Cha IH. Topographical anatomy of the fibula and peroneal artery in Koreans. *Int J Oral Maxillofac Surg* 2001;30:329-32.
11. Schiessel A, Zweymuller K. The nutrient artery canal of the femur: a radiological study in patients with primary total hip replacement. *Skeletal Radiol* 2004;33:142-9.
12. Hughes H. The factors determining the direction of canal for the nutrient artery in the long bones of mammals and birds. *Acta Anatomica*. 1952; 15(3): 261-280.
13. Joshi H, Doshi B, Malukar O. A study of the nutrient foramina of the humeral diaphysis. *NJIRM* 2011;2:14-17.
14. Hoy WE, Hughson MD, Bertram JF, Douglas-Denton R, Amann K. Nephron number, hypertension, renal disease, and renal failure. *J Am Soc Nephrol*. 2005;16(9):2557-64.
15. Sharma M, Prashar R, Sharma T, Wadhwa A. Morphological Variations of Nutrient Foramina in upper limb long bones. *Int J Med and Dent Sci*. 2013;2(2):177-81.
16. Shaheen SY. Diaphyseal nutrient foramina in human upper and lower limb long bones. A thesis submitted for the partial fulfillment of the requirement for the master degree in anatomy. 2009:20-21.
17. Carroll SE. A study of the nutrient foramina of the humeral diaphysis. *J Bone Joint Surg*. 1963; 45: 176-181.
18. Forriol FC, Gomez LP, Gianonatti MA, Fernandez RV. A study of the nutrient foramina in human long bones. *Surg Radiol Anat*. 1987;9: 251-5.
19. Pereira GAM, Lopes PTC, Santos AMPV, Silveira FHS. Nutrient foramina in the upper and lower limb long bones: Morphometric study in bones of southern Brazilian adults. *Int J Morph*. 2011;29(2):514-20.
20. Bhatnagar S, Deshwal AK, Tripathi A. Nutrient foramina in the upper and lower limb long bones: A morphometric study in bones of western Uttar Pradesh. *Int J Sci Res*. 2014;3(1):301-3.
21. Halagatti MS, Rangasubhe P. A study of nutrient foramina in dry adult humeri of south Indian subjects. *NJCA*. 2011;1(2):76-80.
22. Solanke KS, Bhatnagar R, Pokhrel R. The number and position of nutrient foramina in humerus, radius, ulna of human dry bones of Indian origin with clinical correlation. *OA*. 2014;2(1):1-8.
23. Kizilkanat E, Boyan N, Ozsahin ET, Soames R, Oguz O. Location, number and clinical significance of nutrient foramina in human long bones. *Ann Anat*. 2007;189:87-95.
24. Yaseen S, Nitya W, Ravinder M. Morphological and topographical study of nutrient foramina in adult humeri. *Int J Innov Res Sci Eng Technol*. 2014;3(4):7-10.
25. Ukoha UU, Umeasalugo KE, Nzeako HC, Ezejindu DN, Ejimofor OC, Obazie IF. A study of nutrient foramina in long bones of Nigerians. *Natl J Med* 2013;3(4):304-8.
26. Xinaris C, Benedetti V, Rizzo P, Ab-bate M, Corna D, Azzollini N, et al. In vivo maturation of functional renal organoids formed from embryonic cell suspensions. *J Am Soc Nephrol*. 2012;23(11):1857-68.
27. Khan AS, Shah Z, Inayat Q. Anatomical variations in diaphyseal nutrient foramina of humerus in cadavers from khyber pakhtunkhwa, pakistan. *Khyber Med Univ J*. 2014;6(1):18-21.
28. Gopalakrishna K, Sreekala MA, Rathna BS. A study on the incidence and direction of nutrient foramina in south Indian humeral diaphysis and their clinical importance. *J Med Heal Sci*. 2013;3(1):71-6.
29. Vinay G, Kumar AS. A study of nutrient foramina in long bones of upper limb. *Anat Karnataka*. 2011;5(3):53-6.
30. Anusha P, Naidu MP. A study on the nutrient foramina of long bones. *Jour of Med Sci and Tech*. 2013;2(3):150-7.
31. Kumar S, Kathiresan K, Gowda MST, Nagalaxmi. Study of diaphyseal nutrient foramina in human long bones. *Anat Karnataka*. 2012;6(2): 66-70.
32. Berard A. Memoirs Sur le Rapport Qui Existe Entre La Direction Des Conduits Nourriciers Des Os Longs, Et l'ordre Suivant Lequelles Epiphyses Se Soudent Au Corps De l'os. *Arch Gen Med Series*. 1835; 27:176-183.
33. Datta AK. Essentials of Human Osteology: General Consideration. 2nd ed. Kolkata. Current Books International 1997:5.
34. Chandrasekaran S, Shanthi KC. A study on the nutrient foramina of adult humeri. *J Clin Diagn Res*. 2013;7(6):975-7.
35. Parmar AMB, Vaghela B, Shah K, Patel B, Tridevi B. Morphometric analysis of nutrient foramina in human typical long bones of upper limb. *Natl J Integr Res Med*. 2014;5(5):26-9.
36. Murlimanju BV, Prashanth KU, Prabhu LV, Saralaya VV, Pai MM, Rai R. Morphological and topographical anatomy of nutrient foramina in human upper limb long bones and their surgical importance. *Rom J Morphol Embryol* 2011;52(3):859-62.