

# Acute Subperiosteal Hematoma of the Orbit with Visual Impairment: An Unconventional Presentation

Maithani T, Singh VP, Pandey A

Department of ENT

Shri Guru Ram Rai Institute of Medical & Health Sciences

Patel Nagar, Dehradun, India.

## Corresponding Author

Tripti Maithani

Department of ENT

Shri Guru Ram Rai Institute of Medical & Health Sciences

Patel Nagar, Dehradun, India.

E-mail: dr\_triptimaithani@yahoo.com

## Citation

Maithani T, Singh VP, Pandey A. Acute subperiosteal hematoma of the orbit with visual impairment: an unconventional presentation. *Kathmandu Univ Med J* 2016;53(1):84-6.

## INTRODUCTION

Orbital hematoma can be anatomically classified as intraorbital (intraconal/extraconal) or subperiosteal, of which the former is more common.<sup>1</sup> Subperiosteal hematoma (SpH) of the orbit is a rare condition which usually occurs due to blunt injury to orbit following craniomaxillofacial trauma. The presentation of SpH can be acute or chronic. Its symptoms include painful unilateral proptosis, generally inferolateral displacement of globe, absence of ecchymosis with mild diminution of visual acuity. We here present a rare case of acute SpH presenting with rapidly progressive proptosis accompanied with severe diminution of vision within hours of blunt facial trauma. Owing to its rapid onset and visual affection we would like to state that this case had an unconventional presentation.

## CASE REPORTS

A nine years old male child presented in ENT out patient department with chief complains of swelling of face right side, accompanied with swelling, pain and reduced vision in right eye. He had history of trauma to right side of face following fall on road in the morning same day. There

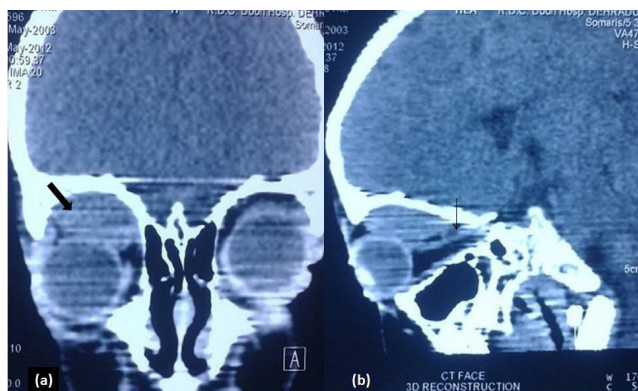
## ABSTRACT

Acute subperiosteal hematoma of orbit is a rare condition and its presentation with rapid severe diminution of vision is even rarest. Urgent intervention is required for these patients presenting with visual compromise. Needle aspiration is safe and simple procedure for management of such hematoma provided the patient presents early and does not have any associated complications. We present one such rare case highlighting the importance of timely diagnosis and urgent management to overcome functional complications in acute subperiosteal hematoma. To best of our knowledge this is the first pediatric case presenting with acute subperiosteal hematoma accompanied by severely diminished vision within few hours of trauma.

## KEY WORDS

*Needle aspiration, subperiosteal hematoma, visual acuity,*

was no significant past medical or surgical history. His examination revealed diffuse soft tissue swelling in right malar region, there was no active nasal or oral bleeding, no palpable bony crepitus or trismus. Bite of patient was normal. Ophthalmic examination of right eye revealed mild proptosis, lateral dystopia with restricted upward gaze (fig. 2a) whereas left eye was normal. Anterior segment examination revealed a sluggish pupillary reaction in right eye with grade I relative afferent pupillary defect. On examination of posterior segment, no disc oedema was seen, cup disc ratio was 0.3 with healthy neuroretinal rim and macula was found to be healthy. His visual acuity was counting fingers from 20 cms distance in right eye whereas 6/6 in left eye. Exophthalmometry revealed 2 mm proptosis in right eye. Intraocular pressure was 24.4 mm Hg (by Schiottz tonometer) in right eye and 17.3 mm Hg in left eye. Evaluation by neurosurgeon was done and no intracranial abnormality was detected. The patient was hospitalized and subjected to routine blood and urine examinations including coagulation profile, CECT of orbit and paranasal sinuses with 3D reconstruction of face, along with B scan ocular Ultrasound. The CT scan (fig. 1)

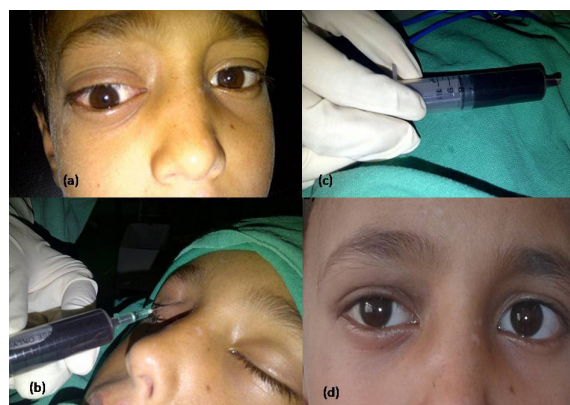

**Figure 1.** A preoperative CT scan of face (a) coronal scan reveals a fusiform, sharply defined, extraconal, non enhancing mass (bold black arrow) along the right superior orbital margin, displacing the orbital contents in downwards direction (b) sagittal scan showing obliteration of central orbital space and compression of optic nerve by the mass (black arrow)

of orbit and paranasal sinuses revealed a fusiform, sharply defined, extraconal, non-enhancing mass with a broad base along the right superior orbital margin. The mass was homogenous in appearance. It was seen abutting the bone and displacing the orbital contents in downwards direction and causing compression of optic nerve. However there was no discontinuity or fracture of skull bones. The USG-B scan of right eye was normal. Blood and urine examination revealed no abnormality. Based on these findings a diagnosis of posttraumatic acute SpH of right orbit was established. In view of reduced visual acuity of right eye the patient was posted for urgent decompression of hematoma. He underwent needle aspiration of hematoma (fig. 2b) under general anesthesia. A20G, 1.5 inch needle on 10 cc syringe was inserted along superior orbital margin just lateral to superior orbital notch right up to the bone and then the needle was gently withdrawn till the blood appeared in the syringe. About 7 cc of altered blood was aspirated (fig. 2c). Proptosis of right eye resolved immediately. Postoperative period was uneventful with visual acuity reverting to 6/6 in right eye and normal extraocular movements (fig. 2d). Patient is maintaining a regular follow-up and is asymptomatic eight months following surgery.

## DISCUSSION

SpH of orbit is a rare but well documented clinical entity. The various documented etiological factors are trauma which can be direct or transmitted, barometric, vascular lesions, hematological disorders and idiopathic.<sup>2</sup> In children the commonest cause of traumatic SpH is blunt trauma related to falls or direct impact.<sup>3</sup> It almost always presents in superior orbit due to mechanical disruption of small vessels under the periosteum. The reason for frequent development of hematoma in children is weak adherence of the periorbita to the roof of orbit thus it is easier for post traumatic bleed to collect here and form hematoma. Similar was the etiology in our case also.



**Figure 2.** (a) preoperative picture showing proptosis and lateral dystopia of right eye (b) intraoperative picture showing needle aspiration of hematoma (c) about 7cc of altered blood was aspirated (d) postoperative picture shows normal position of right eye

Major characteristics of SpH are sudden onset of unilateral proptosis, downward displacement of globe, motility impairment, diplopia, absence of ecchymosis and majority of times visual acuity is only mildly decreased.<sup>4</sup> However in our case apart from the usual features the visual acuity was markedly affected. The reason for decreased vision in SpH might be the increased intraocular pressure and direct compression of optic nerve and/or nutrient vessels supplying the nerve.<sup>5</sup>

Till date there are no fixed protocols for treatment of this condition. Conservative management is recommended in cases where the hematoma is insignificant with unaffected visual acuity.<sup>6</sup> Urgent surgical intervention is required for patients presenting with visual compromise, as was seen in our case. Reversal of severe visual impairment following decompression has been reported in literature.<sup>5</sup> Drainage of hematoma can be done by needle aspiration or surgical evacuation. In our opinion if the patient presents early without any associated complications like fracture of orbital roof or subgaleal hematoma then the treatment of choice should be needle aspiration of hematoma. Late presentation (where the hematoma becomes organized) or associated complications require surgical exploration. The merits of needle aspiration are simplicity of procedure and avoidance of a facial scar. Since our patient presented early and did not have any associated complications, he was managed by needle aspiration with a satisfactory outcome.

## CONCLUSION

Acute orbital Subperiosteal hematoma is a rare entity and can pose serious visual problems in patients. Such patients should be kept under observation and visual acuity should be monitored. Surgical intervention, when required, depends upon the time of presentation and associated complications. Timely decompression of the orbit reverts back the visual loss.

## REFERENCES

1. Carrion LT, Edwards WC, Perry LD. Spontaneous subperiosteal orbital hematoma. *Ann Ophthalmol* 1979;11:1754-7.
2. Duke-Elder S, Perkin ES. From Mechanical Injuries. In System of Ophthalmology. Reprint. Edited by Duke-Elder S. London: Henry Kimpton Publishers 1972; XIV: 285-91.
3. Yazici B, Gonen T. Posttraumatic Subperiosteal Hematomas of the orbit in children. *Ophthalmic plastic and reconstructive surgery* 2011;27(1): 33-7
4. Crawford C, Mazzoli R. Subperiosteal hematoma in multiple settings. *Digital journal of Ophthalmology* 2013;19(1)DOI:10.5693/djo.02.2013.01.001
5. Gillum WN, Anderson RL. Reversible visual loss in subperiosteal hematoma of the orbit. *Ophthalmic Surg* 1981;12:203-9.
6. Griffeth MT, Dailey RA, Ofner S. Bilateral spontaneous subperiosteal hematoma of the orbits: a case report. *Arch Ophthalmol* 1997;115: 679-80.