

Orthognathic Surgery for the Correction of Severe Skeletal Class III Malocclusion

Kafle D, Upadhayaya C, Chaurasia N, Agarwal A

Department of Dentistry

Dhulikhel Hospital, Kathmandu University Hospital,

Kathmandu University School of Medical Sciences,

Dhulikhel, Kavre, Nepal.

Corresponding Author

Dashrath Kafle

Department of Dentistry

Dhulikhel Hospital, Kathmandu University Hospital,

Kathmandu University School of Medical Sciences

Dhulikhel, Kavre, Nepal.

E-mail: dashrath07@yahoo.com

Citation

Kafle D, Upadhayaya C, Chaurasia N, Agarwal A. Orthognathic surgery for the correction of severe skeletal class III malocclusion. *Kathmandu Univ Med J* 2016;53(1):90-3.

ABSTRACT

Skeletal Malocclusions results from the abnormal position of maxilla and mandible in relation with cranial base. These types of malocclusion are commonly treated by orthodontic teeth movement known as camouflage orthodontics. However severe skeletal malocclusions cannot be treated by orthodontics alone. Such cases need surgical intervention to align the position of the jaw along with orthodontic correction. This procedure is commonly known as Orthognathic Surgery. Orthognathic Surgery dates back to early eighteenth century but became popular on mid twentieth century. Though the prevalence of skeletal malocclusion is more than 1% the treatment facility was not available in Nepal till 2012. Here we present a case of Skeletal Class III malocclusion treated at Dhulikhel Hospital, Kathmandu University Hospital. For this case, double jaw surgery was performed by le-Fort I osteotomy and Bilateral Sagittal Split Osteotomy. Orthognathic surgery has been routinely performed at this centre since then.

KEY WORDS

Bilateral Sagittal split Osteotomy, Le-fort I Osteotomy, orthognathic surgery, skeletal malocclusion

INTRODUCTION

Skeletal malocclusions are those type of malocclusion which result from the abnormal position of maxilla and mandible with cranial base where as dental malocclusions are those which result from abnormal relation of teeth. Commonly both the skeletal as well as dental malocclusions are divided into Class I,II and III. The prevalence of Class III malocclusion is approximately 1-7%.¹⁻⁶ This can go upto 12% on patients with craniomandibular dysfunctions.^{7,8} More than 2% of the overall malocclusion are severe enough which limits the orthodontic treatment alone.⁹ The treatment of skeletal malocclusion varies depending on the severity of the problem, age of the patient, patient's expectation and availability of all the treatment modalities. Skeletal malocclusion in growing children can be treated either by myofunctional appliances or by orthopaedic appliances. However these therapies are associated with obvious controversies. It's still not clear whether these appliances produce pure skeletal effect or mere dentoalveolar changes.¹⁰⁻¹³

Another popular way of treating such abnormalities in non-growing individuals is camouflage orthodontics in which skeletal abnormality is marred by differential extractions in single or both the jaws.¹⁴ Skeletal class II malocclusion is usually treated by extraction of maxillary first premolars and mandibular second premolars where as in skeletal class III Camouflage extraction pattern is mandibular first premolars and maxillary second premolar. Camouflage orthodontics is very popular because it avoids complicated surgery and orthodontists can deliver treatment alone.

When skeletal discrepancy is severe and patient has already crossed the growing phase, orthognathic surgery is the only treatment option available. However orthognathic surgery is a relatively complex procedure done under general anaesthesia which involves multi-disciplines of the dentistry viz Orthodontics and Maxillofacial Surgery mainly and Prosthodontics, Restorative Dentistry and Periodontics occasionally. Here we report a case done at Dhulikhel

Hospital, Kathmandu University School of Medical Sciences. Orthognathic surgery was started four years ago and is now routinely performed in Nepal at Dhulikhel Hospital.

CASE REPORTS

A 20 years old male patient is initially seen by Author B in 2008 with the chief complain of protruded lower jaw and inability to meet upper and lower front teeth. He does not have any significant medical and dental history. Extraoral examination revealed dolicocephalic head, leptoprosopic face , concave facial profile, increased lower facial height and hyperdivergent mandible (Fig. 1). On Intra oral examination there was class III molar and canine relationship on both sides, reverse overjet of 9 mm, midline shift by 3 mm towards left, posterior crossbite, moderate crowding in both the arches as well as proclined maxillary anteriors and retroclined mandibular anteriors (Fig. 2). Orthopantomograph showed normally developed dentition with impacted all four third molars. Lateral cephalograph suggested skeletal class III malocclusion secondary to mandibular prognathism and mild maxillary retrognathism (Fig. 3).



Figure 1. Pre-treatment extra oral photograph.

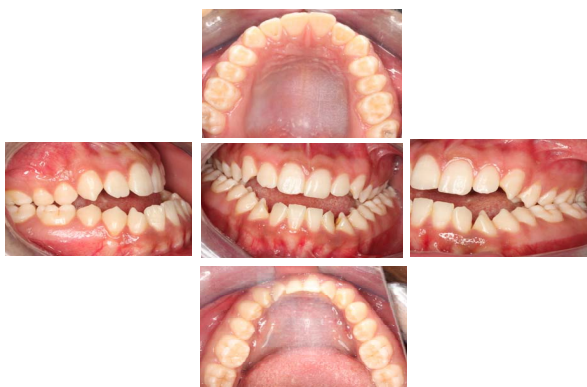

Figure 2. Pre treatment intra oral photograph.

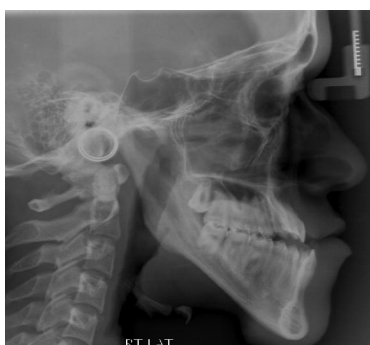

Figure 3. Pre-treatment lateral cephalograph.

So the case was diagnosed to be Skeletal Class III Malocclusion with Mandibular Prognathism, maxillary retrognathism with reverse overjet and posterior cross bite with midline shift. The treatment plan was Orthognathic Surgery which consisted of : Pre-surgical orthodontics, Surgery to reposition the aberrant jaws, post surgical orthodontics followed by retention. The presurgical orthodontics involved banding and bonding with mechanics mainly involved to decompensate the naturally compensated dentition, aligning and levelling (Fig. 4). This phase took almost nine months because of the moderate crowding and posterior cross bite. The surgical procedure consisted of double jaw surgery involving maxillary advancement with le fort I osteotomy and mandibular setback with Bilateral Sagittal Split Osteotomy (BSSO). The patient was admitted in hospital and discharged on 5th Post-operation day with class II, ¼" guiding elastics. The post surgical orthodontic included detailing and finishing of the occlusion and minor corrections (Fig. 5). This phase consisted of six months. Retention phase was started after removal of the bands and brackets. The patient is still in retention phase. The post treatment result shows pleasant facial profile, reduced facial height and coincident midline and Class I molar and canine relation (Fig. 6,7,8).³ years follow up has shown stable treatment result with very minimal relapse tendency.

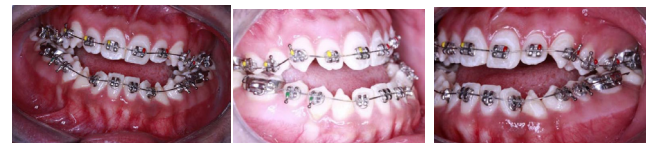


Figure 4. Pre-surgical orthodontics.

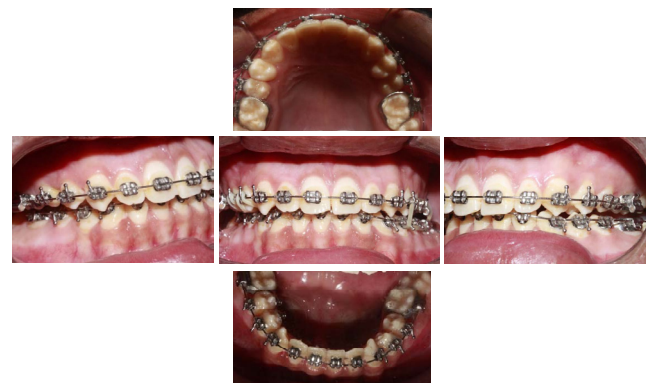

Figure 5. Post-surgical orthodontics.

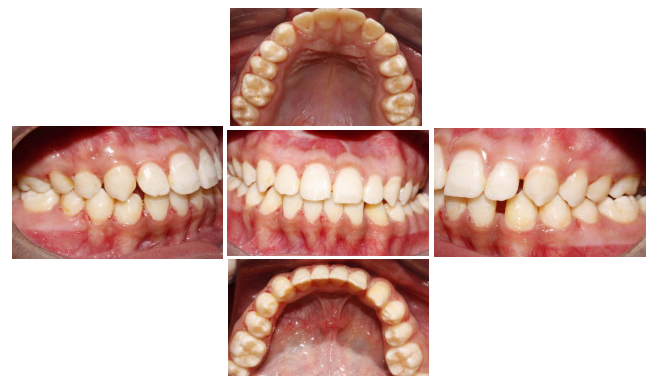

Figure 6. Post treatment intra oral.

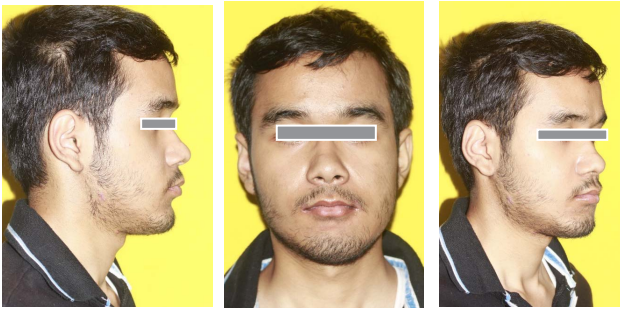

Figure 7. Post treatment extra oral.

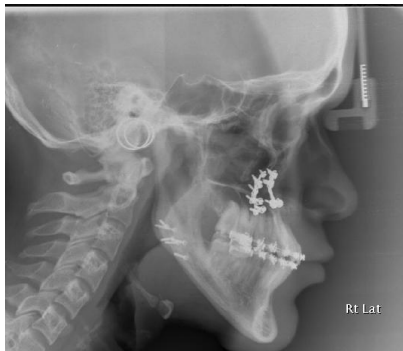

Figure 8. Post treatment lateral cephalograph.

DISCUSSION

Although history of Orthognathic surgery dates back to nineteenth century, the modern orthognathic surgery can said to be popularized in early 1950s by Obwegeser.¹⁵⁻¹⁷ Though basic principle of orthognathic surgery is same there are several modifications done on surgical procedures. For maxillary advancement Le fort I and for mandibular set back BSSO are the main work horse procedures for the surgeons. The importance of pre-surgical orthodontic therapy is many folds especially in case of naturally compensated dentition. This phase of treatment lasts from six months up to one year depending upon the severity of dental malocclusion. If this phase contains extraction of teeth, then the duration is longer. This phase consists of arch coordination, decompensation, aligning and levelling. The surgical phase is most critical phase of this treatment. The surgeons and orthodontists have to sit together and decide surgery for most stable and aesthetically pleasing position. It might consist of single or double jaw surgery occasionally combined with adjunctive surgeries like genioplasty, rhinoplasty as well as cheiloplasty. Before surgery mock surgery is done on the plaster model and splints are fabricated. Usually when double surgery is planned intermediate and final splints are fabricated with different color coding. In our case maxillary advancement

with Le Fort I osteotomy and Mandibular set back with BSSO was performed. The maxillary position was fixed with miniplates whereas mandibular position was fixed with bicortical screws. Mandibular position can be fixed with miniplates too. As compared with wire fixation, rigid fixation gives better stability whether it is bicortical screws or miniplates.¹⁸ Some studies has shown that Miniplates are preferred than bicortical screws however some studies did not find any difference on both the methods of fixation.^{19,20} Now a days bioresorbable fixation screws are on use. These bioresorbable screws are found to be as effective as the non resorbable screws.^{21,22} The complications of surgery are haemorrhage, non union, malunion, paresthesia etc.²³ Transient paraesthesia of the maxillary and mandibular area is most common complication. However this improves with time.

The postsurgical phase lasts around six months. In this phase some residual malocclusion is corrected. Immediately after surgery there is tendency to develop posterior open bite which is corrected by inter maxillary elastics. The post-surgical orthodontic tooth movement is fast which is explained by Rapid Accelerating Phenomenon (RAP). It is natural to have a tendency to relapse. So to prevent relapse, different mechanics are suggested such as inter maxillary elastics, reverse pull head gear, chin cup etc. In our case we applied class III elastics to prevent relapse. Different factors are associated with relapse such as lack of control of segmented parts, soft tissue and muscle pull, inadequate fixation, age of the patient, Temporo Mandibular joint derangement etc. Good post surgical finising of the occlusion is also the key factor to retain the treatment results.²⁴⁻²⁶

The patient was kept on retention with lower bonded retainer as well as Hawley's retainers on both maxillary and mandibular arches. The patient is still on follow up. The post treatment result is stable after 30 months of debonding.

CONCLUSION

A good teamwork is needed for great results during the treatment of severe skeletal malocclusion. The treatment result is not only very rewarding for the involved team but also for the patient to adapt psychosocially.

ACKNOWLEDGEMENT

We would like to acknowledge Dr. Binam Sapkota for her help during the fabrication of surgical splints.

REFERENCES

1. Van Vuuren C. A review of the literature on the prevalence of Class III malocclusion and the mandibular prognathic growth hypotheses. *Aust Orthod J*. 1991 Mar;12(1):23-8.
2. Guaba K, Ashima G, Tewari A, Utreja A. Prevalence of malocclusion and abnormal oral habits in North Indian rural children. *J Indian Soc Pedod Prev Dent*. 1998 Mar;16(1):26-30.
3. Vellappally S, Gardens SJ, Al Kheraif AA, Krishna M, Babu S, Hashem M, et al. The prevalence of malocclusion and its association with dental caries among 12-18-year-old disabled adolescents. *BMC Oral Health*. 2014;14:123.
4. Aikins EA, Onyeaso CO. Prevalence of malocclusion and occlusal traits among adolescents and young adults in Rivers State, Nigeria. *Odontostomatol Trop*. 2014 Mar;37(145):5-12.

5. Reddy ER, Manjula M, Sreelakshmi N, Rani ST, Aduri R, Patil BD. Prevalence of Malocclusion among 6 to 10 Year old Nalgonda School Children. *J Int Oral Health*. 2013 Dec;5(6):49-54.
6. Muppa R, Bhupathiraju P, Duddu MK, Dandempally A, Karre DL. Prevalence and determinant factors of malocclusion in population with special needs in South India. *J Indian Soc Pedod Prev Dent*. 2013 Apr-Jun;31(2):87-90.
7. Popovic N, Drinkuth N, Toll DE. Prevalence of class III malocclusion and crossbite among children and adolescents with craniomandibular dysfunction. *J Orofac Orthop*. 2014 Jan;75(1):36-41.
8. Silva RG, Kang DS. Prevalence of malocclusion among Latino adolescents. *Am J Orthod Dentofacial Orthop*. 2001;119(3):313-5.
9. Proffit WR, Fields HW, Jr., Moray LJ. Prevalence of malocclusion and orthodontic treatment need in the United States: estimates from the NHANES III survey. *Int J Adult Orthodon Orthognath Surg*. 1998;13(2):97-106.
10. Yagci A, Uysal T, Kara S, Okkesim S. The effects of myofunctional appliance treatment on the perioral and masticatory muscles in Class II, Division 1 patients. *World J Orthod*. 2010 Summer;11(2):117-22.
11. Negoro T, Tanaka S, Kajiwara T, Miwa H, Goto S, Kita Y. [Treatment changes in skeletal maxillary protrusion. The effect of cervical headgear and early treatment]. *Aichi Gakuin Daigaku Shigakkai Shi*. 1985 Sep;23(3):579-89.
12. Pancherz H, Anehus-Pancherz M. The headgear effect of the Herbst appliance: a cephalometric long-term study. *Am J Orthod Dentofacial Orthop*. 1993 Jun;103(6):510-20.
13. De Clerck H, Timmerman H. [Effect of headgear activator treatment and of mandibular advancement osteotomy on profile convexity]. *Rev Belge Med Dent*. 1994;49(4):63-74.
14. Kinzinger G, Frye L, Diedrich P. Class II treatment in adults: comparing camouflage orthodontics, dentofacial orthopedics and orthognathic surgery--a cephalometric study to evaluate various therapeutic effects. *J Orofac Orthop*. 2009 Jan;70(1):63-91.
15. Steinhäuser EW. Historical development of orthognathic surgery. *J Craniomaxillofac Surg*. 1996 Aug;24(4):195-204.
16. Drommer RB. The history of the "Le Fort I osteotomy". *J Maxillofac Surg*. 1986 Jun;14(3):119-22.
17. Obwegeser HL. Orthognathic surgery and a tale of how three procedures came to be: a letter to the next generations of surgeons. *Clin Plast Surg*. 2007 Jul;34(3):331-55.
18. Van Sickels JE, Richardson DA. Stability of orthognathic surgery: a review of rigid fixation. *Br J Oral Maxillofac Surg*. 1996 Aug;34(4):279-85.
19. Ochs MW. Bicortical screw stabilization of sagittal split osteotomies. *J Oral Maxillofac Surg*. 2003;61(12):1477-84.
20. Stoelinga PJ, Borstlap WA. The fixation of sagittal split osteotomies with miniplates: the versatility of a technique. *J Oral Maxillofac Surg*. 2003;61(12):1471-6.
21. Yang L, Xu M, Jin X, Xu J, Lu J, Zhang C, et al. Skeletal stability of bioresorbable fixation in orthognathic surgery: a systemic review. *J Craniomaxillofac Surg*. 2014 Jul;42(5):e176-81.
22. Ahn YS, Kim SG, Baik SM, Kim BO, Kim HK, Moon SY, et al. Comparative study between resorbable and nonresorbable plates in orthognathic surgery. *J Oral Maxillofac Surg*. 2010 Feb;68(2):287-92.
23. Robl MT, Farrell BB, Tucker MR. Complications in orthognathic surgery: a report of 1,000 cases. *Oral Maxillofac Surg Clin North Am*. 2014 Nov;26(4):599-609.
24. Wisth PJ, Isaksen TS. Changes in the vertical position of the anterior teeth after surgical correction of mandibular protrusion. *Am J Orthod*. 1980 Feb;77(2):174-83.
25. Ritzau M, Wenzel A, Williams S. Changes in condyle position after bilateral vertical ramus osteotomy with and without osteosynthesis. *Am J Orthod Dentofacial Orthop*. 1989 Dec;96(6):507- 13.
26. Pike JB, Sundheim RA. Skeletal and dental responses to orthognathic surgical treatment. *Angle Orthod*. 1997;67(6):447-54.