

Osteomyelitis of Humerus and Intramuscular Abscess Due to Melioidosis

Vijaykumar GS, Thilakavathy P, Jeremiah SS, Vithiya G

Department of Microbiology

Velammal Medical college Hospital & Research Institute

Madurai, India.

Corresponding Author

Pandurangan Thilakavathy

Department of Microbiology

Velammal Medical college Hospital & Research Institute

Madurai, India.

E-mail: thilaka_doctor@yahoo.co.in

Citation

Vijaykumar GS, Thilakavathy P, Jeremiah SS, Vithiya G. Osteomyelitis of Humerus and Intramuscular Abscess Due to Melioidosis. *Kathmandu Univ Med J* 2016;54(2):184-5.

INTRODUCTION

Melioidosis is an emerging infectious disease in India and in recent years several cases have been reported from different parts of India.^{1,2} Melioidosis is endemic in Southeast Asia and northern Australia.³ Melioidosis is a disease known as “the great mimicker” because of its similarity to other infections and the difficulty with its diagnosis.⁴ Diagnostic confirmation mainly relies on the isolation of the organism (*Burkholderia pseudomallei*). Due to lack of awareness and low index of suspicion, melioidosis has been under diagnosed and under reported in many tropical countries which under-estimates the global burden of this infection.^{5,6}

CASE REPORTS

Thirty one year old paddy field worker presented with complaints of pain and swelling in right arm for the past 15 days. He was a known diabetic patient, six months back he had fracture of humerus (proximal end) for which

ABSTRACT

Melioidosis is a clinically diverse disease caused by gram negative bacterium *Burkholderia pseudomallei*. It is a potential bioterrorism agent. The high risk group includes the agricultural and construction workers whose contact with contaminated soil and water may expose them to bacteria. The clinical manifestations varies from asymptomatic infection to overwhelming sepsis. To diagnose melioidosis a high index of suspicion along with isolation and identification of the organism from the clinical samples is needed. Early diagnosis and treatment is essential for better outcome. We are reporting a case of melioidosis which presented as osteomyelitis of humerus with intramuscular abscess.

KEY WORDS

Burkholderia pseudomallei, melioidosis, osteomyelitis

he had undergone fixation of proximal end of humerus. After thorough clinical and radiological evaluation he was diagnosed to have osteomyelitis of right proximal humerus with intramuscular abscess. Incision and drainage of the abscess was done under aseptic precaution. Patient developed fever, hypotension, dyspnoea. Pus and blood samples were sent for microbiological analysis. X-ray chest findings were suggestive of right lower lobe pneumonitis. Hematological values were elevated [Total Count (23,500), Erythrocyte Sedimentation Rate (21 mm)], C Reactive Protein was positive. Within 48 hrs patient died of sepsis.

Microbiological analysis

Melioidosis is classified by the Centers for Disease Control as a category B bioterrorism concern and biohazard to the lab workers. Patient samples with clinical suspicion of melioidosis cultures should be performed in Biosafety level-2. Pus and blood culture collected from this patient yielded *Burkholderia pseudomallei*. Pus sample

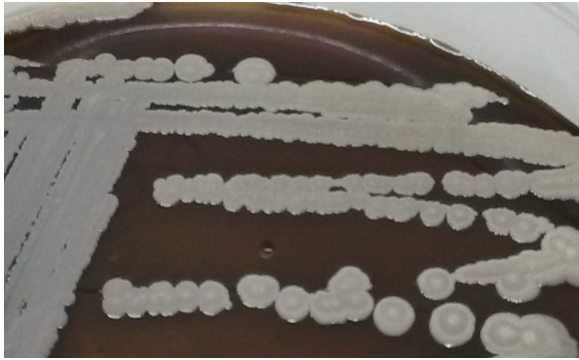


Figure 1. Blood agar plate showing wrinkled colonies with metallic sheen.

was cultured on blood agar, Mac conkey agar and fluid thioglycollate medium. On blood agar plate colonies appeared creamy white with a metallic sheen and on further incubation colonies become wrinkled. Mac conkey agar showed lactose fermenting colonies. It was gram negative bacilli, oxidase positive and motile. Antimicrobial susceptibility testing was done on Mueller Hinton agar by disc diffusion method according to Clinical and Laboratory Standard Institute guidelines. The isolate was sensitive to cotrimoxazole, ciprofloxacin, imipenam, piperacillin tazobactam, cefepime, ceftazidime, colistin, and resistant to gentamicin and polymixin B (300 units/disc). The isolate was confirmed by Vitek2.

DISCUSSION

Burkholderia pseudomallei, the causative agent of melioidosis is an environmental pathogen. It is widely disseminated in contaminated soil and water and common mode of transmission to humans is mainly through

inhalation and inoculation. It infects individuals with predisposing factors like diabetes mellitus and alcoholism. The predisposition to melioidosis in individuals with diabetes and those with excessive alcohol intake appears to be related primarily to impaired neutrophil function, such as mobilisation, delivery, adherence, and ingestion.^{7,8}

Melioidosis can be categorized as an acute or localized infection, acute pulmonary infection, acute bloodstream infection or disseminated infection.^{11,12} Subclinical infections are also possible. The incidence of musculoskeletal melioidosis in Northern Australia is 3.7% and in a study conducted in western coastal area of India, the incidence is 20%.^{3,9}

In this case, patient was diagnosed as osteomyelitis with intra muscular abscess, and melioidosis was not suspected initially. Patient developed sepsis and succumbed. Melioidosis was diagnosed based on the isolation of the organism, *Burkholderia pseudomallei* from pus and blood samples. Melioidosis as a cause of proximal humeral osteomyelitis was a rare clinical presentation. The epidemiology and risk factors of melioidosis had been extensively studied in endemic areas and high mortality rates had been reported (14-50%).¹⁰ Mortality was seen only in patients with bacteremia.³

CONCLUSION

Melioidosis is probably under diagnosed and under reported in India. Occupational exposure and concurrent medical illness together with a high index of clinical suspicion helps in diagnosing melioidosis. The diagnosis of melioidosis can be made easy if it is both after considered by the clinicians and microbiologists.

REFERENCES

1. Anuradha K, Meena AK, Lakshmi V. Isolation of *Burkholderia pseudomallei*: from a case of septicaemia - A case report. *Indian J Med Microbiol* 2003;21:129-32.
2. Vidyalakshmi K, Shrikala B, Bharathi B, Suchitra U. Melioidosis: an under-diagnosed entity in western coastal India: a clinical microbiological analysis. *Indian J med Microbiol* 2007;25:245-8.
3. Chaowagul W, White NJ, Dance DA, Wattanagoon Y, Naigowit P, Davis TM et al. Melioidosis: a major cause of community acquired septicemia in northeastern Thailand. *J Infect Dis* 1989;159:890-9.
4. Yee KC, Lee MK, Chua CT, Puthuchearu SD. Melioidosis, the great mimicker: a report of 10 cases from Malaysia. *J Trop Med Hyg.* 1988;91(5):249-54.
5. R Gopalakrishnan, D Sureshkumar, MA Thirunarayan, V Ramasubramanian. Melioidosis : an emerging infection in India: *J Assoc Physicians India.* 2013 Sep;61(9):612-4.
6. John TJ. Emerging and re-emerging bacterial pathogens in India. *Indian J Med Res.* 1996;103:4-18.
7. Jones AL, Beveridge TJ, Woods DE. Intracellular survival of *Burkholderia pseudomallei*. *Infect Immun* 1996;64:782-90.
8. Marhoffer W, Stein M, Maeser E, Federlin K. Impairment of polymorphonuclear leukocyte function and metabolic control of diabetes. *Diabetes Care.* 1992 Feb;15(2):256-60.
9. BJ Currie, L Ward, AC Cheng. The epidemiology and clinical spectrum of melioidosis: 540 cases from the 20 year Darwin prospective study. *PLoS Negl Trop Dis.* 2010 Nov 30;4(11).
10. Cheng AC, Currie BJ. Melioidosis: epidemiology, pathophysiology, and management. *Clin Microbiol Rev.* 2005;18(2):383-416.
11. Mukhopadhyay C, Krishna S, KE Vandana, Saravu K, Balasubramaniam R. Tuberculosis or melioidosis? - look twice in Southwestern coastal India. *SAARC Journal of Tuberculosis, Lung Diseases & HIV/AIDS* 2012;IX(2):15-8.
12. Deepak Madi, Basavaprabhu Achappa, Mridula Laxman, John T Ramapuram, Nithyananda Chowta, Sujani Yadlapati et al. Multiple pyogenic liver abscess – Case report. *Asian Journal of Medical Science* 2014; 5(2):137-9.