

Persistent Trophoblastic Disease at Cesarean Scar

Biswas R, Saxena P, Gupta U, Choudhary N, Chawla R

Department of Obstetrics and Gynaecology,
Lady Hardinge Medical College,
New Delhi, India.

Corresponding Author

Pikee Saxena

Department of Obstetrics and Gynaecology,
Lady Hardinge Medical College,
New Delhi, India.

E-mail: pikesaxena@hotmail.com

Citation

Biswas R, Saxena P, Gupta U, Choudhary N, Chawla R. Persistent Trophoblastic Disease at Cesarean Scar. *Kathmandu Univ Med J* 2016; 56(4):376-9.

INTRODUCTION

Pregnancy at cesarean section scar site of uterus is the rarest cause of ectopic pregnancy, and its incidence ranges from 1:1800 to 1:2216.¹ The incidence of complete molar pregnancy is about 1:1945 and partial molar pregnancy is 1:695 pregnancies.² Thus likelihood of molar pregnancy at the cesarean scar is very low and likelihood of persistent trophoblastic disease at cesarean scar site is still lower. We report a case of a persistent trophoblastic disease at the site of cesarean section scar.

CASE REPORTS

Thirty one year old female patient, para 2 with 2 living issues with history of previous cesarean section presented to our hospital with complain of persistent nausea. Her last menstrual period (LMP) was 25/8/2013. At 5 weeks 2 days from her last LMP, on getting a positive urine pregnancy test, she took 200 mg of Mifepristone followed by 400 µg of Misoprostol for medical abortion. She underwent

ABSTRACT

Pregnancy over the cesarean scar is the rarest cause of ectopic pregnancy and development of persistent trophoblastic disease at the scar site is extremely rare. A high index of suspicion is needed for early diagnosis and management of cesarean scar molar pregnancy. This condition is difficult to diagnose and must be considered in the patient with a history of cesarean section who has persistent vaginal bleeding or symptoms of pregnancy after suction evacuation. Diagnosis can be confirmed by measuring β Human Chorionic Gonadotropin levels, transvaginal ultrasound with doppler flow evaluation. As this is an uncommon condition, this case report with conservative non surgical approach will add up to its clinical spectrum.

KEY WORDS

Caesarean scar, ectopic, persistent trophoblastic disease

dilatation and curettage at some local clinic for heavy vaginal bleeding following these medications and was discharged the next day. She had persistent nausea even after 2 weeks of dilatation and curettage and reported back to the clinic, where she was advised serum β human chorionic gonadotropin (HCG) and a pelvic ultrasound and was referred to our hospital. Her obstetric history revealed one preterm caesarean section performed four years ago for chorioamnionitis with failed induction. Following this, she had a vaginal birth after caesarean section.

On examination, her vitals were stable and mild pallor was noted. Per abdominal examination revealed previous pfannensteil scar. No muscle guarding or tenderness was observed. No mass was palpable per abdominally. Pelvic examination revealed closed cervical os with no cervical motion tenderness and no adnexal tenderness. Uterus was enlarged to 8 weeks size pregnant uterus, anteverted, mobile, non tender. No adnexal mass was palpable and the pouch of Douglas was free.

Her investigation revealed hemoglobin of 9.6 gm/dl. Her liver, kidney and thyroid function tests were within normal limits. Her initial β HCG was 15000 miu/ml and pelvic ultrasound report revealed a 37×37×30 mm hyperechoic lesion in the anterior uterine wall in the region of previous scar suggestive of scar site pregnancy with retained products of conception. The other differential diagnosis considered were scar site hematoma or ectopic pregnancy or molar pregnancy or persistent trophoblastic disease.

On repeating the β HCG after seven days, levels rose to 31332 miu/ml. Repeat ultrasound revealed 4.8×3.5 cm heterogenous, heteroechoic lesion with cystic spaces noted in anterior myometrium of lower uterine segment with thinned out, stretched anterior myometrium. Endometrial cavity was empty with normal endometrial lining. On color Doppler, increased vascularity with low resistance flow was noted predominantly in periphery of lesion. Bilateral ovaries were normal and there was no free fluid in the abdomen or pouch of Douglas (Fig. 1).

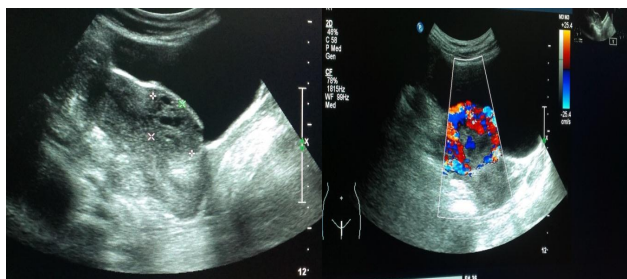


Figure 1. A 4.8 ×3.5 cm heteroechoic lesion with cystic spaces noted in anterior myometrium of lower uterine segment with thinned out stretched myometrium. Endometrial lining is normal. On color Doppler, low resistance, increased vascularity noted predominantly in periphery of the lesion.

MRI findings depicted bulky uterus having heterogenous lesion in anterior wall of the lower uterine body with hyperintense signal on T2W and STIR with minimal restricted diffusion DW1. Endometrial echo was normal. Blooming was seen on gradient-echo, indicative of hemosiderin. These findings were suggestive of scar site invasive mole or scar endometrioma or implantation of pregnancy over intramural hematoma (Fig. 2).

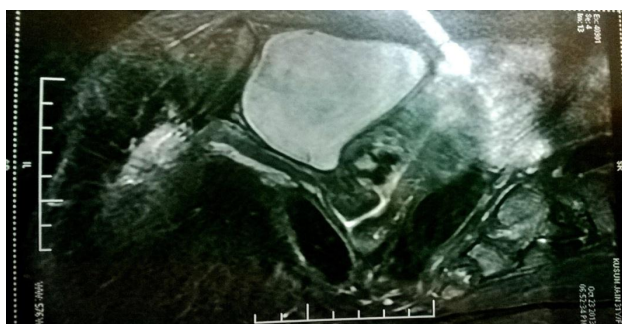

Figure 2. Bulky uterus showing heterogenous lesion in anterior wall of the lower uterine body appearing as hyperintense signal on T2W. Endometrial echo normal. Blooming present (indicative of hemosiderin)

Based on history, examination, rising β HCG value, ultrasound and MRI reports, final diagnosis of persistent gestational trophoblastic disease at caesarean scar site, with federation of international gynaecologists and obstetricians (FIGO) score 4 was made.³ The persistence of cystic spaces at the scar site with increased vascularity and rising β HCG values following dilatation and curettage was suggestive of persistent trophoblastic disease at the scar site. Patient was treated with single agent chemotherapy with injection methotrexate 1 mg/kg on day 1,3,5,7 and injection folinic acid 5 mg intramuscular on day 2,4,6,8 because the patient wanted to preserve her fertility. Response to chemotherapy was monitored by serial β HCG values and ultrasonography measuring the size of the lesion and noting the vascularity on Doppler. She received total eight cycles of single agent Methotrexate at 2 weekly intervals.

After first cycle of Methotrexate, β HCG values decreased from 31332 miu/ml to 2812 miu/ml. β HCG value normalised to 3 miu/ml after the 6th cycle of chemotherapy. She received two more cycles of chemotherapy after normalisation of β HCG value. After eight cycles of chemotherapy, lesion size reduced to 13×17 mm size with markedly reduced vascularity with β HCG \leq 1.2 miu/ml (Fig. 3). Ultrasonography was done monthly and the lesion disappeared completely after 14 weeks. Surveillance was done for remission of the disease and the patient was followed up with β HCG values every 2 weekly for 3 months, monthly for 1 year and thereafter is being followed 6 monthly for 3 years. Patient was advised to use barrier contraception to avoid pregnancy for 1 year after end of chemotherapy.

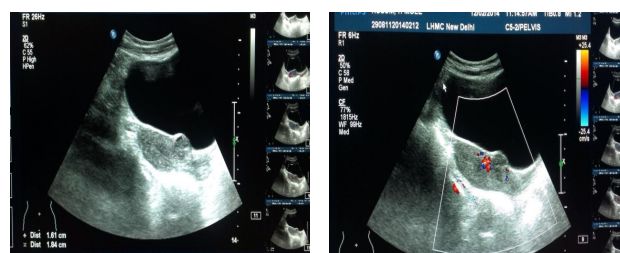


Figure 3. Size of the lesion reduced to 13×17 mm size and vascularity decreased significantly

DISCUSSION

Gestational trophoblastic disease is a spectrum of diseases which includes hydatidiform moles, invasive moles, gestational choriocarcinomas and placental site trophoblastic tumors. Review of medical literature revealed only a few cases of ectopic molar pregnancy reported in caesarean section scar.⁴⁻⁸ Thus caesarean site molar pregnancy is extremely rare and carries a high risk of uterine rupture and uncontrollable haemorrhage presenting as vaginal bleeding, intra-peritoneal bleeding and shock. While few cases of caesarean scar site partial and complete molar pregnancy have been reported

worldwide, current literature does not reveal any case of caesarean site persistent molar pregnancy.

Patients having caesarean site molar pregnancy present with symptoms of early pregnancy complication such as abnormal vaginal bleeding, abdominal pain, persistent spotting after uterine evacuation.⁶ In this case, it is difficult to say whether the index pregnancy was molar pregnancy or abortion since a pelvic sonogram was not obtained before evacuation. Since patient had high β HCG levels following evacuation, she was managed as persistent trophoblastic disease at caesarean scar site which commonly follows a molar pregnancy.

An important characteristic of molar pregnancy, caused by trophoblastic proliferation, is its ability to form β HCG. Therefore, serum β HCG serves as a tumour marker and its serial quantitative measurement helps to follow up these women indicating residual disease activity. High β HCG levels with the presence of cystic spaces and absence of foetal cardiac activity indicates molar pregnancy. High resolution transvaginal sonography including doppler further plays an important role in the clinical evaluation of molar pregnancy.³

Caesarean scar site pregnancy should be suspected in a woman with irregular bleeding showing uterine endometrial or myometrial heterogenous mass lying close to cesarean scar anteriorly, along with a high levels of serum β HCG. This uterine mass reflects tissue invasion, necrosis and haemorrhage. In suspicious cases the radiologist should carefully look for caesarean scar and uterine integrity.⁹ The ultrasound criteria for caesarean scar pregnancy includes an empty uterine cavity and endocervical canal with closed cervical os, detection of the placenta, gestational sac or heterogenous mass embedded in the cesarean scar, a thin (1 – 3 mm) myometrial layer between the gestational sac and the bladder.¹⁰ A closed and empty endocervical canal and a discontinuity in the anterior wall of the uterus may also suggest scar site pregnancy.¹¹ Doppler, however, is much more helpful, showing the hypervascularity of invasive trophoblast. Colour doppler abnormalities are invariably more extensive than the greyscale abnormality. High velocity low resistance flow results from the arteriovenous shunting. Magnetic resonance imaging provides non-invasive confirmation of the imaging findings.

Molar pregnancy at caesarean scar may be very dangerous for the patient, because it could result in uterine rupture, life threatening haemorrhage that may require hysterectomy. There are various modalities which may be used for management of caesarean scar site molar pregnancy, which includes dilatation and evacuation under ultrasound guidance, laparotomy or laparoscopy for local wedge excision of the trophoblastic tissue or medical management by systemic chemotherapy. Hysterectomy is usually recommended for women who have completed their childbearing, or for those with persistent chemotherapy-resistant uterine disease. However, hysterectomy may also be required in case of uterine perforation or rupture with intractable internal bleeding or due to patient's preference of definitive surgery.³

For persistent trophoblastic disease in women who opt for fertility sparing treatments, FIGO staging should be done. Women with scores ≤ 6 are at low risk and are treated with single-agent intramuscular methotrexate alternating daily with folic acid. Women with scores ≥ 7 are at high risk and are treated with intravenous multi-agent chemotherapy, which includes combinations of methotrexate, dactinomycin, etoposide, cyclophosphamide and vincristine. Treatment is continued, in all cases, until the HCG level has returned to normal and then for a further 2 consecutive cycles in high risk women requiring multi-agent chemotherapy.³ Till now there are no clear guidelines on management of cesarean site persistent trophoblastic disease. Treatment needs to be personalized depending upon size and location of the lesion, the desire for fertility, patient preferences and experience of the clinicians. The patient should be advised to avoid pregnancy for at least 1 year by using barrier or oral contraceptives as pregnancy during this time may lead to confusion.⁶

To the best of our knowledge, this is the first report of persistent trophoblastic disease at cesarean site. We demonstrated possibility of successfully treating persistent trophoblastic disease at scar site with systemic methotrexate. This case report also emphasizes on the importance of high resolution transvaginal ultrasonography and color Doppler in early pregnancy with previous cesarean scar. We reported this case to add experience that may improve the understanding of this disease and allow development of appropriate management plan in such rare presentation of molar pregnancies.

REFERENCES

1. Seow KM, Huang LW, Lin YH, Lin MY, Tsai YL, Hwang JL. Caesarean scar pregnancy: issues in management. *Ultrasound Obstet Gynaecol* 2004;23:247-253.
2. Berkowitz RS, Goldstein DP. Gestational trophoblastic disease. In: J.S. Berek, Editor. *Berek & Novac's Gynaecology*. 14th ed. Philadelphia: Lippincott Williams & Wilkins; 2007. p. 1581-1603.
3. Seckl MJ, Sebire NJ, Fisher RA, Golfier F, Massuger L, Sessa C; ESMO Guidelines Working Group. Gestational trophoblastic disease: ESMO Clinical Practice Guidelines for diagnosis, treatment and follow-up. *Ann Oncol*. 2013 Oct; 24 Suppl 6:vi39-50. doi: 10.1093/annonc/mdt345.
4. Wu CF, Hsu CY, Chen CP. Ectopic molar pregnancy in a caesarean scar. *Taiwan J Obstet Gynecol* 2006;45:343-5.

5. Shrivastava D, Bhute S, Singh A, Mukherjee S. A rare case of invasion of LSCS scar by Partial Mole. *J South Asian Fed Obstet Gynecol* 2011;3:38-9.
6. Ko JKY, Wan HL, Ngy SF, Cheung VY, Ng EHY. Cesarean scar molar pregnancy. *Obstet & Gynecol* 2012; 119: 449-51.
7. Feng-Sheng Jin, Dah-Ching Ding, Gwo-Jang Wu, KweiShuai Hwang. Molar Pregnancy in a Cesarean Section Scar of Uterus. *Journal of Med Sci* 2011;31(4):173-6.
8. Kaluarachchi CI, Tissera AJ, Gananatha Karunaratna SMG. Cesarean scar site complete molar pregnancy. *Sri Lanka Journal of Obst & Gynaecol* 2013; 35: 62-4.
9. Maymon R, Halperin R, Mendlovic S, Schneider D, Herman A. Ectopic pregnancies in a caesarean scar: review of the medical approach to an iatrogenic complication. *Human Reprod Update* 2004; 10:515-23.
10. Asseryanis E, Schurz B, Eppel W, Wenzl R, Vavra N, Husslein P. Detection of an atypical invasive mole in an ectopic pregnancy by transvaginal color-flow Doppler. *Am J Obstet Gynecol* 1993;169:1656.
11. Rumack CM, Wilson SR, Charboneau JW. Gestational trophoblastic neoplasia. In: Mosby editor. *Diagnostic ultrasound*. 2nd ed. St Louis; 1998. p.1359–1370.