

# Comprehensive Oral Rehabilitation Using Fixed Prosthesis and Implants to Manage Severe Tooth Wear

Huong CQ,<sup>1</sup> Tri PM,<sup>2</sup> Anh TH<sup>2</sup>

<sup>1</sup>Department of Prosthodontics,  
Hanoi National Hospital of Odonto-Stomatology,  
Ha Noi, Vietnam.

<sup>2</sup>Faculty of Dentistry,  
VNU University of Medicine and Pharmacy,  
Vietnam National University Hanoi, Hanoi, Vietnam.

## Corresponding Author

Chu Quynh Huong  
Department of Prosthodontics,  
Ha Noi National Hospital of Odonto-stomatology  
Hoan Kiem District, Hanoi, Vietnam.  
E-mail: Quynhhuong1234@gmail.com,  
Quynhhuong@hmu.edu.vn

## Citation

Huong CQ, Tri PM, Anh TH. Comprehensive Oral Rehabilitation Using Fixed Prosthesis and Implants to Manage Severe Tooth Wear. *Kathmandu Univ Med J.* 2025; 93(5): 119-24. (Special Issue)

## ABSTRACT

The vertical dimension of occlusion (VDO or OVD) is maintained by tooth eruption and the development of the alveolar bone. Adaptive changes in the alveolar bone compensate for occlusal wear. The loss of the Vertical Dimension of Occlusion is the result of periodontal disease, tooth wear, or trauma, thereby leading to the loss of tooth height or alveolar bone. The patient suffers from functional and aesthetic issues. This paper describes 2 cases of full-mouth rehabilitation with a severely worn dentition, with Vertical Dimension of Occlusion loss and missing teeth. Full-mouth prosthetic restoration was done in both patients, thereby improving the function and aesthetic outcome of the patients, thus highlighting the need for early intervention for repair of Vertical Dimension of Occlusion. Minimal complications were observed during the two-year follow-up in this case of severe tooth wear and posterior tooth loss. In these treatments, centric occlusal contacts on all teeth were maintained with proper anterior guidance, with functional jaw movements in harmony.

## KEY WORDS

*Dental implants, Fixed prosthesis, Oral rehabilitation, Tooth wear*

## INTRODUCTION

The loss of the Occlusal Vertical Dimension (OVD) occurs when the space between the upper and lower jaws decreases due to tooth wear, loss, or age. This loss can cause dental and facial issues that impact facial function and attractiveness. Dental occlusion problems due to OVD can flatten or sunken the lower third of the face, making the person look older or tired. Nasolabial fold may deepen, aging the face, thus requiring multiple aesthetic procedures like Botox, threading, and filler.<sup>1</sup> Loss of OVD can also make biting, speaking, and breathing difficult, thus bringing overall functional defects in the masticatory function of the jaw and related muscles.<sup>2</sup> The smaller space might strain the jaw joints, causing pain or TMJ issues that might lead the patient to visit the ENT department for otalgia.<sup>3</sup> Thus, prosthetic restoration might improve TMJ disorder.<sup>4</sup>

Many people lose vertical dimension gradually as a part of aging, making the changes difficult to notice until there is significant bone loss, reducing the height of the jaw and teeth.<sup>5</sup> As the vertical space narrows, teeth may wear down, and bite alignment may suffer. Prosthodontic intervention relies on the correction of the OVD to treat malocclusion and align teeth.<sup>6</sup> Dental prostheses like crowns, bridges, and dentures are often used to restore bite height in a patient. Restoring the OVD enhances oral function, making chewing easier and more efficient. OVD restoration improves facial attractiveness and function. Rebuilding this region restores facial harmony and youth. Deep mouth lines and folds can be minimized, and the lower face defined. Additionally, such a correction can also transform the facial outlook to look more natural. It is essential for comprehensive dental procedures, especially for patients with considerable tooth wear or tooth loss.

Appropriate vertical dimension occlusion is crucial for the long-term health and function of the oral system, not only for dental purposes, as well as preventing unnecessary economic burden on fillers and threading for facial aesthetics under the background of vertical dimension loss. Vertical compromise can cause gum recession, bone loss, and tooth wear, thus leading to various issues like gingivitis and halitosis. Regular dental checkups and appropriate treatments can detect vertical dimension loss early and allow dental intervention before further harm. Hence, OVD restoration is essential for functional and aesthetic dental care as well as reducing unnecessary periodic economic burden for aesthetic care, helping to preserve a holistic dental and aesthetic, and thereby increasing oral function and well-being.

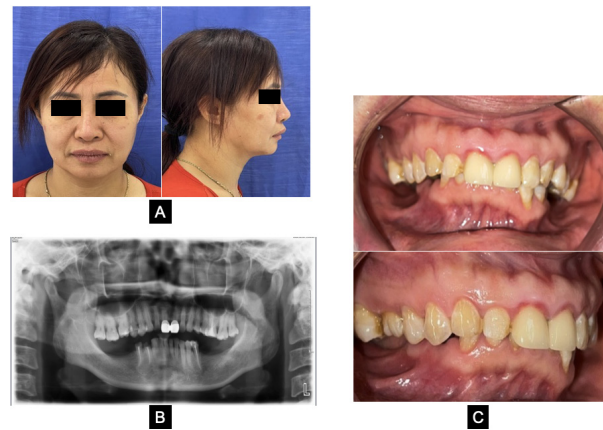
This paper presents 2 cases of full-mouth rehabilitation with a severely worn dentition, with Vertical Dimension of Occlusion (VDO) loss and missing teeth. Full-mouth prosthetic restoration was done in both patients, thereby improving the function and aesthetic outcome of the patients.

## CASE REPORT

### Case 1

#### Clinical Presentation

A 47-year-old female patient presented to the Clinic of the Prosthodontic Department at the National Hospital of Odonto-Stomatology Ha Noi with primary concerns of chewing difficulties, tooth wear, and discoloration (Fig. 1). Her patient's chief complaint was the loss of multiple lower jaw molar teeth, teeth #36, #37, #46, and #47, along with the significant vertical fracture of tooth #44, which had previously had endodontic treatment. The clinical examination revealed a notable decrease in the lower portion of the face and pronounced nasolabial folds. Upon oral examination, the maxilla was intact, with all teeth present from #18 to #28, including a porcelain bridge on teeth #11 and #21 (Fig. 1). Nonetheless, gingival irritation was observed surrounding these bridge teeth. The mandible exhibited absent molars, and teeth #35 and #45 had received endodontic therapy. The root of tooth #44 displayed a vertical fracture, necessitating extraction. The bite assessment indicated a deep bite of 100% in the front region, with inadequate interarch space in the first and second molar locations to rehabilitate the absent molars. Radiographic evaluations, including a panoramic radiograph as well as a full-mouth periapical radiograph, revealed the absence of periapical or periodontal lesions. The patient reported mild joint fatigue at the mastication region and requested repair of the lower molars and remaining teeth due to these dental concerns, but she did not report any clicking or tenderness in the temporomandibular joint



**Figure 1.** Case 1. Before treatment (female patient), frontal and lateral views of the face (A), panoramic radiograph (B), and intraoral frontal and right lateral view (C).

(TMJ).

The diagnosis verified the absence of molars #36, #37, #46, and #47, in addition to the damaged tooth #44, which necessitated extraction. Due to the deep bite and inadequate space, restoration alternatives for the missing teeth require meticulous evaluation, perhaps encompassing prosthetic rehabilitation and occlusal modifications to facilitate subsequent restorations.

#### Treatment Plan

The treatment approach was thoroughly discussed with the patient. The treatment planned was full-mouth fixed prostheses in the upper arch and posterior implants in the lower arch, followed by fixed prostheses. Initially, her existing restorations would be removed, followed by a diagnostic wax-up to determine a new VDO and prosthetic plan. Tooth #44 was planned for extraction due to its vertical fracture. A new VDO was planned to be restored in both jaws to create sufficient space for restoring molars #36, #37, #46, and #47 to improve the function and aesthetics.

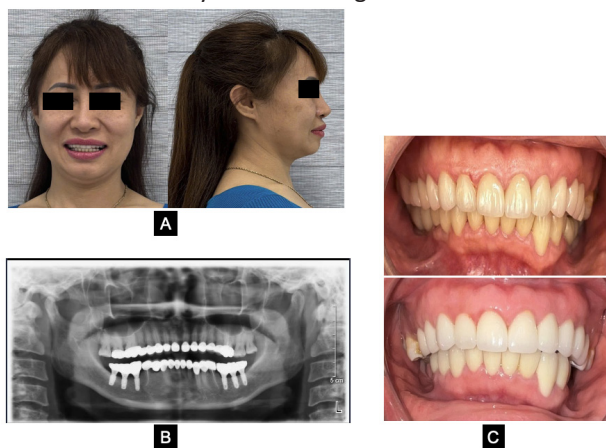#### Clinical Procedures

The treatment commenced with a hygienic phase involving oral hygiene instructions and a dental prophylaxis. An alginate upper and lower impression was made and poured models. Removable plastic denture for teeth 26, 27 on the upper jaw and for #36, #37, #46, #47 in the lower jaw according to the new vertical dimension. The OVD was increased by 4 mm.

Impression was taken to create a diagnostic wax-up, establishing a new VDO by raising a 2-3 mm height in the posterior teeth. This was translated into a direct mock-up using Bis-Acryl-resin (Luxatemp Star, DMG Fabrik GmbH, Germany), facilitating the visualization of future incisal edges, particularly on the central and lateral incisors. The patient was comfortable functionally at this new VDO and

was also pleased with her aesthetic appearance.

Once the patient approved the wax-up, a mock-up was made in the mouth. The old restorations were removed with preparation burs and provisionalization with the new prosthetic design was initiated on the upper and lower teeth with Bis-Acryl-resin (Luxatemp Star, DMG Fabrik GmbH, Germany). The provisional restorations were removed, and teeth were prepared for the tooth stump #35. The impressions were performed with the polyether impression material (DMG, Germany), using a double retraction cord technique (Ultrapak, Ultradent, USA). Shade matching was done with photographs and direct communication with the laboratory. Zirconia crowns were made on teeth #35 to #42 and a 3-unit bridge on #43 to #45 (Fig. 2). The impressions were performed with the polyether impression material (DMG, Fabrik GmbH, Germany), using a double retraction cord technique (Ultrapak, Ultradent, USA). Then, 6 implants (Dentium, South Korea) were placed guided in positions 36, 37, 38, 46, 47, 48 with 45 N insertion torque and left to heal transmucosally with a healing abutment for 8 months.



**Figure 2.** Case 1. After treatment (female patient), frontal and lateral views of the face (A), panoramic radiograph (B), and intraoral frontal and right lateral view (C).

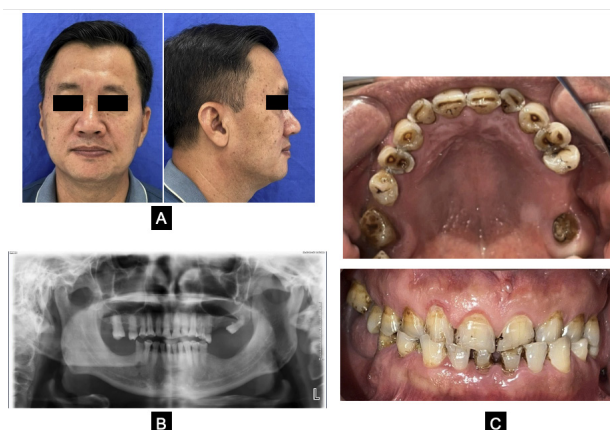
Connective tissue graft surgery increases the height of attached gingiva 46, 47. Porcelain crowns were cemented on implants 36, 37, 38, 46, 47, 48 (Fig. 2).

At the 24-month follow-up, the patient expressed high satisfaction with the integration of the restorations and the overall aesthetic improvement. The occlusion was stable, and the restorations showed good durability. Lateral contacts were intact, but there was gingivitis around teeth #12 and #13. The remaining teeth had healthy periodontal conditions. Aesthetically, the results were pleasing, and the patient's pronunciation was normal. The patient reported improved chewing function and expressed satisfaction.

## Case 2

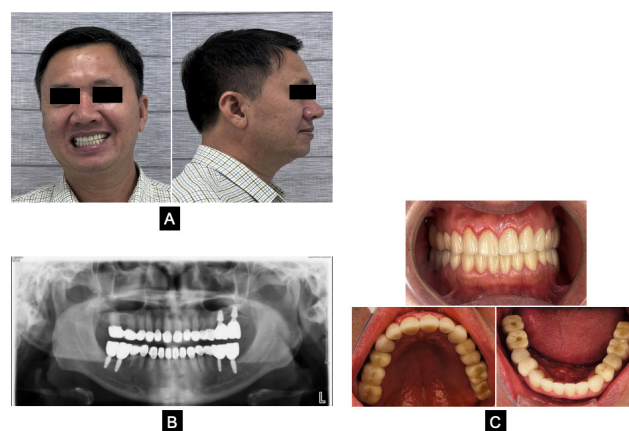
### Clinical Presentation

A 54-year-old male patient reported to the Prosthodontic Department Clinic for a check-up with a chief complaint of difficulty in chewing due to short teeth, eating difficulty due to significant tooth wear, and the loss of several



**Figure 3.** Case 2. Before treatment (male patient), frontal and lateral views of the face (A), panoramic radiograph (B), and intraoral frontal and right lateral view (C).

molars in both the upper and lower jaws, and poor facial appearance (Fig. 3). The patient presented with a flat lower facial third, deep nasolabial folds, and slight deviation of the lower lip and chin to the left. During the consultation, the patient's medical history was reviewed and recorded. The patient reported nighttime bruxism during periods of stress. Extraoral examination revealed muscle and temporomandibular joint pain. The upper jaw revealed the loss of teeth #16, #26, and #27, with heavily worn incisors and premolars exposing dentin and pulp. Tooth #28 was tilted approx. 90 degrees. The lower jaw exhibited the loss of teeth #36, #37, #46, and #47, with tooth #45 showing periapical inflammation (Fig. 4). The incisors and premolars were also severely worn, exposing dentin and pulp. Certain phonemes, such as "s" were mispronounced as "x," indicating a correlation with incisor length. Additionally, teeth #41 and #45 had chronic periapical inflammation. The bite showed a reduced vertical dimension, with end-to-end occlusion and pulling bites in the incisor and premolar regions. There was insufficient interarch space for restoring the missing teeth.



**Figure 4.** Case 2. After treatment (male patient), frontal and lateral views of the face (A), panoramic radiograph (B), and intraoral frontal view, upper arch and lower arch (C).

It indicated that the patient had lost several molars and had chronic periapical inflammation in certain teeth. The occlusion was compromised due to significant wear on

both the upper and lower teeth, and there was insufficient space for restoration. The patient desired treatment to restore both chewing function and aesthetics.

#### Treatment Plan

The treatment approach was thoroughly discussed with the patient. The treatment planned was full-mouth fixed prostheses in the upper arch and posterior implants in the lower arch, followed by fixed prostheses. The treatment method was discussed with the patient after a step-by-step explanation of the process. The patient's maxillary and mandibular data were recorded using the ProArch II facebow and bite fork to determine the new vertical dimension for restoration of anterior teeth, molar spaces, function, and aesthetics. The OVD of the bite was decided to increase after assessing the above factors.

The treatment plan included endodontic treatment for teeth #41 and #45, restoration of tooth #45 with a quartz post and composite core, extraction of tooth 28, and restoration of the vertical dimension of occlusion in both jaws to create adequate inter-arch space for the restoration of teeth #26, #27, #36, #37, #46, and #47. Following this, the upper and lower molars will be restored, with aesthetic improvements and occlusion adjustments.

#### Clinical Procedures

An alginate upper and lower impression was made, and models were poured. Removable plastic denture for teeth 26, 27 on the upper jaw and for #36, #37, #46, #47 in the lower jaw according to the new vertical dimension. The OVD was increased by 4 mm. A wax mock-up was done in the mouth to check the shape of the teeth, facial aesthetics, occlusal height, and the relationship between the two jaws.

Then, tooth preparation was done on teeth #15 to #25, and #16 in the upper arch for a porcelain crown. The impression was performed with the polyether impression material (DMG, Fabrik GmbH, Germany), using a double retraction cord technique (Ultrapak, Ultradent, USA). Similarly, tooth preparation was done in all teeth from 35-45 in the lower arch. The impressions were performed with the polyether impression material (DMG, Germany), using a double retraction cord technique (Ultrapak, Ultradent, USA). Information for the lab about the mock-up sample in the mouth. The finished crowns were cemented.

Extraction was done for tooth #28. Then, dental implants were placed for teeth #26 and #27 with sinus lift, bone graft. Implant placement for teeth #36, #37, #46, and #47. Implant-supported crowns were delivered on implants #26, #27, #36, #37, #46 and #47. The patient has an aesthetic appearance, normal pronunciation, and good chewing ability. The restorations are durable, but there was gum inflammation around the neck area of teeth #11, #12, and #13.

## DISCUSSION

Tooth wear is a multifactorial condition. In this patient, the primary causes were the prolonged absence of posterior molars without prosthetic restoration, a crossbite occlusion pattern, and nighttime bruxism due to stress, which all contributed to severe dental abrasion. This wear negatively affected occlusion, resulting in the loss of anterior and lateral guidance. The absence of posterior teeth further exacerbated the problem. Facial appearance was altered, speech was affected, and the VDO was reduced. Thus, the treatment approach focused on restoring both function and esthetics, while simultaneously creating space for posterior rehabilitation by increasing the VDO. In this case, the VDO was increased using an occlusal splint. The patient was closely monitored for function, occlusion, esthetics, and phonetics throughout the treatment. No discomfort was reported during the adaptation to the new VDO.

VDO loss is one of the common dental issues, but often ignored among the general population. Such neglected vertical dimension loss has created functional damage and aesthetic disfigurement will ultimately lead the patient to seek dental care. Although it's a normal phenomenon at older age but unpredictable and premature vertical dimension loss of the jaw and teeth should be considered as a part of dental treatment at the earliest stage.<sup>5</sup>

Many pathological diseases in the oral cavity are responsible for the wear and tear of the facial bony structures, such as gingivitis, periodontitis, attrition, and tooth decay, etc.<sup>7-9</sup> Although the vertical dimension loss of the bony process is a gradual process but the ongoing pathological process leads to visible and premature loss of bony structures as seen in our case.<sup>10</sup> The loss of such bony structures will lead to the compensatory functional use of other remaining healthy structures. This creates unnecessary wrinkles and fine lines, as seen in our patient.<sup>8</sup> Similarly, such cases have also raised economic burden on filler, botox, and threading for aesthetics. Another important complication that might arise is excessive fatigue and exhaustion due to overuse of the muscle as the compensatory role of other muscles. This causes significant impairment of daily activities as well as sleep problems and psychological discomfort.<sup>11-13</sup> Besides, the loss of posterior molar teeth leads to unnecessary occlusion of bony structures, thus leading to excessive pressure at the TMJ joint, and this becomes one of the prominent reasons for a dentist visit, as seen in the first case.<sup>14</sup> There are some reported cases where the tension at the joint has led to the referred otalgia, thus directing the patient towards other departments, especially ENT.<sup>15</sup>

Another noteworthy complication that arises due to OVD loss, as seen in our second patient, is the development of an unnecessary deep nasolabial fold and deviation of the lip and chin.<sup>8</sup> It highlights the impact of the longitudinal loss on facial and jaw muscles, thus impairing the facial outlook. This leads to functional loss of the jaw muscles

due to disproportionate articulation and malocclusion, like pronunciation defects, speech problems, chewing, eating, etc.<sup>16</sup> The articulation defect, as seen in the first patient, has caused problems during mastication, as seen in previous studies.<sup>17,18</sup> The comfort felt by the patient while chewing after the restoration of vertical dimensional loss in our patient has highlighted the importance of the timely repair of longitudinal dimensional loss. The resolution of gingival health, controlling the halitosis, and boosting the overall oral hygiene after treatment with dental implants for vertical dimension loss has helped to restore significant functional rehabilitation in our two patients.

The treatment of the entire dentition in patients with reduced tooth wear and loss of OVD is a complex and multifactorial challenge that requires a multidisciplinary approach to ensure long-term success. In case, the patient had lost posterior teeth for a long time without a prosthesis, leading to loss of vertical dimension of the occlusion and tooth wear, combined with the Class II occlusal relationship between the two jaws, resulting in a deeper bite.<sup>1</sup> In this case, several important clinical considerations were considered in determining the treatment plan, including preservation of tooth structure, tooth preparation, and preparation of the implant space for the lower molars. Restoration of the VDO of the bite is very important for this patient because it shows tooth wear and tooth loss leading to loss of vertical dimension, an increase in the vertical dimension of the bite is expected to be 2-3 mm, which is appropriate and not excessive, which will overload the teeth and cause damage to the teeth, and enough space for the posterior teeth is considered an acceptable increase, which allows the placement of new restorative materials that can withstand the bite force when restoring function and aesthetics for the patient. In this case, the material chosen is zirconia to restore and increase the VDO of the bite of both jaws. During the restoration process, a removable plastic denture must be used for the lower posterior teeth to support the increase in VDO of the bite. Re-establish the

bite contact in the anterior teeth, with incisor guidance and group guidance. To establish the bite of the molars, because not increasing the vertical dimension too much will affect the aesthetics and temporomandibular joint, a crown was restored for tooth #17, and #18, #27, and #28 were ground. After 2 years of follow-up, the patient has occlusal stability, durability of the restoration, and satisfaction with the aesthetic and functional results. There is only a gingival margin on teeth #11 and #11, so the patient needs to be scheduled for a 6-month follow-up for oral hygiene and periodontal treatment.

Full-contour zirconia crowns were used for the final restorations due to their natural translucency and high durability in both cases. The anterior teeth achieved ideal overjet and overbite relationships, while posterior occlusion was supported by implant-retained restorations on both arches. After the restorative phase, a protective night guard was fabricated to prevent further damage during sleep.

Thus, it is highly recommended for every individual to understand the functional and aesthetic defect due to the vertical dimension loss. This study highlights the timely dental intervention required for the restoration of the longitudinal dimension loss to improve dental hygiene, functional rehabilitation, and the facial outlook.

Restorative treatment for patients with severe tooth wear and posterior tooth loss requires a carefully planned and precisely executed protocol. Any increase in vertical dimension must be followed by regular checkups to assess functional outcomes, esthetic appearance, oral health, and crown longevity. After thorough diagnostic planning and the application of advanced prosthetic techniques through sequential restorative procedures combining bridges, crowns, and implants, an increase in vertical dimension was successfully achieved. Long-term follow-up is essential in this patient's case because there is a bridge, crown, and implant to monitor the stability of the restoration and the periodontium.

## REFERENCES

1. Moon H, Fundaro SP, Goh CL, Hau KC, Paz-Lao P, Salti G. A Review on the Combined Use of Soft Tissue Filler, Suspension Threads, and Botulinum Toxin for Facial Rejuvenation. *J Cutan Aesthet Surg*. 2021 Apr-Jun;14(2):147-55. doi: 10.4103/JCAS.JCAS\_119\_20. PMID: 34566355; PMCID: PMC8423215.
2. Paradowska-Stolarz AM. Is malocclusion a risk factor for obstructive sleep apnea and temporomandibular disorders? An orthodontic point of view. *Dent Med Probl*. 2025 Mar-Apr;62(2):197-9. doi: 10.17219/dmp/194232. PMID: 40249025.
3. Coulter J, Hohman MH, Kwon E. Otagia. StatPearls. Treasure Island (FL): StatPearls Publishing Copyright © 2025, Stat Pearls Publishing LLC. 2025.
4. Caldas W, Conti AC, Janson G, Conti PC. Occlusal changes secondary to temporomandibular joint conditions: a critical review and implications for clinical practice. *J Appl Oral Sci*. 2016 Jul-Aug;24(4):411-9. doi: 10.1590/1678-775720150295. PMID: 27556214; PMCID: PMC4990372.
5. Mendelson B, Wong CH. Changes in the facial skeleton with aging: implications and clinical applications in facial rejuvenation. *Aesthetic Plast Surg*. 2012 Aug;36(4):753-60. doi: 10.1007/s00266-012-9904-3. Epub 2012 May 12. PMID: 22580543; PMCID: PMC3404279.
6. Fueki K, Kimoto K, Ogawa T, Garrett NR. Effect of implant-supported or retained dentures on masticatory performance: a systematic review. *J Prosthet Dent*. 2007 Dec;98(6):470-7. doi: 10.1016/S0022-3913(07)60147-4. PMID: 18061741.
7. Lang NP, Schätzle MA, Löe H. Gingivitis as a risk factor in periodontal disease. *J Clin Periodontol*. 2009 Jul;36 Suppl 10:3-8. doi: 10.1111/j.1600-051X.2009.01415.x. PMID: 19432625.
8. Lee W, Jung KH. Changes in the Face Related to Aging Process. *Lifting Techniques in Plastic Surgery: A Practical Guide on Thread Lifting, Mini-Lifting and Rhytidectomy*: Springer 2025:25-34.
9. Sperber GH. Dental Wear: Attrition, Erosion, and Abrasion-A Palaeo-Odontological Approach. *Dent J (Basel)*. 2017 Jun 17;5(2):19. doi: 10.3390/dj5020019. PMID: 29563425; PMCID: PMC5806976.

10. Martínez-Maestre MÁ, González-Cejudo C, Machuca G, Torrejón R, Castelo-Branco C. Periodontitis and osteoporosis: a systematic review. *Climacteric*. 2010 Dec;13(6):523-9. doi: 10.3109/13697137.2010.500749. Epub 2010 Aug 7. PMID: 20690866.
11. Surendran A, Daigavane P, Shrivastav S, Kamble R, Sanchla AD, Bharti L, et al. Comparative Evaluation and Correlation of Hyoid Bone Position, Airway Dimension, and Psychological Status in Class II Vertical and Horizontal Malocclusion Cases With Temporomandibular Disorder Compared to Class I Non-Temporomandibular Disorder Cases. *Cureus*. 2024 Sep 4;16(9):e68648. doi: 10.7759/cureus.68648. PMID: 39371831; PMCID: PMC11451583.
12. Alsulaiman OA, Alghannam MI, Almazroua DM, Alamri AS, Shahin SY, Nassar EA, et al. Mental Health and Malocclusion: A Comprehensive Review. *Clin Pract*. 2025 Feb 24;15(3):44. doi: 10.3390/clinpract15030044. PMID: 40136580; PMCID: PMC11941310.
13. Skallevoid HE, Rokaya N, Wongsirichat N, Rokaya D. Importance of oral health in mental health disorders: An updated review. *J Oral Biol Craniofac Res*. 2023 Sep-Oct;13(5):544-552. doi: 10.1016/j.jobcr.2023.06.003. Epub 2023 Jun 19. Erratum in: *J Oral Biol Craniofac Res*. 2024 Jul-Aug;14(4):353-354. doi: 10.1016/j.jobcr.2024.05.011. PMID: 37396968; PMCID: PMC10314291.
14. Lekaviciute R, Kriauciunas A. Relationship Between Occlusal Factors and Temporomandibular Disorders: A Systematic Literature Review. *Cureus*. 2024 Feb 13;16(2):e54130. doi: 10.7759/cureus.54130. PMID: 38487145; PMCID: PMC10939299.
15. Petrides GA, Fadhil M, Meller C. Otalgia from temporomandibular disorder in Ear, Nose and Throat surgery: a literature review and diagnostic algorithm. *Aust J Otolaryngol*. 2024;7.
16. Oliver S, Keyser MMB, Jhingree S, Bocklage C, Lathrop H, Giduz N, Moss K, Blakey G, White R, Turvey T, Mielke J, Zajac D, Jacox LA. Impacts of anterior-posterior jaw disproportions on speech of dentofacial disharmony patients. *Eur J Orthod*. 2023 Feb 10;45(1):1-10. doi: 10.1093/ejo/cjac057. PMID: 36308520; PMCID: PMC9912703.
17. Shetty B, Khan SF, Irfana K, Nambiar M. Effect of osseous defect on periodontal ligament stress under normal masticatory force: A three-dimensional finite element analysis of mandibular second molar. *J Indian Soc Periodontol*. 2024 Nov-Dec;28(6):691-696. doi: 10.4103/jisp.jisp\_98\_24. Epub 2025 Apr 3. PMID: 40313345; PMCID: PMC12043224.
18. Fayad MI. A Literature Review of Vertical Dimension in Prosthodontics Theory and Practice - Part 1: Theoretical Foundations. *Cureus*. 2024 Jun 7;16(6):e61903. doi: 10.7759/cureus.61903. PMID: 38855484; PMCID: PMC11161034.