

Upper GI Endoscopy in Children- in an adult suite

Joshi MR¹, Sharma SK², Baral MR³

¹Lecturer, ²Associate Professor, Department of Surgery, ³Professor, Department of Paediatrics, Kathmandu Teaching Hospital, Sinamangal, Kathmandu

Abstract

Although Upper GI endoscopy is commonly performed in adults, paediatric endoscopy is not available in many of our referral centres. The efficacy and safety of upper GI endoscopy in paediatric age group performed in adult suite of Kathmandu Medical College is reviewed. **Patients and Method:** A retrospective study of endoscopies performed on children aged up to 15 years in an adult endoscopy suite of Kathmandu medical college over last one year is presented. All cases were the referred cases from paediatric unit for various problems. **Results:** Endoscopy in paediatric group comprises only 6% of total upper GI endoscopies performed during the same year. Sex ratio was almost equal. Most cases (87%) were performed under local anaesthetic and well tolerated by the patients. Recurrent abdominal pain (RAP) was the commonest indication and among them one third of cases had significant positive finding. **Conclusion:** Upper GI endoscopy is a useful diagnostic tool in children. Where specialized paediatric endoscopy units are not feasible i.e. developing countries, endoscopic services to children can be safely provided in adult endoscopy suite with or without sedation. Upper GI endoscopy is well tolerated by children even without sedation.

Key words: Endoscopy, Recurrent abdominal pain.

Modern gastroenterology began with Bozzini's crude, candle-powered *lichtleiter* in 1805 and blossomed with the introduction of flexible gastrointestinal endoscopy by Hirschowitz in the late 1950s. Paediatric gastroenterology followed soon after.

Fuelled by the application of gastrointestinal endoscopy to childhood digestive disease, paediatric gastroenterology has emerged as one of the most diverse medical-surgical practices in modern medicine¹. The first accounts of flexible gastrointestinal endoscopy in children appeared in the 1970s^{2,3,4,5,6,7,8}

In 1972, Freeman, British paediatric surgeon, reported using the fibre-optic bronchoscope for examination of the upper gastrointestinal tract in children and noted, "the need for paediatric endoscopy is well established and the indications will likely increase". Early accounts of paediatric endoscopy stressed identification of superficial lesions not seen on radiographic contrast studies, and specific causes of upper gastrointestinal bleeding^{3,4}. In 1977, Ament and Christie declared upper gastrointestinal fibre-optic endoscopy "one of the major diagnostic advances in paediatric gastroenterology in this decade"³.

Much difficulty is often encountered in finding the underlying cause of abdominal pain. Clinical features may vary from one patient to other and occasionally from one episode to the next even in the same child. The

recent development of fibre-optic endoscopy may well prove to have a useful diagnostic technique, particularly in those children in whom other investigations are inclusive¹. Esophagogastroduodenoscopy (EGD) is a well established diagnostic and therapeutic procedure in paediatric patients¹. In contrast to the experience in the adults, there are limited data concerning efficacy and safety of upper GI endoscopy in paediatric patients. The information on this procedure is very scanty from non western countries¹.

We have analyzed our experience of upper GI endoscopy in paediatric age group in one year.

Patient and Method

This is a retrospective review of the total cases of upper GI endoscopy performed in children under the age 15 years during one year (Aug, 2003 to Aug, 2004) in the department of surgery, Kathmandu medical college teaching Hospital (KMCTH). Data were taken from the record section of endoscopy unit. All children were referred cases from paediatric unit of the same hospital. The need and indication of UGI endoscopy was determined by paediatrician. Most of the cases were referred for recurrent abdominal pain (RAP).

Correspondence

Dr. Mukund raj Joshi.

GPO Box: 9843.

E-mail: mukundrajjoshi@yahoo.com

Recurrent abdominal pain (RAP) is usually defined as three or more bouts of abdominal pain for more than 3 months, and severe enough to affect the daily life of the child. After receiving the child in the endoscopy unit, both the child and parents were informed about the procedure in detail and its possible complications. Informed consent was taken from parents and they were asked to stay with the child till the end of procedure.

The policy was to try each case under local anaesthetic i.e. 4% lignocaine pharyngeal spray. The children who were uncooperative and in whom endoscopy could not be performed were asked to come for next attempt to be performed under general anaesthesia or intravenous sedation. Those were performed under intravenous Ketamine given by anaesthetic team. The endoscope used was 9mm diameter Fuzinon adult video-endoscope by trained endoscopist. Endoscopic findings were recorded. No any therapeutic procedures were performed in any case. Biopsy was taken according to need, decided by endoscopist. After the procedure, babies were sent back to paediatrician with endoscopic diagnosis. Follow up endoscopies performed during the same period were excluded from the study.

Age, sex and clinical indications were tabulated. Endoscopic diagnosis was correlated and compared with clinical indication. Need of IV sedation or general anaesthetic to complete the procedure is discussed. SPSS 11.5 software was used for statistical analysis.

Result

During the period (Aug, 2003 to Aug, 2004), 519 endoscopies were performed at endoscopy unit of Kathmandu medical college teaching hospital (KMCTH). Of them, 31(6%) cases were of under 15years of age. Mean age 11.5 ± 2.71 SD. Lowest age was 7years. Fig.1 shows the age distribution. Male and females were almost equal. (Fig-2).

Figure 1 Age distribution

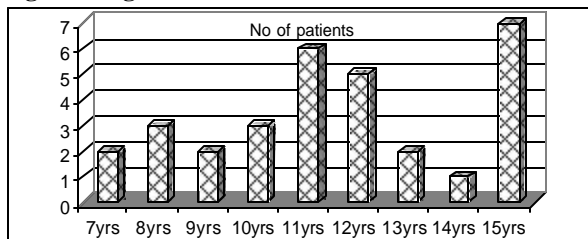
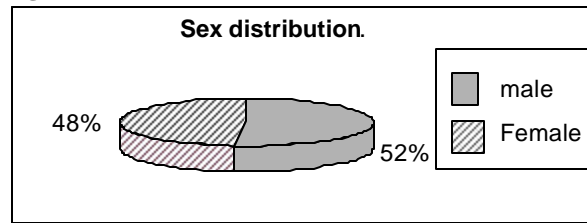


Figure 2 Sex distribution



Most common indication for endoscopy was recurrent abdominal pain (84%), others were vomiting, dysphagia, hematemesis etc. (Table. 1). Out of 26 cases of recurrent abdominal pain, 8 cases (30%) had significant positive finding in endoscopic examination. Endoscopic finding has been summarized in table 2 Although, sixty-two percent cases had normal endoscopy, there was a significant correlation between indication and positive findings ($P=0.04$). The endoscopic diagnosis with regards to age group is found to be statistically insignificant ($P=0.492$). There were four cases of duodenal ulcer of 12-15 years age group. They received triple therapy empirically. Remaining 18 (66%) cases with normal finding were sent back to paediatrician for further evaluation of abdominal pain. No any complication was encountered during the procedure.

Table 1. Indications for endoscopy.

Indications	No of cases	Positive findings
Recurrent abdominal pain	26 (84%)	8
Repeated vomiting	3 (10%)	3
Dysphagia	1 (3%)	0
Hematemesis	1 (3%)	1

Table 2. Endoscopic diagnosis.

Normal	19(62%)
Gastritis	5(16%)
Duodenal ulcer	4(13%)
Reflux oesophagitis	1(3%)
Hiatus Hernia	1(3%)
Bile reflux	1(3%)

Regarding the need of sedation, 26 children tolerated the procedure with local anaesthetic spray. Four children needed general anaesthetic. Two of them were in initial days when the procedure was first started in institute when all paediatric endoscopy were performed under IV ketamine. Three of those four children were above 10yrs of age. Most of children who tolerated the procedure under tropical anaesthetic were under 10 age group however the relation is statistically insignificant ($P=0.739$). Intravenous sedation whether conscious or

deep sedation was not employed in any of the cases. In all most all cases, the procedure could be accomplished in first attempt which is very significant (P=0.00). Out of 31 cases, only two children were very intolerable to procedure and needed second attempt under general anaesthetic. (Table 3).

Table 3. Anaesthesia needed for the procedure according to age.

Anaesthesia	Age	
	<10yr	>10yr
General anaesthetic (4)	1	3
Local anaesthetic (27)	9	18

Discussion

Abdominal pain is a common gastrointestinal symptom in children¹. The entity recurrent abdominal pain in children was first described by Apley and Naish in 1958. Recurrent abdominal pain is usually defined as three or more bouts of abdominal pain for more than 3 months, and severe enough to affect the daily life of the child. The incidence found in their community based study was 10.8% and the majority of cases were diagnosed as non-organic². The most challenging task for the clinician seeing a child with recurrent abdominal pain is to determine whether a specific organic cause may be present and what the most appropriate investigations to be undertaken should be². Croffie et al further confirmed that most children with recurrent abdominal pain had a functional disorder and suggested that cost-effectiveness evaluations should be carefully considered². With the advent of paediatric endoscopy and motility studies, more studies have reported organic causes of recurrent abdominal pain². The prevalence of organic disease responsible for the pain has ranged from less than 10% to more than 50%². Our study has shown that the most common cause for referral is recurrent abdominal pain (88%). Approximately 33% of the cases with recurrent abdominal pain had endoscopically diagnosed positive findings. This is quite comparable with other studies.

Most of the endoscopic studies were found to be normal (66%). Other diagnosis were Gastritis (16%), Duodenal ulcer (13%), Reflux oesophagitis (3%), Hiatus hernia (3%) and bile reflux (3%). The higher incidence of normal finding is probably because routine biopsy was not performed in all cases. The endoscopic evaluation may be considered deficient on many occasions if not accompanied by histopathologic evaluation where as the endoscopist is frequently criticized for performing biopsies in situation where the gross mucosal appearance is described as normal¹⁰. In 1983, Biller et

al², reported a poor correlation of endoscopy and histology for the oesophageal mucosa in children in a retrospective review with only 45% true-positive and as high as 30% false-positive case. The correlation of gastric mucosal endoscopy and histology was also reported to be quite limited by Sauerbruch et al².

Although safe, EGD has the potential for complication, in particular cardiopulmonary abnormalities associated with intravenous sedation. EGD is often performed in adults without sedation. It was recently suggested that, even though adult patients have a clear preference for receiving sedation, consideration should be given to abandoning its routine use in the interests of safety². Unsedated EGD is occasionally performed in children but not been subjected to study². There are no detailed protocols available for endoscopic sedation that have gained widespread acceptance. Published articles focusing on the practical aspects of paediatric endoscopy avoid precise recommendations with regard to sedation. The endoscopy can be performed reasonably satisfactorily in many children using a midazolam/pethidine regimen, but that as we had anticipated the sedative doses required were much greater than those recommended by the drug manufacturers and by other authorities^{2,3,4}. Intravenous sedation is hazardous in children as the therapeutic margin between sedation and anaesthesia is very narrow. In view of this, it should be administered only under very special circumstances². This study has shown that endoscopy could be carried out in most of the children with tropical pharyngeal anaesthesia only and almost all of them had undergone procedure in first attempt. Only four children needed general anaesthetic and three of them were above age 10. This was too in initial days when the procedure was first started in institute. This could be possible probably because of good counselling of the children and their parents before and during the procedure. Only a few of them were apprehensive where as most of them had tolerated the procedure well without any complication. There have been some similar reports from other centres. Bishop et al, "Unsedated EGD can be performed safely and successfully in children with good patient tolerance. There was a significant decrease in total procedure time for children who have unsedated EGD. Unsedated EGD should be considered a viable option for motivated children."²¹ Zahavi I et al, "Upper gastrointestinal endoscopy with or without sedation is a safe and effective diagnostic procedure in the paediatric age group"².

In the present study, we have used the available 9mm adult video-endoscope which we found to be well tolerated by the children. Almost all of them except two were successfully and completely examined in first

attempt ($P < 0.05$). All of our patients were above 7yrs of age. Doing endoscopy in an adult unit is a new experience to us although there are similar reports. Peter et al, 'Paediatric endoscopy is simple with appropriate instruments and preparation; examination techniques are similar to those used in adults. The standard adult forward- and lateral- viewing instruments (10-12mm diameter) can be used down to the age of about 2 years. Smaller paediatric instruments (5mm diameter) may be needed in infants'²

Conclusion

Abdominal pain is a common problem in children and significantly associated with positive organic finding so upper GI endoscopy is a valuable and essential diagnostic procedure. Where specialized paediatric units are not feasible, e.g. developing countries, endoscopic services to children can be safely provided in an adult endoscopy unit without sedation, provided that the necessary modifications to meet the medical and psychological needs of children and their parents are taken into consideration.

Acknowledgements

We would like to acknowledge our sincere thanks to the department of surgery, department of paediatrics, department of anaesthesiology and endoscopy unit of Kathmandu medical college for active participation and College administration for continuous support.

Reference

1. Mark A. Gilger. Gastroenterologic endoscopy in children: past, present and future. *Current opinion in Pediatrics* 2001, 13:429-434.
2. Freeman NV: Clinical evaluation of the fiberoptic bronchoscope (Olympus BF5B for paediatric endoscopy. *J Pediatr Surg* 1973, 8:213-220.
3. Ament ME, Christie DL: Upper gastrointestinal fiberoptic endoscopy in paediatric patients. *Gastroenterology* 1977, 72: 1244-1246.
4. Gleason WA, Tedesco FJ, Keating JP, et al.: Fiberoptic gastrointestinal endoscopy in infants and children. *J pediatr* 1974, 85: 810-813.
5. Cotton PB: Fiberendoscopy and the barium meal: results and implications. *BMJ* 1973, 2:161-165.
6. Pepp JP: Endoscopic experience in 100 consecutive cases with the Olympus GIG endoscope. *Am J Gastroenterol.* 1973, 60: 466.
7. Cremer M, Peeters JP, Emonts P, et al: Fiberendoscopy of the gastrointestinal tract in children: experience with newly designed fiberscopes. *Endoscopy* 1974, 6: 186-189.
8. Graham DY, Klish WJ, Ferry GD, et al.: The value of fiberoptic gastrointestinal endoscopy in infants and children. *South Med J* 1978, 24: 298-301.
9. Soeparto P. Endoscopic examination in children with recurrent abdominal pain. *Paediatric Indones.* 1989 Nov-Dec; 29(11):221-7.
10. Dahshan A, Rabah R. Correlation of endoscopy and histology in the gastroesophageal mucosa in children: are routine biopsies justified? *J Clin Gastroenterology.* 2000 Oct; 31(3): 213-6.
11. Ayoola EA, Nanda VJ, Gadour MO, Dlamini AK. Upper gastrointestinal disease in Saudi Arabian children. *Trop Gastroenterol.* 1999 Jul-Sep; 20(3): 137-9.
12. Quak SH, Low PS, Wong HB. Upper gastrointestinal endoscopy in children with abdominal pain. *Ann Acad Med Singapore,* 1985 Oct; 14(4): 614-6.
13. Apley J, Naish N. Recurrent abdominal pains: a field survey of 1000 school children. *Arch dis Child* 1958; 33: 165-70.
14. Thiessen PN. Recurrent abdominal pain. *Pediatr Rev* 2002; 23: 39-45.
15. Croffie JM, Fitzgerald JF, Chong SKF. Recurrent abdominal pain in children- a prospective study of outcome in a group referred to a paediatric gastroenterology practice. *Clin pediatr* 2000; 39:267-74.
16. Ukarapol N, Iertprasertsulk N, Wongasawasdi L. Recurrent abdominal pain in children: the utility of upper endoscopy and histopathology. *Singapore medical J* 2004; 45(3): 121-124.
17. Stordal K, Nygaard EA and Bentsen B. Organic abnormalities in recurrent abdominal pain in children. *Acta Paediatr* 90: 638-642.
18. Biller J, Winter H, Grand R, et al. Are endoscopic changes predictive of histologic esophagitis in children? *J pediatr* 1983;103:215-8.
19. Sauerbruch T, Scheriber M, Schussler P, et al. Endoscopy in the diagnosis of gastritis, diagnostic value of endoscopic criteria in relation to the histologic diagnosis. *Endoscopy* 1984; 16:101-4.
20. Colin-Jones DG. Improving the standards of endoscopy. *Gut* 1991; 32: 725-6.
21. Bishop PR, Nowicki MJ, May WL, Elkin D, Parker PH. Unsedated upper endoscopy in children. *Gastrointest Endosc.* 2002 May; 55(6): 624-30.
22. Murphy M Stephen. Sedation for invasive procedures in paediatrics; *Archives of Disease in childhood* 1997; 77:281-286.
23. British Medical Association, Royal Pharmaceutical Society of Great Britain. *British national formulary.* London: Pharmaceutical Press, 1997.
24. Insley J, ed. Prescribing. *A Paediatric vademecum.* 13th Ed. London: Arnold, 1996.
25. Royal College of Surgeons of England. Commission on the provision of surgical services. *Report of the working party on guidelines for sedation by non-anaesthetists.* London: Royal college of Surgeons, 1993.
26. Zahavi I, Arnon R, Ovaida B, Rosenbach Y, Hirsch A, Dinari G. Upper gastrointestinal endoscopy in the paediatric patient. *Isr J Med Sci.* 1994 Aug; 30(8): 664-7.
27. Peter B. cotton, Christopher B. williams. *Practical Gastrointestinal Endoscopy: The fundamentals;* 4th edition 1996, Blackwell Publishing:28.