

## Cervical necrotizing fasciitis in an uncontrolled type II diabetic patient

Singh RK<sup>1</sup>, Bhandary S<sup>2</sup>, Wakode PT<sup>3</sup>, Karki P<sup>4</sup>

<sup>1</sup>Assistant Professor, <sup>2</sup>Associate Professor, <sup>3</sup>Professor, Department of Otolaryngology Head and Neck Surgery,

<sup>4</sup>Professors, Department of Medicine, BP Koirala Institute of Health Science, Dharan, Nepal

---

### Abstract

We report a case of cervical necrotizing fasciitis (CNF) in a female having uncontrolled type II diabetes mellitus. The patient was presented to us after 20 days of preliminary symptoms. The aetiology of microbial inoculation in subdermal tissue was not known. The isolate was *Staphylococcus aureus*. In spite of the delay in presentation, the patient was successfully treated with combined antimicrobial and surgical intervention.

**Key words:** Necrotizing fasciitis, head and neck, cervical, diabetes mellitus.

---

Necrotizing fasciitis (NF) is an infrequent, rather fatal, rapidly progressive infection of soft tissue characterized by widespread necrosis of the superficial fascia with undermining of the subcutaneous tissue and gangrene of the skin. The suppressed immunity plays an important role in determining the initiation, progression, and outcomes of the disease.<sup>1</sup> The head and neck NF is usually monomicrobial, however, the polymicrobial culture is not uncommon.<sup>2</sup> Clinical diagnosis poses its own importance because any delay in diagnosis and intervention directly affect the prognosis of the patient. However, poor economical condition, delays in referral, long distance to the tertiary hospital were the main problems patients had to face with.<sup>3</sup>

We present an extremely rare case of cervical NF in type II diabetic female caused by *Staphylococcus aureus* and the literature is briefly reviewed.

### Case report

A 37-year-old female was admitted to the Department of Otolaryngology with a 15 days history of discharging large wound on the nape of neck. Twenty days back she had noticed a small painful lump on the back of the right side of neck. The swelling initially increased in size with appearance of a localised area of black discoloration of overlying skin on the next two days. The patient denied any knowledge of antecedent trauma. On the following days the localised discoloured skin sloughed out to make large wound with plenty of purulent discharge. During these periods she seeks advice from some local practitioner but without any relief.

At last she came to us for the further management. Our initial evaluation of wound revealed two separate ulcers with a small area of healthy looking skin in between two. The larger ulcer was 10 cm X 4cm in size, with loss of skin and subcutaneous tissue, exposing underneath muscles, while smaller wound was 4cm X 3cm in size with similar characters. The pocket of pus was along the subcutaneous plain up to 10 cm in back and 8 cm in lateral neck up to clavicle (Photo.1A-B). No separate lymph node was palpable in neck or anywhere in body. Rest of the ear nose and throat examinations were found within normal limit.

She had type II diabetes mellitus for the last 6 years, on treatment with Metformin. There was no other significant past history. On examination she was non-toxic, afebrile (37°C), with a heart rate of 90/min and blood pressure of 110/76mm of Hg. Other systemic examination was unremarkable.

Investigations showed haemoglobin of 9.9g/dl, white cell count  $16.9 \times 10^3 \text{ mm}^{-3}$  (Neutrophil 67%, lymphocyte 32% and monocyte 1%) and platelet count  $422 \times 10^3 \text{ mm}^{-3}$ . Biochemistry results were fasting glucose 343mg/dl, blood urea 13mg/dl, serum creatinine .7mg/dl, serum sodium 132mmol/Liter, and potassium 4.7 mmol/Liter.

---

### Correspondence

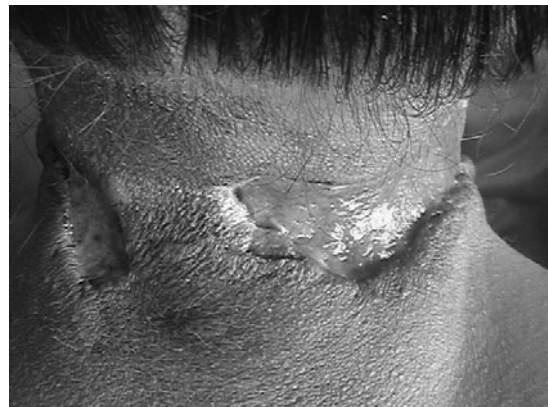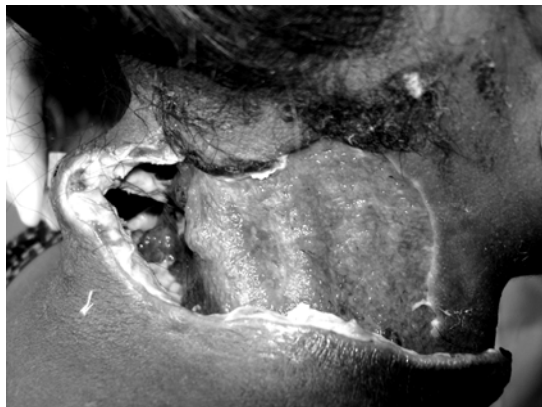
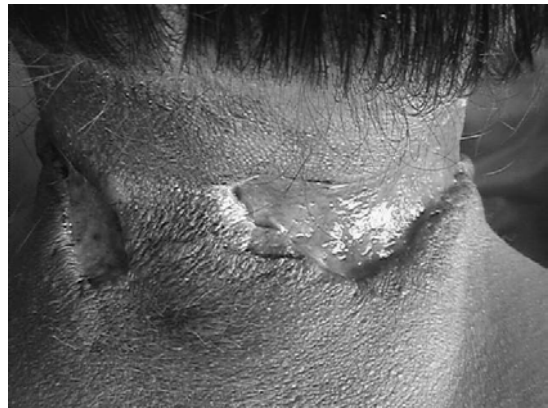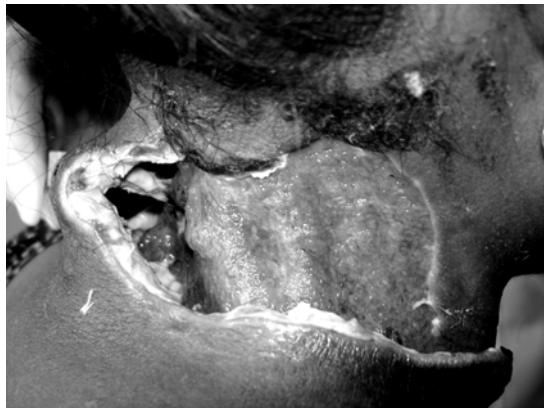
Rakesh Kumar Singh, Assistant Professor. Department of Otolaryngology Head and Neck Surgery, B.P. Koirala Institute of Health Science, Dharan, Nepal.

E-mail: r2696m2003@yahoo.com

Other investigations such as ECG, chest X-ray was found normal. The pus culture deep from the wounds grew *Staphylococcus aureus* sensitive to cloxacillin, gentamycin, tetracycline, vancomycin within 24 hour of incubation. She was treated with intravenous cloxacillin, intramuscular gentamycin and subcutaneous human insulin and oral non steroid anti inflammatory drug. On the basis of these findings the diagnosis of NF was made. The surgical debridement of devitalised tissue was done and twice in a day dressing of the wound with eusol soaked ribbon gauze was made. Within two days of above treatments the amount of pus was markedly reduced

and wound became dry within 5 days of antimicrobial treatment. However, her blood sugar was not controlled even after regular increase in the dose of insulin. Subsequently, the granulation tissue appeared and skin began to grow over it. Considering the condition of the patient and the rate and degree of appearance of granulation and growth of healthy skin, we decided to believe on natural healing rather than to do skin grafting. After one and half month of treatment the wound was completely healed without any residual deformity. She is getting further medical consultation to control her blood sugar.

**Fig. 1 (A-B)** Photograph of the patient showing necrosis of skin and soft tissue exposing underlying muscle. A bridge of healthy looking skin is seen in between two wounds. The sub dermal pus pocket is seen in continuation with the wounds (black arrow).



### Discussion

Integumentary system is the largest organ of human body provides the first line of defence against the microbial and non-microbial challenges. Once this natural blockade is breached, the micro-organism get hold of a chance to cross it and causes cutaneous and

subcutaneous infections.<sup>3</sup> NF is an unusual subcutaneous infection characterised by widespread necrosis of superficial and deep fascia resulting in devascularization of skin. It frequently affects

extremities, trunk, and perineum; the NF of head and neck is exceptional.<sup>4</sup>

The exact incidence of CNF is not known because of the diversities in the term used for this single clinical entity from time to time. However, the mean age of occurrence of cervicofacial NF is 44 years while 68% sufferers are male.<sup>5</sup>

NF is often common in diabetic patients. The reported rate of NF in diabetic up to 81% has been by different authority while Lin et al have observed diabetes mellitus in 72.3% of all 47 cases.<sup>1, 3</sup> It is for the reason that the microangiopathy in diabetic indemnify the tissue hypoxia. The associated peripheral neuropathies often result in increase incidence of unnoticed trauma. The reduce IgG level in diabetic nephropathy may put the patient on the risk of recurrent and serious infection.<sup>6, 7</sup> While hyperglycaemia in diabetes mellitus impairs leucocyte function and suppress immunity.<sup>3</sup>

The CNF is commonly caused by dental infections or surgical and/or non-surgical trauma.<sup>8</sup> The other aetiology includes cervical adenitis, salivary gland infection, peritonsillar abscess, and otological or dermal infection. Some rare possibilities are parotid and epiglottic infection; post surgical such as after laryngectomy, thyroidectomy, tracheostomy, esophagoscopy and intubation.<sup>7, 8</sup> Significant number of idiopathic NF has been reported in literature.<sup>2</sup> In our case no etiological factor has been revealed.

The cervical NF is an infection caused by micro-organism that is found in the upper aerodigestive tract, mostly *Streptococcus pyogenes*, *Staphylococcus aureus* and anaerobes.<sup>4</sup> We got *Staphylococcus aureus* as monomicrobial isolate in our case.

The initial clinical presentations are erythematous, tender, swollen area similar to cellulites with disproportionately severe pain in conjunction with fever, chills, weakness, confusion, and rash. Once the disease progresses, the skin develops a violaceous hue, may become necrotic with bullae formation, and eventually appears hemorrhagic and gangrenous. Necrosis of the superficial fascia and fat may leads to watery, thin and often foul smelling discharge known as "dishwater pus". Involvement of the muscle and/or nerves may lead to weakness and loss of sensory innervation. During second week, the skin may slough out. In some patients, spontaneous recovery is reported after skin sloughing.<sup>9,10</sup> In our case the presentation was late and by the time she visited our hospital, the disease had progressed. At the time of

admission she had had large discharging wound over the back of neck.

Investigations may show anaemia and leucocytosis<sup>10</sup> Wall et al. recommended that white blood cell count of more than  $14 \times 10^9/L$ , serum sodium level of less than 135mmol/L and blood urea nitrogen of more than 15mg/dL on admission helps to differentiate this condition from other types of soft tissue infections that are less aggressive.<sup>11</sup> Thrombocytopenia can occur in proximately half of all cases. Hypocalcaemia may develop due to fat necrosis. The incision biopsy down to the deep fascial level is the best tool to confirm diagnosis.<sup>4,9</sup> In our case except leucocytosis (16,900), anaemia, and hyperglycaemia other investigations were within normal range.

NF should be differentiated from other infective conditions like cellulites, erysipelas, impetigo, folliculitis, ecthyma, furunculosis, carbunculosis and myonecrosis, gas gangrene, pyoderma gangrenosum, phlegmasia cerulea dolens, thyroiditis and trauma.<sup>8,10</sup>

Once the diagnosis is suspected prompt surgical debridement is necessary along with antibiotics and intensive supportive therapy for associated multisystem failure. Some authors have advocated hyperbaric oxygen in the treatment of NF, apart from surgical debridements. Elliott et al. demonstrated that a combination of factors is more predictive of outcome than any individual factor.<sup>11</sup> In one study, if diabetes mellitus or atherosclerotic peripheral vascular disease as co-morbid factors of NF than the mortality rate above 80% has been reported.<sup>12</sup> The over all mortality rate for craniocervical NF ranges from 22-100%.<sup>1,3</sup> We did surgical debridement of devitalized tissue and appropriate dose of sensitive antibiotic was given to the patient. The recovery was uneventful.

The complications of CNF are airway obstruction, jugular venous thrombophlebitis, carotid artery rupture, aneurysm, thrombophlebitis wit hemiplegia, facial artery necrosis, laryngocutaneous fistula, disseminate intravascular coagulation, mediastinitis, pericarditis, pleural effusion, empyema, pericardial effusion, pneumonitis, cardiac tamponade, esophageal bleeding, septic shock and multisystem failure.<sup>1,4,7</sup> Our patient had no such complications.

Our patient was presented 20 days after the initiation of initial symptoms. She has uncontrolled type II diabetes mellitus with high fasting blood glucose level (mean 300mg/dl) during the course of management of NF. The location of disease was important, possessing life-taking complications. In

spite of all unfavourable prognostic factors we got outstanding result with full recovery.

### Conclusion

Necrotizing fasciitis of the head and neck is a rare occurrence. In significant number of cases no definite etiological factor has been reported. The diabetes mellitus is one of the most important precipitating factor that also determines the outcome of the disease. Prompt and aggressive treatment should be advocated merely on the basis of clinical suspicion. The time of intervention is the most important prognostic determinant of this disease.

### References

1. Panda NK, Simhadri S, Sridhara SR. Cervicofacial necrotizing fasciitis: can we expect a favourable outcome? *J Laryngol Otol* 2004; 118: 771-77.
2. Singh G, Sinha SK, Adhikary S, Babu KS, Ray P, Khanna SK. Necrotizing Infections of Soft Tissues-A Clinical Profile. *Eur J Surg* 2002; 168: 366-71.
3. Ndukawe KC, Fatusi OA, Ugboko VI. Craniocervical necrotizing fasciitis in Ile-Ife, Nigeria. *Br J Oral Maxillofac Surg* 2002; 40: 64-7.
4. Beerens AJ, Strack van Schijndel RJ, Mahieu HF, Leemans CR. Cervical necrotizing fasciitis with thoracic extension after total laryngectomy. *J Laryngol Otol* 2002; 116: 639-41.
5. Prakash PK, Biswas M, ElBouri K, Braithwaite PA, Hanna FW. Pneumococcal necrotizing fasciitis in a patient with Type 2 diabetes. *Diabet Med* 2003; 20: 899-03.
6. Ogawa D, Shikata K, Wada J, Matsuda M, Makino H. Successful treatment of necrotizing fasciitis associated with diabetic nephropathy. *Diabetes Res Clin Pract* 2003; 60: 213-16.
7. Marioni G, Bottin R, Tregnaghi A, Boninsegna M, Staffieri A. Craniocervical necrotizing fasciitis secondary to parotid gland abscess. *Acta Otolaryngol* 2003; 123: 737-40.
8. Umeda M, Minamikawa T, Komatsubara H, Shibuya Y, Yokoo S, Komori T. Necrotizing fasciitis caused by dental infection: Aretrospective analysis of 9 cases and a review of the literature. *Oral Surg Oral Med Oral Pathol Oral Radiol Endod* 2003; 95: 283-90.
9. Green RG, Dafoe DC, Raffin TA. Necrotizing fasciitis. *Chest* 1996; 110: 219-29.
10. Cunningham JD, Silver L, Rudikoff D. Necrotizing fasciitis: A Plea for early diagnosis and treatment. *Mt Sinai J Med* 2001; 68: 253-61.
11. Elliott D, Kufera JA, Myers RAM. The microbiology of necrotizing soft tissue infection. *Am J Surg* 2000; 179: 361-66.
12. Kumar A, Will EJ. Necrotizing fasciitis and Legionnaires' disease after combined renal and pancreatic transplantation: a penalty of overseas travel. *Nephrol Dial Transplant* 1999; 14: 1781-83.