

Visual outcome and IOP control after cataract surgery in lens induced glaucomas

Rijal AP¹, Karki DB²

¹Prof., National Academy of Medical Sciences, ²Senior Consultant Ophthalmologist Nepal Eye Hospital

Abstract

Lens induced glaucoma is one of the important cause of secondary glaucoma in our population. Retrospective analysis of 40 cases of lens induced glaucoma presenting to Nepal Eye Hospital from January 2002 to December 2004 were analyzed to find the prevalence of sex, age, visual outcome, IOP control, and duration between appearance of symptoms and surgical invention. Females out numbered male (55:45 percent). Phacomorphic glaucoma was seen more than phacolytic type (65:35). Visual recovery was good in 45% cases (6/12-6/60) and moderately fair in 30% cases (VA <6/60).

Preoperative IOP ranged from 24.0-59.0 mmHg. Postoperative IOP ranged from 14-22 mmHg. Duration between symptoms and surgery was 1 week to 4 months.

Keywords: Phacomorphic, Phacolytic, Glaucoma, ECCE, PCIOL

According to the National Blindness Survey conducted in 1980-81, 0.84% of population in Nepal is blind in both eyes and 1.7% in one eye. Major cause of blindness is cataract (66.8%). The annual incidence of cataract blindness is 18000-20,000, on the top of already existing cases awaiting surgery. Hence, the backlog is in increasing order. As the backlog is increasing, occurrence of lens induced glaucoma also is more often.

Lens induced glaucoma in general may be phacomorphic and phacolytic type. Other types like lens particle glaucoma and phacotoxic glaucoma may occur in some cases. The only modality of treatment in such type of glaucoma is lens extraction. Mode of treatment at present days is extracapsular cataract extraction with post chamber IOL (ECCE with PCIOL).

This is a retrospective study to find out the visual outcome and status of IOP after cataract surgery in lens induced glaucoma cases in Nepal Eye Hospital, Kathmandu.

Materials and Methods

This retrospective study was done at Nepal Eye Hospital by analyzing the data from case records of patients diagnosed to have lens-induced glaucoma admitted between Jan 2002 to Dec. 2004. A total of 40 cases were analyzed. The data recorded was in terms of age, sex, eye involved, visual acuity, slit lamp examination for corneal oedema, anterior chamber depth, pre and post operative IOP and visual

acuity. The duration between symptoms and surgery was also noted. Patients usually presented with the visual acuity of light perception to hand movement.

Diagnosis of phacomorphic glaucoma was made when patients presented with symptoms of pain, redness of involved eye, headache, IOP above 21 mmHg and shallow ac and intumescant lens.

Diagnosis of phacolytic glaucoma was made in patient presenting with raised IOP of above 21mmHg of mercury, Hyper mature cataract, deep anterior chamber and flare and cells in a.c.

Initially, control of IOP was done with top diamox 500 mg. oral three times a day and topical timolol maleate 0.5% 12 hourly and intravenous mannitol 20% 300 ml was given in 45 minutes times in cases where intraocular pressure (IOP) was above 40 mmHg. Topical predacetate 4 times a day was given to reduce inflammation.

Correspondence

Dr. A. P. Rijal,
Nepal Eye Hospital,
Tripureshwor, Kathmandu, Nepal

Out of 40 eyes, 32 eye were subjected to ECCE with PCIO implantation and 6 eyes underwent trabeculectomy + ECCE + PCIOL. 2 eyes underwent ECCE only. Cataract surgery was done by making a limbal incision and fornix based conjunctival flap, with envelope type anterior capsulotomy in majority of the cases. Can opener capsulotomy was done in few cases. Hydro-dissection nucleus delivery and thorough cortical clean up was done followed by PCIOL implantation in the bag.

In combined procedure, 4 cases had conventional fornix based conjunctival flap and 2 cases had limbus based conjunctival flap.

All the operated cases were examined post operatively daily and discharged on 4th or 5th post operative day. Most of the patients had improvement in vision as it was recorded at discharge time from hospital.

The patients were followed up in OPD after 1 week and 6th week from the day of discharge.

All patients were put on Topical Predacetate 2 hourly, Ciplox eye drop 2 hourly and Flubiprofen eye drop thrice daily during post operative period. Visual acuity recorded at the day of discharge, i.e. 4th or 5th postoperative day was PL to 6/18.

Tonometry was not done in early post operative period for fear of infection. Digital IOP assessment was normal. Bleb formation in combined cases was good which was indicator of IOP control.

IOP (Applanation) recorded at follow up visits later than 6 weeks were found to be in normal range 14-22 mmHg. Best corrected visual acuity with refraction done later than 6th post operative week was 6/12-6/24 mmHg.

Vision didn't improve in 6 cases (PL only in 4 cases and NPL in 2 cases). This was attributed to optic atrophy (Glaucomatous) in 4 patients, and vitreo-retinal disease in 2 cases. Vision of Hm to CF 2 meter only was found in 4 cases. 2 each of macular degeneration and corneal scar.

Results

Out of 40 cases, 26 (65%) were phacomorphic glaucoma and 14 (35%) were having phacolytic glaucoma. Age of presentation was between 46-78 years. Female were 22 (55%) and male were 18 (45%). Eye involved RE was 19 and LE 21. Preoperative IOP (Applanation) ranged from 24.0 to 59.0. 20 cases > 43 mmHg. 10 cases>30 mmHg and 10 cases 24-30 mmHg. Post operative IOP was recorded 14-22 mm/Hg. Duration between symptoms and surgery was 1 week to 4 months.

Fig 1: Percentages of patients according to types of glaucoma

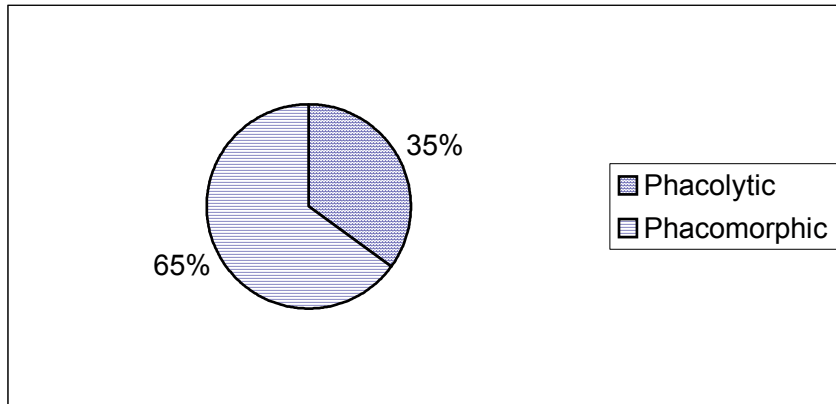


Table 1: Visual Acuity

Better than 6/24 (6/12 to 6/24)	25% (10 eyes)
6/36 to 6/60	20% (8 eyes)
Less than 6/60 (3/60 to 5/60)	30% (12 eyes)
HM-CF 2 meters	10% (4 eyes)
PL only	10% (4 eyes)
NPL	5% (2 eyes)

Fig 2: Visual Outcome

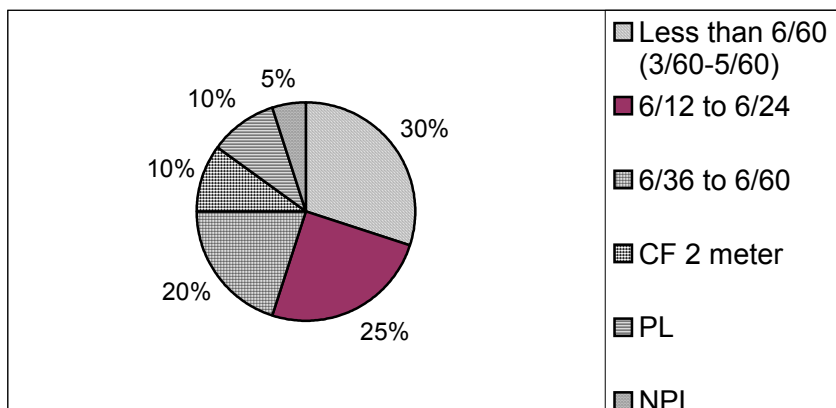


Table 2: Causes of poor vision

Optic Atrophy	4
Vitreo Retinal disease	2
Macular degeneration	2
Corneal scar	2

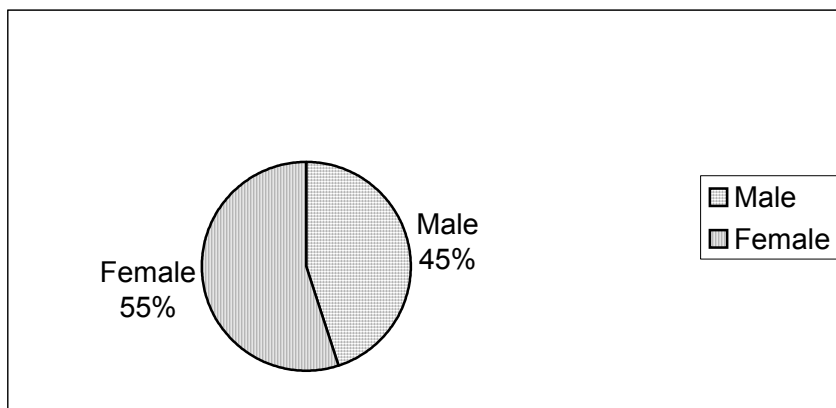
Discussion

Lens induced glaucoma is not uncommon in our population, where people cannot afford to undergo cataract surgery in time due to various financial, social, geographical and other constraints. Annual incidence of newer cases of cataract is 18000-20,000, besides pre-existing cataract backlog¹. Consequently, the backlog is increasing every year. Lens induced glaucoma are often seen in our country, where the

incidence of cataract cases exceeds the performance of cataract surgery. These lens induced glaucoma compromise the optic nerve functioning due to high intraocular pressure. The only modality of treatment is cataract extraction.

This study was undertaken to assess the visual acuity and IOP outcome in patients who presented as lens induced glaucoma in Nepal Eye Hospital.

Fig 3: Sex distribution



Analysis shows females are affected more as compared to male. This is identical with the study of Dr Prajna et. al (IJO 1996, 44, 149-155)³.

Phacomorphic glaucoma was seen more (65%) than phacolytic glaucoma (35%) in our study. This is more or less similar to earlier studies done in the country at Lahan by Dr Pradhan D et al² (Phamorphic 72%, Phacolytic 28%).

In our study, good visual acuity of better than 6/60 (6/12-6/60) was achieved in 45% cases, moderately fair vision, i.e. less than 6/60 (3/60 to 5/60) was observed in 30% cases, which is similar to Lahan study, which had 38.6% good visual acuity of better than 6/60 and 31.2% visual acuity less than 6/60.

Singh et al had 100% visual acuity in a study done in India⁴ (IJO, 1994, 42: 145-147). This may be because of earlier surgical intervention in their series at 6 days of presentation as against of our 1 week to 4 months of presentation.

Main cause of poor visual outcome was optic atrophy in our study, i.e. 4 cases (10%) which is less than earlier studies done at Lanan³, but similar to the studies at India.

At presentation, IOP was more than 40mm/Hg in 20 cases (50%) and 30-40 mm/Hg in 10 cases (25%), which was controlled to normal level 14-22 mmHg in all cases after cataract surgery, alike as it was found in Lahan study where preoperative IOP was >30mm in 79% and postoperative IOP after cataract surgery in 80.7% cases was below 21mmHg.

Out of 6 cases who had undergone combined surgery (Trab + Cataract), 4 were phacomorphic and 2 were phacolytic. Candidates for combined surgery were cases where IOP was not controlled despite full antiglaucoma treatment including i.v manitol injection.

Assessment of IOP control in combined cases was made by formation of good fluttering bleb post operatively.

In other cases also, despite high IOP at initial hospital presentation, IOP came down to normal limits after lens extraction. The results of lens induced glaucoma in response to visual recovery and IOP control is quite satisfactory and encouraging. Earlier is the lens extraction, better is the visual and IOP outcome.

There is a great need to impart health education to the public about the importance of timely surgery for better visual outcome and the dangers of poor visual result if cataract surgery is delayed.

Acknowledgement

We would like to give my sincere thanks to all our colleagues and staffs at Nepal Eye Hospital who helped us in carrying this study. We would also like to thank Mr Mukunda Wagle for typing and computer work.

References

1. Pokharel, R P et al. Program for Prevention and Control of Blindness in Nepal, Nepal Eye Hospital Souvenir 1982, Nov 47:62.
2. A Henning, Pradhan D et al. A Prospective Study of 413 Cases of Lens Induced Glaucoma in Nepal. Indian Journal of Ophthalmology 2001 June; 49 (2): 103-107.
3. M Venklesh Prajna et al. Lens Induced Glaucomas: Visual Results and Risk Factors for Final Visual Acuity. Indian Journal of Ophthalmology 1996;44:149-155.
4. Singh G, Kaur J et al. Phacolytic Glaucoma: Its treatment by planned ECCE with PCIOL implantation. Indian Journal of Ophthalmology 1994,42: 145-147.
5. Mandal A K, Gothwal V K. IOP and Visual outcome in patients with Phacolytic Glaucoma managed by ECCE with or without PCIOL implantation.
6. R Varsha et al. Visual and IOP outcome in lens induced Glaucoma. Ind. Ophth Book 1998, 119-121.
7. Eliant J P, Obstbaum SA. Lens Induced Glaucoma. American Academy of Ophthalmology 1992, 81:317
8. Rockwood EJ et al. Outcomes of Combined Cataract Extraction, Lens Implantation and Trabeculectomy Surgeries. AJO Dec 2000, 130 (6):704-711.
9. M Tanito, Ohira A et al. Surgical outcome of Combined Trabeculectomy and Cataract Surgery. J. Glaucoma 2001 Aug;10(4):302-308.
10. Becker and Shaffer's Diagnostic and Therapy of Glaucoma.