

Descending necrotizing mediastinitis: A fatal complication of neglected esophageal foreign body

Ghimire A¹, Bhattarai M², Kumar M³, Wakode PT⁴

¹Assistant Professor, ²Senior Resident, ⁴Professor, Department of Otolaryngology & Head-Neck Surgery, ³Associate Professor, Department of Surgery, B.P. Koirala Institute of Health Sciences, Dharan, Nepal

Abstract

Descending necrotising mediastinitis due to a neglected esophageal foreign body is uncommon. It is a lethal disease if it develops with full blown clinical picture. A case is reported of descending necrotising mediastinitis caused by a foreign body in oesophagus which is rarely reported in world literature. It is emphasized that prompt diagnosis and aggressive surgical mediastinal drainage is very important for the survival of these patients. Delayed diagnosis and treatment in our case may have been the cause of death of the patient. Delayed diagnosis in our case is due to the unavailability proper health facility in remote area in developing countries like Nepal.

Key words: Descending necrotising mediastinitis, foreign body, oesophagus, fatal complication

Esophageal foreign bodies remain a common clinical problem. Most of the time, the removal of the foreign body with rigid or flexible esophagoscopy cure the patients. Sharp foreign bodies or neglected cases of oesophageal foreign body sometimes may lead to serious complications like mediastinitis. The most dreaded and probably the most lethal form of mediastinitis is the diffuse necrotizing variety that occurs as complications of cervical or odontogenic infections. Descending necrotizing mediastinitis (DNM) usually has fulminant course, leading commonly to sepsis and death. The mortality of this disease is between 40% and 50%^{1,2}. The most common cause of DNM is odontogenic infections. Other causes include retropharyngeal abscess, peritonsillar abscess, cervical lymphadenitis, parotitis, thyroiditis, oesophageal trauma and traumatic endotracheal intubation, as well as a variety of others iatrogenic causes. Oesophageal foreign body as a cause for the descending necrotizing mediastinitis (DNM) has been reported very rarely in the world literature.

Here we present a case of delayed presentation of oesophageal foreign body with retropharyngeal abscess leading to the fatal complication of descending necrotizing mediastinitis.

Case Report

A 55 year old male presented to emergency department with history of accidental ingestion of chicken bone 10 days back which was followed by dysphagia and odynophagia. The place where it happened was a remote hilly area from where a primary health centre was 3 days of walking distance.

There was no means of surface transport available. Patient could not eat any solid food. So he drank only home made alcohol and water for 4 days. Swelling over the left supraclavicular area was noticed 3 days back which increased gradually. Four days after the incidence he developed fever with chills and dyspnoea. The patient attended the nearest primary health centre on 7th day of the incidence. From there he was referred to our centre.

On admission blood pressure was 110/70 mmHg, respiration rate was 22breath/min, pulse rate was 90/min and his body temperature was 100⁰ F.

Physical examination revealed erythematous swelling in left supraclavicular region and neck along with subcutaneous emphysema (Fig 1). There was a bulge in posterior pharyngeal wall from where 6 ml of thick pus was aspirated. Microbiological examination of the pus showed growth of *Morganella species* which was sensitive to amikacin, cefotaxim, ceftazidime and gentamycine.

Correspondence

Dr. Anand Ghimire
Assistant professor,
Department of Otolaryngology & head-Neck surgery
B.P. Koirala Institute Health Sciences, Dharan, Nepal
E-mail: anand_ghi@yahoo.com

Laboratory tests at the time of admission were as follows: total blood count-22400/mm³, differential leucocyte count- neutrophil 82%, lymphocyte18%, haemoglobin-14gm%, urea -96mg%, creatinine-0.6mg% ,blood sugar(random)- 159mg/dl. X- ray of the neck (lateral view) showed retropharyngeal abscess, (Fig-2) chest x-ray showed widening of the mediastinal shadow (Fig 3).

The CT scan confirmed the diagnosis of descending necrotizing mediastinitis, displaying retropharyngeal abscess with emphysema associated with diffuse mediastinitis with gas bubbles in the mediasinum. (Fig 4)

Intravenous triple antibiotic therapy (Ceftriaxone 1gm BID, Metronidazole 500mg TID, and Gentamycine 80mg BID) was started immediately after the admission. Emergency surgery was performed. First tracheotomy was performed and giving an incision along the anterior boarder of sternocleidomastoid muscle, neck was explored.

There was extensive necrosis of the tissues including the carotid sheath and internal jugular vein in left side. There were multiple pockets of abscesses. Extensive debridement of the necrotic tissue was performed. Abscess zones were broken and cleaned. Copious cleaning with oxygenated and iodized solutions was carried out. Transcervical mediastinal drainage was performed. A sharp chicken bone was removed from the oesophagus through rigid esophagoscopy (Fig 5). The wound was left open and dressing with hydrogen peroxide and povidone iodine was performed twice daily with necessary debridement of the necrotic tissue.

The patient was treated in intensive care unit. The triple antibiotic therapy was continued. The patient's condition became worse day by day. He expired on the 5th post operative day due to septicaemia and multi-organ failure.

Fig 1: Photograph of the patient showing erythematous swelling in left supraclavicular region and neck .

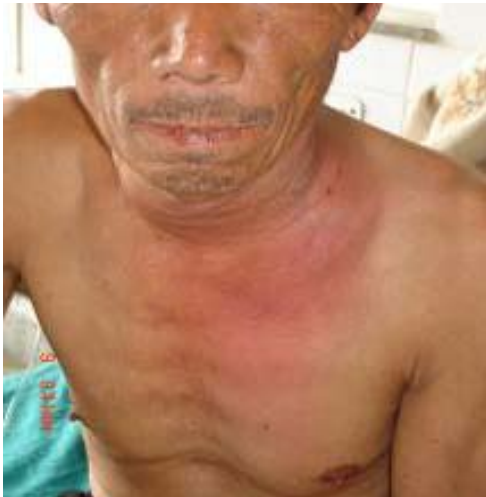

Fig 2: X-ray of the neck (Lateral View) showing the retropharyngeal abscess. It was taken after the admission of the patient.

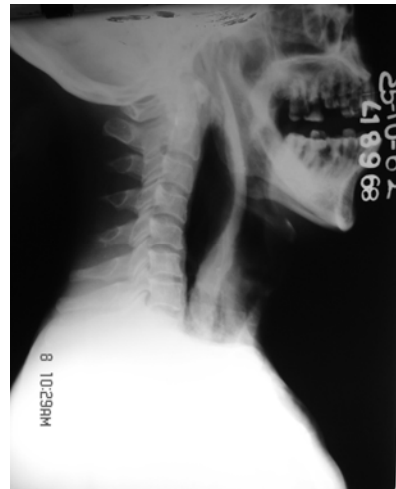

Fig 3: Chest X- ray (PA View) showing the widening of the mediastinum.

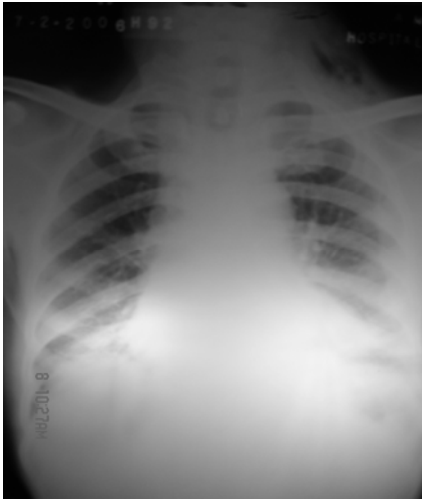

Fig 4: CT scan showing the gas bubbles with mediastinitis

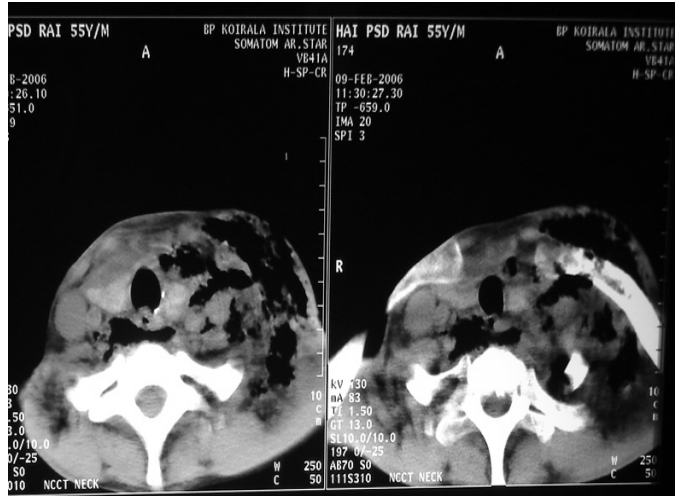
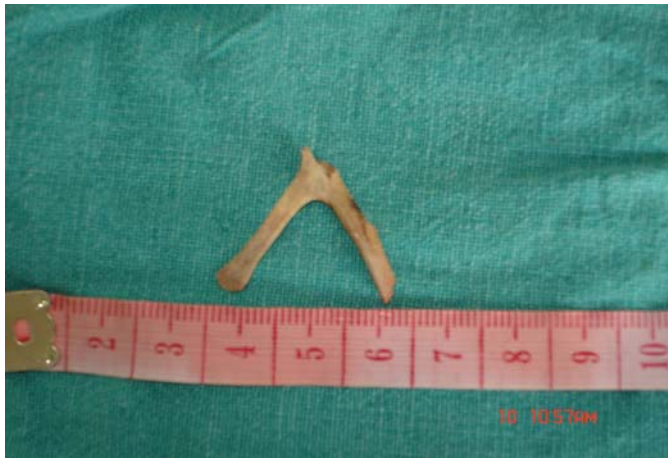

Fig 5: The sharp foreign body (chicken bone) removed from the oesophagus.



Discussion

Descending Necrotizing Mediastinitis (DNM) has been defined as the mediastinum infection which results from the spreading of oropharyngeal or cervical infections. The mediastinum communicates with head-neck structures through several muscular fascia planes and virtual spaces. Infections originating in the fascial planes of the head and neck spread downward into the mediastinum along the cervical fascias, facilitated by gravity, breathing, and negative intrathoracic pressure.

The criteria for diagnosis of DNM were accurately defined by Estrera and colleagues.³ These criteria include: 1) clinical manifestation of severe oropharyngeal infection (odontogenic, peritonsillar, or retropharyngeal abscesses, Ludwig's angina, or infection secondary to traumatic pharyngeal perforations); 2) demonstration of characteristic roentgenographic features of mediastinitis; 3) documentation of mediastinitis at operation or postmortem examination, or both; and 4) establishment of relation between oropharyngeal

infection and development of the necrotizing process in the mediastinum. Our patient met all these criteria.

Delay of diagnosis is one of the primary reasons for the high mortality in DNM. The diagnosis of cervical infection is clinically obvious, but early diagnosis of mediastinitis is often difficult because of the absence of early clinical or radiological signs. In our case also definite signs and symptoms of mediastinitis (dyspnoea, subcutaneous emphysema, and swelling over supraclavicular region) were apparent only 3 days before the admission.

Most of the time the cause for the DNM are oropharyngeal infections (Odontogenic infections, peritonsillar abscess, retropharyngeal abscess)^{4,5}. Foreign body in oesophagus has rarely been reported as a cause for DNM⁶.

DNM has been described as a polymicrobial infection, with participation of aerobic and anaerobic bacteria. Group A *Streptococcus*, has been found to be the most common pathogens. *Clostridium perfringens*, *Staphylococcus aureus*, *Pseudomonas aeruginosa* and anaerobes has also been reported.^{6,7} In our case *Morganella species* were isolated.

Treatment of DNM consists of intravenous broad spectrum antibiotics therapy with adequate surgical drainage of the cervical and mediastinal collections and extensive debridement and excision of necrotic tissue. In our case these measures had been taken as soon the diagnosis has been established by CT scan.

The high mortality rate of DNM is due to the multi-organ failure and sepsis syndrome. Early diagnosis with prompt surgical drainage and debridement and appropriate medical management in an intensive care unit can decrease the mortality rate. But in our case the delayed presentation of the patient and subsequently the delay in treatment may be the cause for the death of the patient. Unavailability of the health facility in remote area in developing countries like Nepal is a common problem. If patient could seek the medical facility in time, removal of the foreign body in time could have saved further complications and loss of life.

Conclusion

Oesophageal foreign body remains a common clinical problem. But non-availability of proper medical facilities in near by place and lack of transport facilities can result in a tragic death. Awareness and availability of the health facility for the people living in a remote area of the country may save many such sad incidences.

References

1. Bulut M., Balcy V., Akose S., Armagcan E.. Fatal descending necrotising mediastinitis. *Emerg Med J* 2004;21:122–123
2. Choudhary N., Agrawal S., Rai A.K. Descending necrotising mediastinitis: trends in developing countries. *Ear Nose Throat J.* 2005; 54: 246-248.
3. Estrera AS, Landay MJ, Grisham JM, et al. Descending necrotizing mediastinitis. *Surg Gynecol Obstet* 1983; 157:545–52.
4. Figueroa-Damin R. Clinical manifestations and lethality of descending necrotizing mediastinitis. *Rev Invest Clin* 2001; 53 (1): 35-40
5. Henri C., Ane M., Berthet J.P, Alric P et al. Management of Descending Necrotizing Mediastinitis: An Aggressive Treatment for an Aggressive Disease. *Ann Thorac Surg* 1999;68:212–7)
6. Makeieff M., Gresillon N., Berthet J. P., Garrel R., et al. Management of Descending Necrotizing Mediastinitis. *Laryngoscope*, 114:772–775, 2004.
7. Ris H.B., Banic A, Furrer M., Caversaccio M. et al. Descending Necrotizing Mediastinitis: Surgical Treatment via Clamshell Approach. *Ann. Thorac. Surg* 1996; 62:1650-1654