

## Managing cysticercosis in anterior chamber of eye: A case report

Shariq SM<sup>1</sup>, Adhikari BP<sup>2</sup>

<sup>1</sup>Lecturer, <sup>2</sup>Medical Director, Department of Ophthalmology, Fateh Bal Eye Hospital, Nepalgunj Medical College, Nepalgunj, Nepal

---

### Abstract

Cysticercosis in anterior chamber (AC) is rarer than in other ocular sites. And it is usually associated with plastic iridocyclitis. We report herein a case of a live cyst in the AC. The cyst was removed intact through limbal incision by visco expression technique. Histopathology confirmed *cysticercosis cellulosae* as the infecting agent. Timely removal of cyst can save the eye from severe plastic iritis.

**Key words:** cysticercosis, anterior chamber, methyl cellulose

---

Cysticercosis is the human infection with the larval form of pork tape worm, taenia solium. Human infection occurs usually by eating raw infected pork, contaminated vegetables or drinking polluted water. Cysticercosis escapes into the circulation from intestine. They are distributed throughout the body, resting particularly where the capillaries are narrow and the current slow. In the eye itself the location varies, the most common site being subretinal in which case the parasite enters through posterior ciliary arteries. From subretinal space, how ever it passes through a tear in the retina into vitreous and exceptionally from post segment through pupil into the anterior chamber.<sup>1</sup> Leach (1949) in 111 cases found 44 subretinal, 51 in the vitreous, 10 subhyaloid 2 in AC, 7 sub conjunctival and 2 in the orbital region.<sup>1</sup>

Presence of intraocular cysticercosis is a contraindication for the systemic use of antihelmenthic drugs as the intra ocular death of a worm can cause a severe allergic blinding panuveitis.<sup>2</sup> What ever its pathogenesis, it is important to achieve removal of the intact cyst because the breach of its integrity leads to a severe reaction.<sup>3</sup>

### Case Report

A 5 year old Nepalese girl presented with pain redness for 2 month and opacity in right eye (RE) for 10 days. There was H/O treatment of corneal ulcer at PHC. It is only after developing a cyst in the AC; she was referred to FBEH, Nepalgunj. There was no H/O fever, convulsion, worm infestation, Rashes/Nodules or any pets. She was non-vegetarian but did not take pork. Her visual acuity was 20/120 RE, 20/20 left eye (LE). Ocular motility was unrestricted. LE was normal. Slit lamp biomicroscopy revealed a whitish translucent round cyst about 3 mm in diameter in the AC of RE. The cyst was attached nasally on the back of cornea in

pupillary area. Transmitted movement was present in light beam.

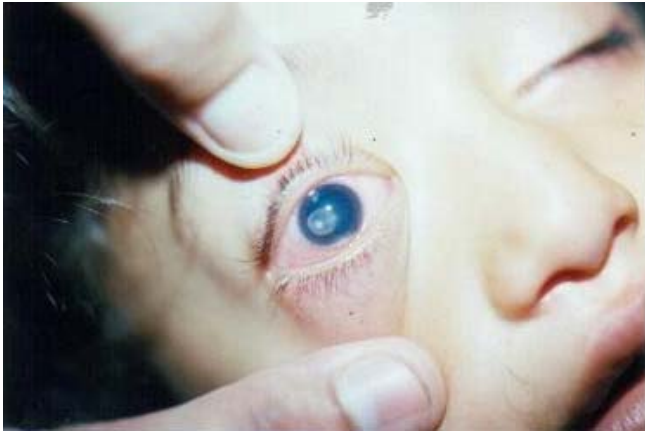Grads II flare and minimal hypopyon was present. Both pupil were dilated under mydiatric. Fundus examination showed no abnormality in both eye. Haemogram and ESR were within normal limit. Result of stool examination was negative. Computed tomography (CT) scan did not show any cyst / nodule in head and orbits. Patient was admitted for early surgery. Therapy start with tab. Prednisolone 1mg/kgbd wt /day and topical prednisolone acetate 1% 4 times started.

About 3 mm limbal incision was given at 9'o clock position under ketamine anaesthesia. Cyst detached from cornea and stucked at the corneoscleral section, as the aqueous came out. 2% methylcellulose was introduced with 27 gauge canula through section. Depression of posterior lip of the section and gentle pressure over cornea lead to expression of intact cyst along with methylcellulose. Remnant part of cyst from the back of cornea and hypopyon was aspirated. The methylcellulose was removed and AC was maintained with air. The incision was closed with 10-0 monofilament interrupted stitches. Cyst specimen sent for histopathology (Fig) Eye was quite second post op day. She was discharged with tapering dose of oral and topical steroid. After two week follow up her VA was 20/80 with quiet eye.

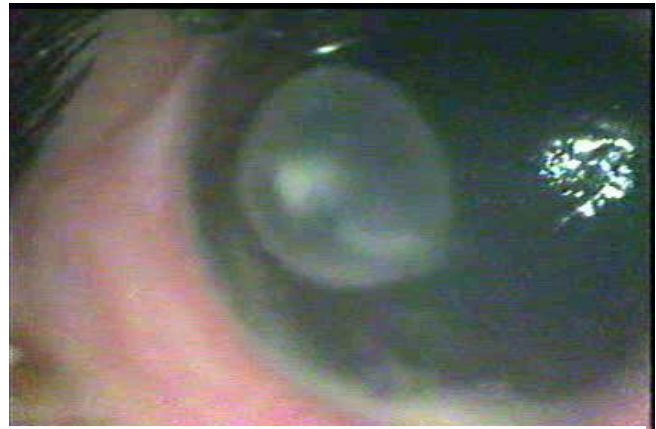
---

### Correspondence

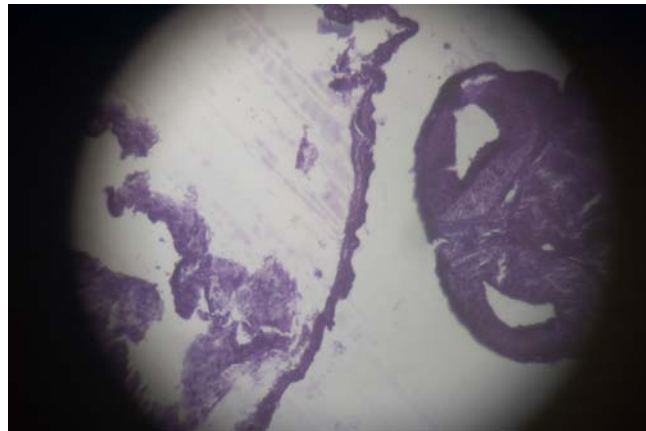
Dr. S.M. Shariq  
Fateh Bal Eye hospital Fultekra,  
Nepalgunj, Nepal  
Email Add: drsharry@rediffmail.com



**Fig 1:** Cysticercosis in anterior chamber of eye



**Fig 2:** Cyst attached at the back of cornea. Hypopyon present



**Fig 3:** Histopathology section of larva of taenia solium showing Cuticle of parasite, Subcuticular cells, Smooth muscle fibres, Suckers

### Discussion

Cysticercosis affects 50 million people world wide<sup>2</sup>. In Nepal the consumption of pork is quite common here. In a study of seizure disorders of brain parenchyma on CT scan, out of 50 cases 25 cases were suffering from neurocysticercosis<sup>4</sup>. This case was non-vegetarian but did not take pork. It shows the possibilities of other source of infection. In a way presence of cysticercosis in AC of eye, which is a rare form of disease, suggests high prevalence of disease in the region. Management of cysticercosis in AC include simple paracentesis, capsule forceps, cryo extraction and erysiphake extraction for the removal of cyst<sup>5,6</sup>. But manipulation and instrumentation may cause rupture of the cyst. In this case we used 2% methylcellulose, a visco surgical device (VSD) which helped in maintaining the AC, coating endothelium and lubricating the

cyst and corneoscleral section. It also helped in building pressure in AC because of which cyst came out intact. We found only one similar case report on cysticercosis in AC of eye in which VSD was use for extraction of cyst<sup>7</sup>. So it can be a simple, safe and easier method of removing cyst from AC of the eye and prevents serious complication like plastic iridocyclitis.

### Reference

1. Duke-Elders, Perkins Edward S. System of Ophthalmology. St. Louis CV company; 1977. Vol IX; p478-481.
2. Patwardhan N, Bhatti SS. Intraocular cysticercosis –A case report. Journal of the Bombay Ophthalmologist association, sept. 2000. Vol 10.No 3, P161-162.
3. Mathur RN, Abraham I, Cysticercosis of eye : a case of a plastic iridocyclitis due to

- cysticercosis cyst in the anterior chamber. Arch Ophthalmol, 1962. 67:562–563.
4. Kumar A, chaturvedi SK, Kothari G. Radiological evaluation of IV contrast ring enhancing CT scan. Journal Nepalgunj Medical collage, July 2002. Vol 2, P27–29.
  5. Kapoor S, Sood GC, Aurora AC, Sood M. Ocular cysticercosis: report of a free floating cysticercosis in the anterior chamber. Acta Ophthalmol, 1977. 55: P927–930.
  6. Wood TR, Binder PS. Intravitreal and intracameral cysticercosis. Ann Ophthalmol 1979. 11: P1033–1036.
  7. Beri S, Vajpayee RB, Dhingra N, Ghose S. Managing anterior chamber cysticercosis by visco expression: a new surgical technique. Arch Ophthalmol, Oct 1994. 112:P1279–1280.