

Situs inversus with dextrocardia with multiple cardiac lesions in adult

Piryani RM¹, Shukla A², Prasad DN³, Kohli SC⁴, Shrestha G⁵ Singh D⁶

^{1,5}Department of Medicine Nepalgunj Medical College Kohalpur, Nepalgunj, ⁶Department of Radiology Nepalgunj Medical College Kohalpur, Nepalgunj, ^{1,2}Assistant Professor, ^{2,6}Associate Professor, ⁵Professor, ⁶Professor & Head of Department

Abstract

Situs inversus with dextrocardia is the malposition most likely to occur with structurally normal heart; generally discovered on routine chest x-ray or physical examination performed for other reasons. These persons experience normal longevity of life and have similar risk of getting acquired disease as that of other person of same age and sex group. Symptoms related to acquired disorder may also lead to discovery of such cardiac malposition. Incidence of congenital cardiac anomalies in dextrocardia with situs inversus is very low globally but its figure in Nepal is not known. We report an adult of 43 years age having situs inversus with dextrocardia associated with multiple cardiac lesions i.e. ventricular septal defect, aortic regurgitation, mitral regurgitation and tricuspid regurgitation.

Key words: Situs Inversus Totalis, Dextrocardia, Congenital Cardiac Anomalies, Nepal

There are two types of situs unambiguous, being situs solitus-the normal and situs inversus -the mirror image of normal and three basic cardiac malpositions in patients without visceral heterotaxy- situs inversus with dextrocardia, situs solitus with dextrocardia and situs inversus with levocardia^{1, 2}. Situs inversus with dextrocardia is the malposition most likely to exist with structurally normal heart; generally discovered on routine chest x-ray or physical examination². Incidence of congenital cardiac anomalies in dextrocardia with situs inversus is low as compared to congenital cardiac anomalies³. A 3-5% incidence of congenital heart diseases is observed in Situs inversus with dextrocardia; usually with transposition of great vessels. Here we report an adult having situs inversus with dextrocardia associated with multiple cardiac lesions i.e. ventricular septal defect (VSD), aortic regurgitation (AR), mitral regurgitation (MR) and tricuspid regurgitation (TR).

Case Report

A forty three years old male attended outpatient department with history of progressive dyspnoea. He first felt dyspnoea in early adulthood. His pulse was 100 beats per minute, regular with moderate volume. Peripheral pulses were normally palpable. His blood pressure was 105/90 mm Hg and respiratory rate was 18 breaths per minute and lungs were clear on auscultation.

There was chest asymmetry with right anterior bulge and visible pulsation in supraclavicular fossae, epigastrium and right 4th, 5th and 6th intercostal spaces.

Apical impulse was diffuse and right parasternal heave was present. Systolic thrill was palpated at right 3rd, 4th and 5th intercostal spaces. Cardiac dullness detected on right side, liver dullness on left side and tympanic note over right hypochondrium on percussion. Heart sounds were louder on right side of chest and loud S2 at right 3rd intercostal space. Grade IV holosystolic murmur was audible at right 3rd, 4th and 5th intercostal spaces and diastolic murmur at left 3rd intercostal space.

Chest x-ray Posteroanterior (CXR PA) revealed base to apex axis pointing towards right, cardiomegaly, stomach bubble on the right, liver shadow on left and thin walled cavities measuring 1cm to 2.5 cm in diameter in right upper zone (Fig 1). Electrocardiography (ECG) showed inverted p wave and negative QRS complex in lead I, and positive QRS complex, inverted p wave in lead avR, inverted p wave in avL and QS pattern in leads V 1-V 4 with inverted t wave (Fig 2a). ECG tracing with reversed limb leads revealed positive p and QRS complex in lead I (Figure 2 b). Echocardiography demonstrated dextrocardia with ejection fraction of 70%, large VSD at peri-membranous position with left to right shunt (transventricular PG 30 mm Hg), severe AR, mild MR and moderate TR (Fig 3). Ultrasound abdomen reported reversal of abdominal viscera. Sketch illustrations are shown in Fig 4.

Correspondence

Dr. Rano Mal Piryani
Assistant Professor / Consultant, Department of Medicine
Nepalgunj Medical College, Kohalpur, Nepalgunj
E mail: r_piryani@yahoo.com

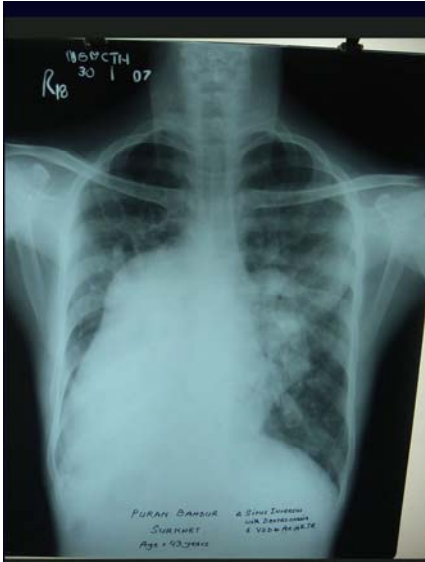

Fig 1: CXR PA view of patient (base to apex axis pointing towards right, cardiomegaly, stomach bubble on right, liver shadow on left and thin walled cavities on right side)

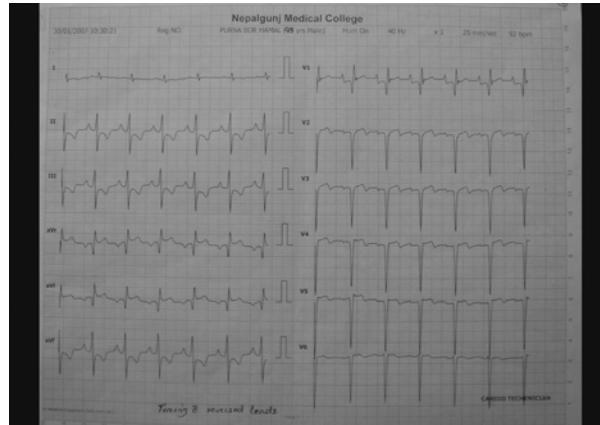


Fig 2 b: ECG of patient with reversed leads

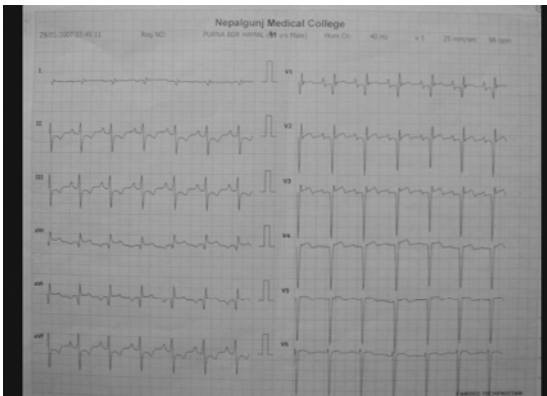


Fig 2 a: ECG of patient with normally placed leads

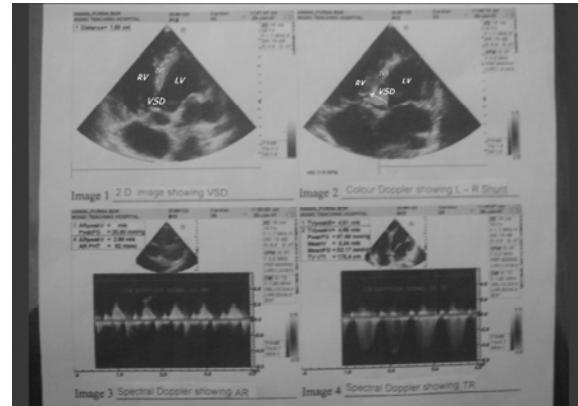


Fig 3: Echo of patient showing dextrocardia, VSD (L-R shunt), AR, TR

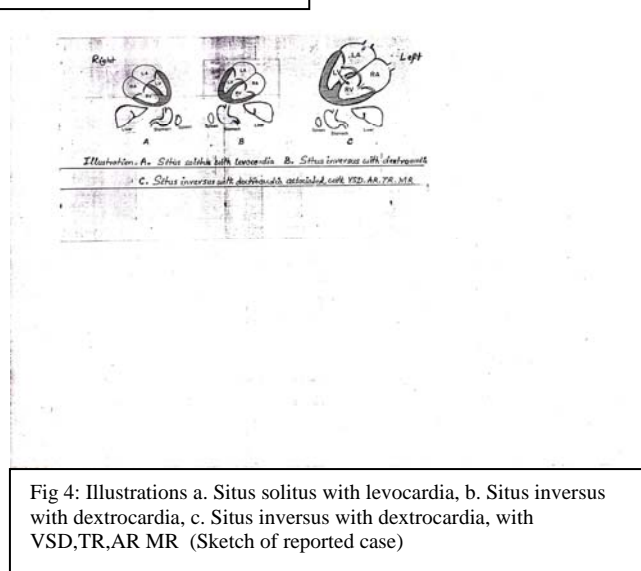


Fig 4: Illustrations a. Situs solitus with levocardia, b. Situs inversus with dextrocardia, c. Situs inversus with dextrocardia, with VSD,TR,AR MR (Sketch of reported case)

Discussion

Situs inversus with dextrocardia also is termed as situs inversus totalis because the cardiac position as well as atrial chambers and abdominal viscera, is a mirror image of normal anatomy^{4, 5}. Situs inversus is present in 0.01% of the population of United States⁴ but its incidence in Nepal is unknown.

Person having situs inversus with dextrocardia without other congenital anomaly experience normal longevity of life and have a similar risk of getting acquired disease as that of other person of same age and sex group. If angina pectoris or myocardial infarction occurs, the pain is located in the right anterior chest with radiation to the right shoulder and right arm. Symptoms related to acquired disorder may lead to discovery of suspected cardiac malposition. The recognition of situs inversus is important for preventing surgical mishaps that result from the failure to recognize reversed anatomy and atypical history^{2, 4}.

Patients with situs inversus may have associated heart malformations such as VSD, ASD Tetralogy of Fallot, tricuspid atresia, pulmonary stenosis, single ventricle, AV canal defect; but transposition of great arteries probably the most common. Presentation varies depending on associated malformation^{2, 3, 6, 7, 8}.

Peri-membranous VSD are much common in Caucasian and have a relatively low incidence of AR, whereas sub arterial VSD in the outlet septum are more common in Asian and have a relatively high incidence of AR. In contrast to the equal sex distribution in uncomplicated VSD, the male to female ratio is as high as 2:1 when AR supervenes⁹. Kulkarni and Inamdar reported a case from Medical College Nanded India having situs inversus with dextrocardia associated with VSD in 2005³.

Interestingly this patient had situs inversus totalis with multiple cardiac lesions VSD, AR, MR and TR. This case is reported because of the situs inversus with dextrocardia with complex pattern of cardiac malformation.

Acknowledgement

We acknowledge the support of Dr. S K Kanodia (Managing Director), Dr. S M Mishra (Principal), Dr J Mahaseth, (Director) and Dr K Sapkota of Nepalgunj Medical College.

References

1. Ulrike B, Johannes W, Christen P S: Heterotaxy syndrome-asplenia and polysplenia as indicators of visceral malposition and complex congenital heart disease. *Biol Neonate* 2005; 88:278-290
2. The Cardiac Malposition- Perloff's The Clinical Recognition of Congenital Heart Disease, Fourth Ed-India Ed. Harcourt Brace & Company Asia PTE Ltd, W B Saunders Co, 1998; Chapter 3: page 21-52
3. Kulkarni PR, Inamdar VV- Situs Inversus with dextrocardia associated with ventricular septal defect- a case report, Abstract, *Journal of the Anatomical Society of India* 2005; 54 (1)
4. Wilhelm A, Holbert JM- Situs Inversus, last updated April 2003, eMedicine from WebMD.htm
5. Van Praag R- Terminology of congenital heart diseases, Glossary and commentary, *Circulation (J-AHA)* 1977; 56: 139-143
6. Anoop P, Kumar V, Sasidharan CK- Situs inverses totalis with complex cardiac malformations in Goldenhar Syndrome, *Kuwait Medical Journal* 2004, 36 (3) : 212-213
7. Madan Kumar K, Irineu, Babu C, Chander S, Kumar A, Balchander J, Nachipaan M- Complete A-V canal defect with dextrocardia with CCTGA- A case Report, *IJTCVS* 2003; 19: 55
8. Partridge JB, Scott O, Deverall PB, Macartney FJ- visualization and measurement of the main bronchi by tomography as an objective indicator of thoracic situs in congenital heart disease, *Circulation (J-AHA)* 1975; 51: 188-196
9. Ventricular Septal Defect with Aortic Regurgitation- Perloff's The Clinical Recognition of Congenital Heart Disease, Fourth Ed-India Ed. Harcourt Brace & Company Asia PTE Ltd, W B Saunders Co, 1998; Chapter 17: page 422-428