

Clasping of subscapular artery by radial nerve

Kuwar RB¹, Bilodi AKS²

¹Lecturer in Anatomy, ²Associate professor of Anatomy, Nepalgunj Medical College, Chisapani Banke

Abstract

The present study is about an abnormal origin of radial nerve from Posterior cord of brachial plexus. Here radial nerve was arising as two roots from the posterior cord of brachial plexus. One root was passing posterior to the subscapular artery and other root anterior and the artery was situated between the two roots of the radial nerve. Further down both the roots united to form the trunk of the radial nerve.

Key words: Radial nerve, Subscapular artery, Brachial plexus. Posterior cord, Axillary artery

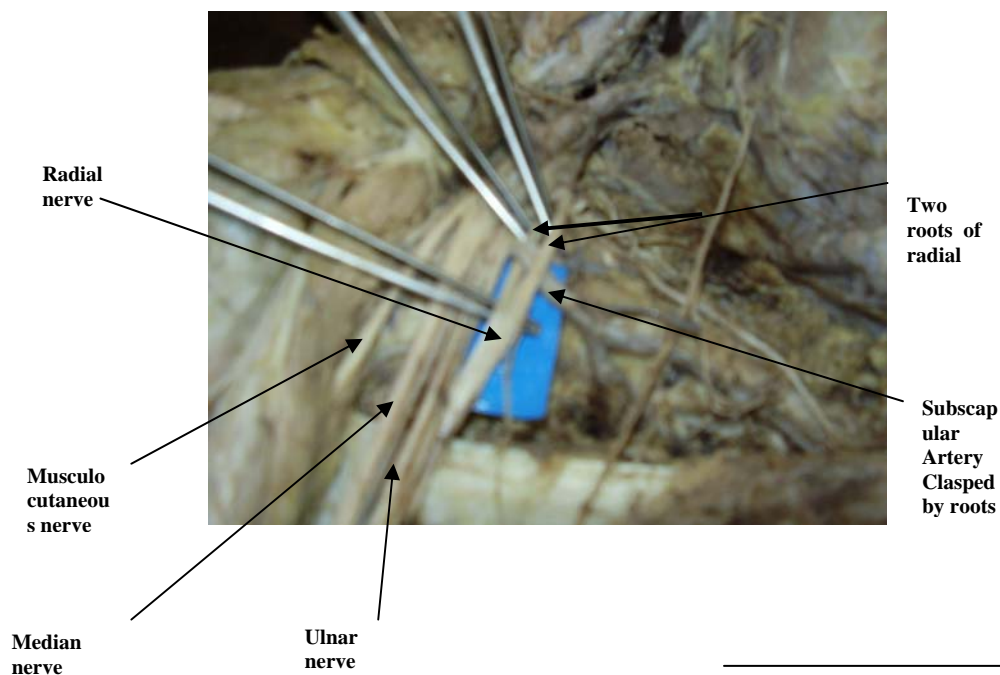
The radial nerve is the largest branch of the Posterior cord of brachial plexus with root value of C_{5,6,7,8} and T₁. In the axilla, it lies posterior to the third part of axillary artery and anterior to the subscapularis, latissimus dorsi, and teres major muscles.

Subscapular Artery is the largest and the most variable branch of the axillary artery¹. It arises at the lower border of the subscapularis muscle. It is accompanied distally by the nerve to the latissimus

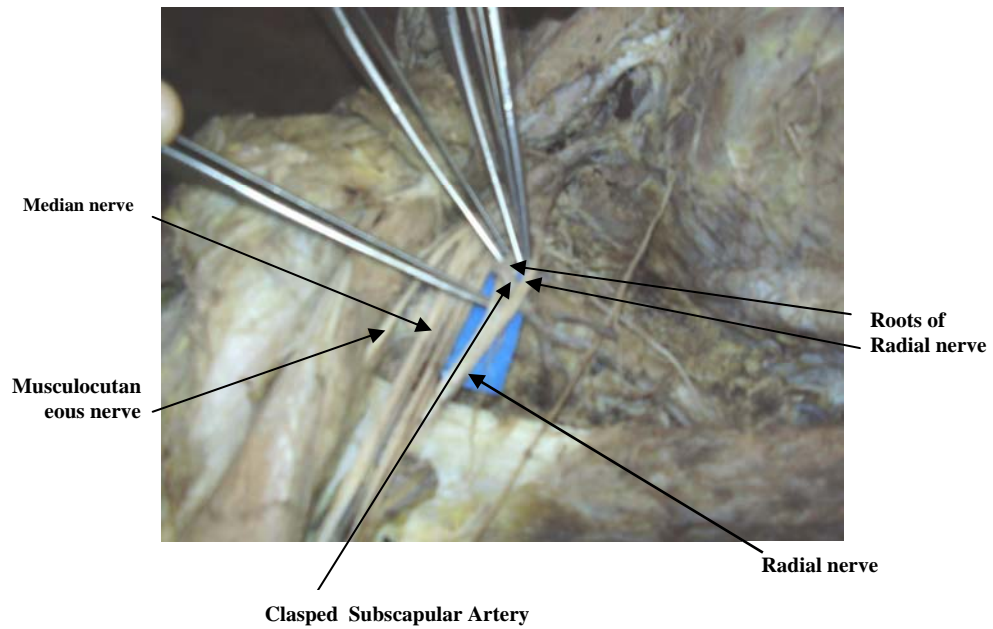
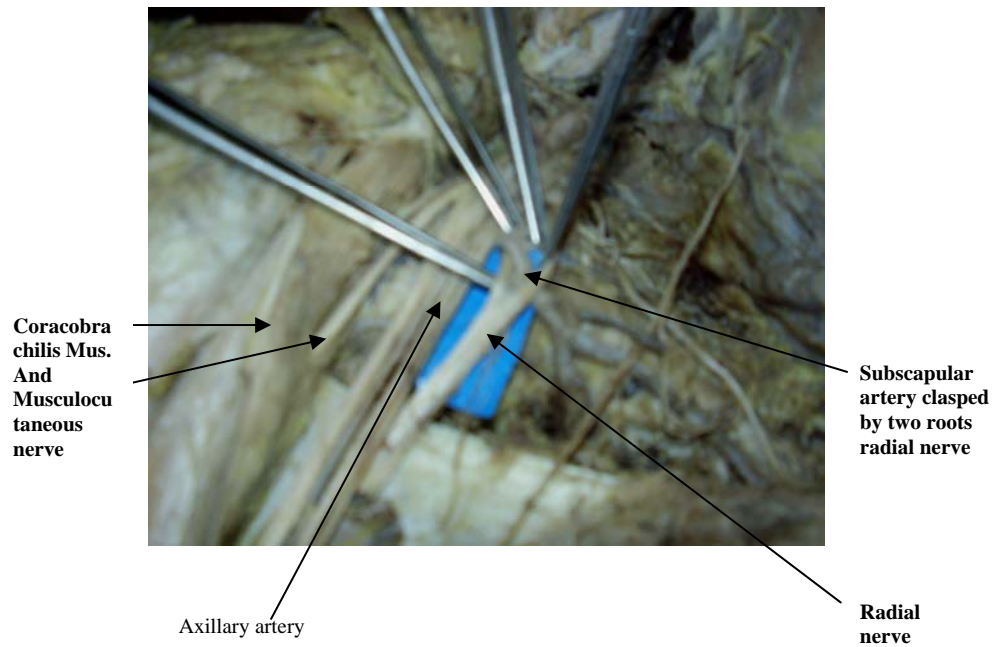
dorsi. About 4 cm. from its origin it divides into the circumflex scapular artery and thoracodorsal artery².

Case Report

A variation was found in the right axilla in a female Nepali cadaver during dissection in the Department of Anatomy, Nepalgunj Medical College, Chisapani-Banke, Nepal. The formation of brachial plexus and its relations with arteries were studied. The branches of brachial plexus were carefully separated, studied along the subscapular artery.



Correspondence
Mr. Ram Bahadur Kuwar
Lecturer,
Department of Anatomy Nepalgunj Medical College,
Chisapani Banke.
E-mail:rbkuwar@yahoo.com



Results

In this case it showed two roots of the radial nerve arising from the posterior cord, where one root was posterior to the subscapular artery while the other root was anterior to the artery encircling the said artery. The medial and lateral cord and their branches were normal but there was variation in the posterior cord and the origin of radial nerve. All the branches of axillary artery were normal. Thus the artery was completely encircled by the roots of the radial nerve.

Discussion

There are only few variations of radial nerve that have been studied by different anatomists. There is a case in which radial nerve was arising from the union of posterior division of inferior trunk and the middle trunk and no contribution from the superior trunk.³

There is another case study in which accessory radial root which was the branch of inferior trunk and was communicated with the root from the posterior cord to form the radial nerve. The radial nerve was penetrated by aberrant axillary artery from deep to superficial during its course.⁴In our study we found radial nerve is penetrated by subscapular artery and the two roots later unite to form trunk of radial nerve. In literature it has been said that the segmental origin of the axillary artery and its branching may determine the arrangement of the brachial plexus during foetal development⁵which may be the cause of this rare variation. To our knowledge, this variation has not been previously reported in the literature. This variation of above neurovascular bundle is quite rare and the radial nerve might have caused compression the subscapular artery. This knowledge may be of

help to vascular surgeons and hence it is studied and reported

Acknowledgement

We authors sincerely thank

- i}The Managing director of Lord Buddha Educational Academy
- ii}The professor and HOD of Anatomy and Principal of Nepalgunj Medical College Chisapani

References

1. AizawaY, Ohtsuka K,Kumaki K-(examination on the courses of the arteries in the axillary region. The course of the subscapular artery system, especially the relationships between the arteries and posterior cord of the brachial plexus) Kaibogaku Zasshi 1995; 70(6):554-68
2. Peter L. William, Gray's anatomy, 37th edition Great Britain: Churchill Livingstone, 1989; page-,757-757
3. Aktan ZA,OzturkL,Okan B,Ozer MA,Pinar YA- A cadaveric study of the Anatomical variation of Brachial plexus Nerves in the axillar region and arm. Turk J.Med.Sci.2001; 31:147-150
4. Honma S,Kawai K,Koizumi M, Yoshinaga K,Tanii I,Kodama K-An aberrant axillary artery penetrating the origin of the radial nerve from deep to superficial. Ann.Anat.2004;286:153-6
5. Lengele B.,Dhem A. Unusal variation of vasculonervous elements of the human axilla report of three cases. Arch Anat.Histol.Embrol. 1989; 72: 57-67

