

# Endodontic Management of Radix Paramolaris with Six Canals: A Clinical Case Report

Acharya N, Singh A, Samant PS, Gautam V

Department of Conservative Dentistry and Endodontics, Universal College of Medical Science

College of Dental Surgery

Bhairahawa, Nepal

## Corresponding Author

Nisha Acharya

Department of Conservative Dentistry and Endodontics, Universal College of Medical Science

College of Dental Surgery

Bhairahawa, Nepal

E-mail: me\_nisha5@hotmail.com

## Citation

Acharya N, Singh A, Samant PS, Gautam V. Endodontic Management of Radix Paramolaris with Six Canals: A Clinical Case Report. *Kathmandu Univ Med J* 2013;44(4):338-341.

## ABSTRACT

Endodontic therapy of mandibular molars is a challenging task due to its varied root canal morphology. A mandibular first molar with additional buccal root (Radix paramolaris) and additional distolingual root (Radix Entomolaris) is an example of its varied anatomy. A successful management of atypical root canal configurations is an important aspect in determining the success rate of root canal therapy. The detail knowledge of the root morphology and canal anatomy allows the clinician for accurate location of the extra roots and canals and accordingly the refinement of the access cavity for the stress free entry of complex anatomy. Hence, for a successful root canal therapy, clinician must be aware of the external and internal anatomic variations. The aim of this clinical case report is to present and describe the unusual presence of two separate mesial roots and six root canals in mandibular first molar, detected during routine endodontic therapy.

## KEY WORDS

*Atypical configurations, extra root, mandibular first molar, radix paramolaris, radix entomolaris*

## INTRODUCTION

Accurate diagnosis and successful endodontic therapy is always a challenge due to the complexity of the root canal morphology, especially in multi rooted teeth. Literature shows number of case reports on the anatomic variations and the abnormalities that are associated with the mandibular first molars.<sup>1-7</sup>

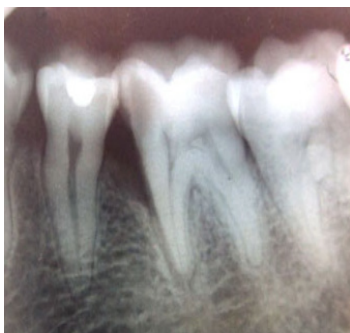As usual root canal morphology, mandibular first molars have two roots (mesial and distal) with two canals in the mesial root and one or two canals in the distal root. Occasionally, it has two or three canals in the mesial roots and one, two or three canals in the distal root. If three canals are present in the mesial root it is known as mesiobuccal (MB), middle mesial (MM) and mesiolingual (ML). Similarly the canals in the distal roots are distobuccal (DB), middle distal (MD) and distolingual (DL).<sup>8</sup> An additional third root may be present in permanent mandibular first molar, in a distolingual (Radix Entomolaris) and rarely in a mesiobuccal location (Radix Paramolaris).<sup>9</sup>

Knowledge of such anatomic variation of root and root canals is essential during the treatment of the patients presenting with morphological diversities in their root canal anatomy.

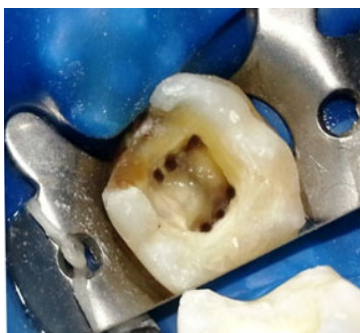
## CASE-REPORT

A 35-year-old female patient with a noncontributory medical history was referred to the Department of Conservative Dentistry and Endodontics for endodontic management of the left mandibular first molar (tooth no 36) from the Department of Periodontology and Implantology. She complained of a localized, steadily provoked dull and momentary pain on chewing in her left lower jaw region since last 5-6 months.

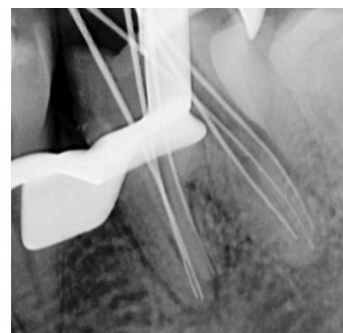The clinical examination of the tooth revealed no swelling or associated sinus tract. The tooth was slightly tender on percussion but there was no tenderness on palpation or associated mobility. The vitality tests (thermal and electric pulp test) showed abnormal responses indicating irreversibly inflamed pulp. The routine intra-oral periapical radiograph revealed radiolucent lesion on mesio-proximal side of the tooth, approximating the pulp. The angular bone loss with a probing pocket depth of approximately 6mm along with the widening of periodontal ligament space in relation to the mesial root was seen in the radiograph. Any morphological variation in the roots or the root canals



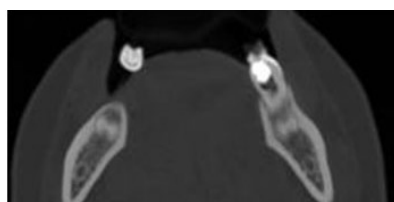
**Figure 1.** Preoperative Radiograph of Tooth # 36.



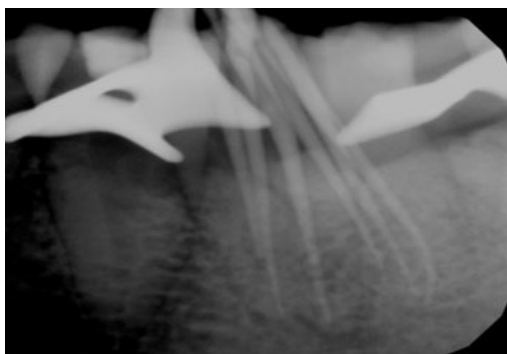
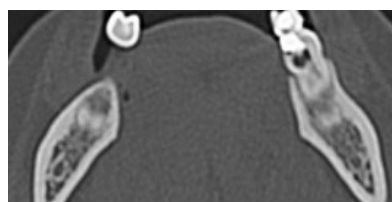
**Figure 2.** Intraoral Photograph Showing Floor of the Pulp Chamber with Three Distal and Three Mesial Canal Orifices.



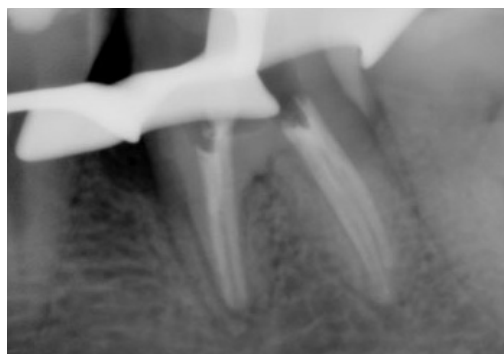
**Figure 3.** Periapical Radiograph for Determination of Working Length Showing Three Roots and Six Canals.



**Figure 4 and 5.** Computed Tomographic Images of Tooth # 36.



**Figure 6.** Master Cone Radiograph.



**Figure 7.** Post Obturation Radiograph.

was not revealed (Fig 1). Clinical and radiographic findings lead to a diagnosis of symptomatic apical periodontitis, indicating the need for endodontic therapy.

The tooth was anesthetized using two percent lignocaine with 1:80,000 adrenaline and isolated under rubber dam. After removal of all carious tissue, access cavity with a straight line access was prepared using endodontic access bur (Dentsply Maillefer). The pulp chamber was flushed with 2.5% sodium hypochlorite to remove the debris. Careful exploration of the pulp chamber floor with endodontic explorer (DG 16 probe, Dentsply) revealed six canal orifices, three mesially (mesiobuccal, middle mesial and mesiolingual) and three distally (distobuccal, middle distal and distolingual) (Fig 2). The patency of the canals was checked with number 10 K-file (Mani, Inc.Japan). The intraoral periapical radiograph for the determination of working length further divulged the presence of three independent roots, two on mesial side and one on distal and six canals (Fig 3).

In order to ascertain the presence of middle mesial and middle distal canals, computed tomography (CT) scan was planned. After obtaining the informed consent from the patient, CT scan of the mandible was done and processed

using Dentascan, Dental Software (GE healthcare, USA). However, the CT only revealed the presence of the three mesial and three distal canals but could not reveal the course of canal anatomy (Fig 4 and 5).

Cleaning and shaping of the canals was completed using hand Protaper files till F2 (Maillefer, Dentsply) under copious irrigation with 2.5% sodium hypochlorite solution and 17% EDTA solution to remove the smear layer. The canals were then dried with paper points and filled with calcium hydroxide paste using a lentulo spiral. The tooth was then temporized with temporary filling material (Cavition, Septodont).

Patient was recalled after 10 days and temporary restoration was removed under rubber dam isolation. The root canals were irrigated with normal saline and stirred with number 25 K file (Maillefer Dentsply) to remove the intracanal medicament. Final irrigation of the canals was done with 2.5% sodium hypochlorite and then 17% EDTA solution. Gutta-percha cones were inserted in dried root canals to reconfirm the working lengths. The angled radiograph was taken which revealed the presence three roots and six canals (Fig 6). Obturation was then performed with Protaper guttapercha cones (Dentsply) and zinc oxide-eugenol-

based sealer (Endofill, Dentsply). Postoperative radiograph was then taken to assess the quality of obturation (Fig 7). Temporary restoration was then placed and patient was recalled for appropriate coronal restoration.

## DISCUSSION

While performing a root canal therapy, clinician must not tend to perceive a concept of predetermined number of roots and/or canals for a given tooth. There are number of literatures available to prove that deviations in tooth morphology are not uncommon.<sup>1,3,4,6,7</sup> Anatomical variation can lead to missed canals resulting in a treatment failure in considerable number of cases. Occasionally mandibular molars presents with Radix Entomolaris (RE) and rarely with Radix Paramolaris (RP). These extra roots are usually small and more curved.<sup>9</sup> Some authors consider RE as a genetic trait with a very high incidence of >30% in Mongoloid. In these ethnic groups RE can be considered as a normal morphological variant.<sup>5,10</sup> In 1948, Visser observed RP has a very rare occurrence with the prevalence of 0% for the first mandibular molar, 0.5% for the second and 2% for the third molar.<sup>11</sup> However, more recently literatures are available with the presence of RP in mandibular first molars.<sup>12,13</sup>

Root canal configuration of mandibular first molar with two distal canals varies from 20% to 46% in different populations.<sup>14</sup> Although there is a paucity of literature reporting the occurrence of middle distal canal in mandibular molars, few articles are available with the anatomic variation of the distal root with three separate canals.<sup>15-17</sup> The presence of three distal canals in mandibular first molar have been reported to be 1.7% in Indian population, 1.7% in Turkish population, 0.7% in Burmese population, 1.6% in Thai population, 0.2% in Senegalese population, and 3% in Sudanese population.<sup>18</sup>

Vertucci et al reported the presence of middle mesial canal as the extra canal present in the mesial root.<sup>19</sup> A radiographic study done by Goel et al in extracted mandibular molars has shown the presence of three mesial canals in 13.3%, four mesial canals in 3.3%, and three distal canals in 1.7% of mandibular first molars.<sup>20</sup> The incidence of middle mesial canal in the mesial root of mandibular first molar is found to be 1-15%.<sup>1</sup> In a clinical evaluation of 145 mandibular first molars, Fabra-Campos H found four molars (2.07%) with the presence of five canals, three in the mesial root with middle mesial canal and two in the distal root.<sup>7</sup> The middle mesial canal found in these four cases didn't show an independent course and foramen. However, Puri S et al in 2011 reported two cases of mandibular first molar with three independent mesial canals.<sup>21</sup> Similar cases of three independent mesial canals in mandibular first and second molars have been reported in the studies done by Beatty R and Pomeranz et al.<sup>4,22</sup> Similarly, Martinez-Bema A and Bandanelli P has reported two cases with six canals and Reeh ES has reported a case with seven canals in a

mandibular first molar.<sup>23,24</sup>

Radiograph and/or other diagnostic images help clinicians in detecting the variations present in both root and root canal anatomy. It has been recommended that two diagnostic radiograph be taken, one ortho radial radiograph and the other taken either 300 mesially or distally depending upon the location of the tooth that is being examined.<sup>25</sup> Angled radiograph, 20° from mesial and 20° from distal, buccolingually reveal the tooth's anatomy and root canal system. Tagger et al suggested that the clinician should always suspect and search for the presence of extra canals whenever the instrument demonstrates an eccentric direction on deeper penetration.<sup>26</sup> This is known as directional control. This case is a rare morphological variant of Mandibular first molar with MM canal originated in a separate orifice near to mesiolingual canal orifice but got joined in the middle third and terminated separately through apical foramina, while MD canal was seen as a separate independent canal throughout the root. Angled radiograph that was taken in order to locate and confirm the extra roots and canals along with their paths revealed the presence of 3 roots and 6 canals. However in cases where radiographs are not clear or direct visualization of the internal anatomy is not possible or impaired, the use of magnification devices or/ and enhancement of color contrast by means of dye is recommended.

## CONCLUSION

It is mandatory for a clinician to become aware of morphological and anatomical deviation that might be present in particular tooth. Along with the identification of the number of roots present and the correct location and the number of canals present, thorough debridement, cleaning, shaping and three dimensional hermetic sealing of the entire root canal system are indispensable procedures for the long term success of the root canal treatment. Thus, every clinician should keep these possibilities in mind in order to locate deeply seated canal orifices during root canal treatment.

## REFERENCES

1. Baugh D, Wallace J. Middle mesial canal of the mandibular first molar: a case report and literature review. *J Endod.* 2004 Mar;30(3):185-6.
2. de Pablo OV, Estevez R, Peix Sanchez M, Heilborn C, Cohenca N. Root anatomy and canal configuration of the permanent mandibular first molar: a systematic review. *J Endod.* 2010 Dec;36(12):1919-31.
3. Al-Qudah AA, Awawdeh LA. Root and canal morphology of mandibular first and second molar teeth in a Jordanian population. *Int Endod J.* 2009 Sep;42(9):775-84.
4. Beatty RG, Krell K. Mandibular molars with five canals: report of two cases. *J Am Dent Assoc.* 1987 Jun;114(6):802-4.
5. Curzon ME, Curzon JA. Three-rooted mandibular molars in the Keewatin Eskimo. *J Can Dent Assoc (Tor).* 1971 Feb;37(2):71-2.

6. de Pablo OV, Estevez R, Heilborn C, Cohenca N. Root anatomy and canal configuration of the permanent mandibular first molar: clinical implications and recommendations. *Quintessence Int.* 2012 Jan;43(1):15-27.
7. Fabra-Campos H. Unusual root anatomy of mandibular first molars. *J Endod.* 1985 Dec;11(12):568-72.
8. Cohen S, Hargreaves KM. Pathways of the pulp. 10th edn. St. Louis, Mo.: Elsevier Mosby; 2010.
9. Nagaven NB, Umashankara KV. Radix entomolaris and paramolaris in children: a review of the literature. *J Indian Soc Pedod Prev Dent.* 2012 Apr-Jun;30(2):94-102.
10. Walker RT. Root form and canal anatomy of mandibular second molars in a southern Chinese population. *J Endod.* 1988 Jul;14(7):325-9.
11. Visser JB. Beitrag zur Kenntnis der menschlichen Zahnwurzelformen. Hilversum: Rotting; 1948. p. 49-72.
12. Carlsen O, Alexandersen V. Radix entomolaris: identification and morphology. *Scan J Dent Res.* 1990; 98:363-73.
13. Sperber GH, Moreau JL. Study of the number of roots and canals in Senegalese first permanent mandibular molars. *Int Endod J.* 1998; 31:112-6.
14. Gulabivala K, Aung TH, Alavi A, Ng YL. Root and canal morphology of Burmese mandibular molars. *Int Endod J.* 2001 Jul;34(5):359-70.
15. Chandra SS, Rajasekaran M, Shankar P, Insider R. Endodontic management of a mandibular first molar with three distal canals confirmed with the aid of spiral computerized tomography: a case report. *Oral Surg Oral Med Oral Pathol Oral Radiol Endod.* 2009 Oct;108(4):77-81.
16. W. F. Stroner, N. A. Remeikis, and G. B. Carr. Mandibular first molar with three distal canals. *Oral Surgery Oral Medicine and Oral Pathology.* 1984;57(5):554-557.
17. Vijay Reddy Venumuddala, M. Sridhar, M. Rajasekaran, Saravanan Poorni, and Gnanaprakasam Senthilkumaran: Endodontic Management of Mandibular First Molar with Middle Distal Canal: A Case Report: Case Reports in Dentistry. 2012;458079:4.
18. Kottoor J, Sudha R, Velmurugan N. Middle distal canal of the mandibular first molar: a case report and literature review. *Int Endod J.* 2010 Aug;43(8):714-22.
19. Vertucci FJ. Root canal anatomy of the human permanent teeth. *Oral Surg Oral Med Oral Pathol.* 1984 Nov;58(5):589-99.
20. Goel NK, Gill KS, Taneja JR. Study of root canals configuration in mandibular first permanent molar. *J Indian Soc Pedod Prev Dent.* 1991 Mar;8(1):12-4.
21. Puri S KCP, Mihir Pandya, Kruti Patel. Mandibular first molar with multiple canals report of two cases. *International Journal of Dental Clinics.* 2011;3(1):94-5.
22. Pomeranz HH, Eidelman DL, Goldberg MG. Treatment considerations of the middle mesial canal of mandibular first and second molars. *J Endod.* 1981 Dec;7(12):565-8.
23. Martinez-Berna A, Badanelli P. Mandibular first molar with six root canals. *J Endod.* 1985;11:348-52.
24. Reeh ES. Seven canals in a lower first molar. *J Endod.* 1998 Jul;24(7):497-9.
25. Pecora JD WJ, Sousa-Neto MD, Issa EP. Morphology study of the maxillary molars. Part II: internal anatomy. *Braz Dent J.* 1992;3: 53-7.
26. Tagger M, Tamse A, Katz A, Korzen BH. Evaluation of the apical seal produced by a hybrid root canal filling method, combining lateral condensation and thermatic compaction. *J Endod.* 1984 Jul;10(7):299-303.