

Vertical Gaze Palsy with Skew Deviation

Pokharel BR, Thapa LJ, Paudel R, Rana PVS

Department of Neurology

College of Medical sciences

Bharatpur, Chitwan

Nepal

Corresponding Author

Babu Ram Pokharel

Department of Neurology

College of Medical sciences

Bharatpur, Chitwan

Nepal

E-mail: drbrpokh@gmail.com

Citation

Pokharel BR, Thapa LJ, Paudel R, Rana PVS. Vertical Gaze Palsy with Skew Deviation. *Kathmandu Univ Med J* 2013;44(4):342-343.

INTRODUCTION

An eye movement abnormality in which the two eyes move conjugately but have limited movement in one direction is called gaze palsy. It is due to malfunction of one of the "gaze centers" (cortical and brainstem regions responsible for conjugate gaze) or to interruption of the pathways leading from them. Vertical gaze palsies usually result from midbrain damage due either to tumours' or vascular lesions.¹ Less frequent causes include progressive supranuclear palsy' and Niemann-Pick disease, type C.² These gaze palsies have been attributed to associated lesions of vertical eye movement control centers in the rostral midbrain rather than the thalamic injury. The frequent coexistence of both midbrain and paramedian thalamic infarction is related to their vascular supply; a single vessel arising near the top of the basilar may branch to supply both the paramedian region of the thalamus and the rostral medial mesencephalon.³ In patients with

ABSTRACT

With the advancement of neuroradiology, clinical localization followed by radiology, had made neurology more interesting. Vertical gage palsy as presentation cerebrovascular disease is not so common. Vertical gaze palsy usually localizes the lesion to dorsal mid brain. A 56 years male patient presented with sudden onset vertigo, diplopia, transient loss of consciousness and sways toward right side while walking. Clinical examination showed vertical gaze palsy with skew deviation along with swaying towards rt. during walk. MRI brain showed – infarct involving dorsal midbrain at superior colliculus level and medial thalamus

KEY WORDS

Mid brain, skew deviation, thalamus, vertical gaze palsy

infarcts of the midbrain/thalamic junction, clinical features can be correlated with lesion location with the use of MRI.

CASE-REPORT

A 56 years male patient came to OPD with the complaint vertigo while patient was going to bathroom. Vertigo was associated with diplopia, ataxia and tendency to sway towards right side. There was history of transient change in consciousness for 2-5 minutes with spontaneous recovery .General physical examination – Normal, Higher Mental Function – normal, Cranial Nerve - skew deviation, Diplopia – vertical. Convergence – absent, Vertical gaze palsy Horizontal gaze – normal. Motor – Normal. Sensory – Normal Reflexes: Normal. Cerebellar Sign - absent Gait - When patient walks – sways towards right side.

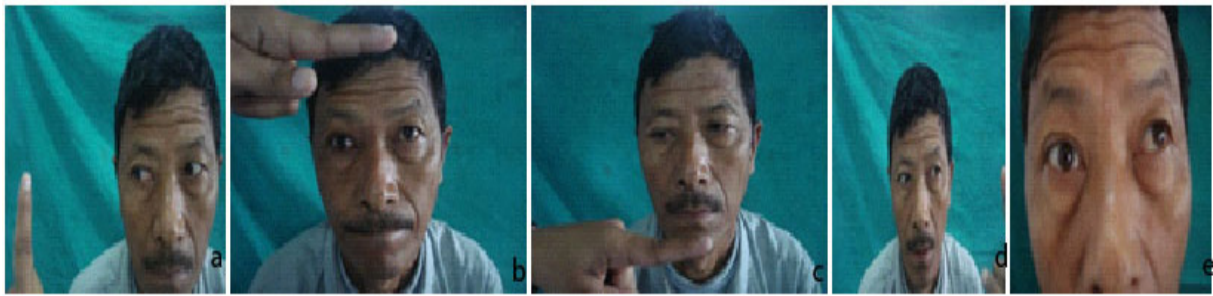

Figure. (a)Gaze to the right,(b)Upward gaze restricted (c) Downward gaze restricted (d) Gaze to the left (e) Skew deviation of the eye.

DISCUSSION

A prominent clinical finding in this patient is vertical gaze palsy (b) and (c) of above picture. However horizontal gaze is normal (a) and (d) picture.(Fig 1) Acute vascular events presenting as vertical gaze palsy and skew deviation is not so common. These patients typically present with upward and downward gaze palsies may be associated with confusion and a decreased level of consciousness. The gaze palsies have been attributed to coexisting lesions of the rostral midbrain.⁴

The neural structures known to be involved in the mediation of vertical gaze lie in the mesencephalic reticular formation. These include the nucleus of Darkschewitsch, the interstitial nucleus of Cajal, and the posterior commissure. Isolated paralysis of downward gaze can also be produced by bilateral lesions of the rostral mesencephalic reticular formation, which includes the interstitial nucleus of the medial longitudinal fasciculus.⁵

The rostral interstitial medial longitudinal fasciculus contains burst neurons for vertical saccades, and in most pathological studies cases of upward and downward gaze paralysis have been attributed to bilateral infarction in the rostral interstitial medial longitudinal fasciculus.⁶

An important clinical feature in our patient was the skew deviation, which has been reported with thalamic infarctions.⁷

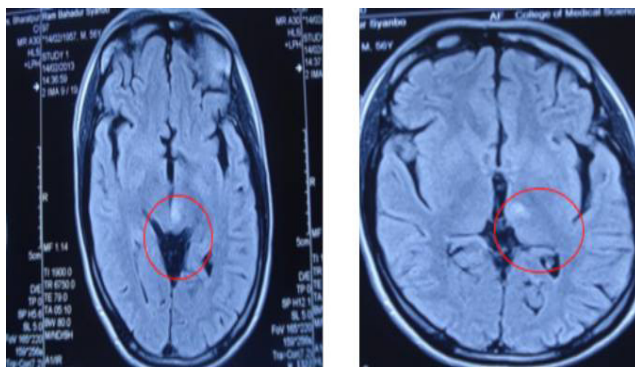


Figure 2. MRI Brain of the Patient Showing Evidence of Acute Infarct mid Brain and Medial Thalamus.

Our case presented with prominent vertical gaze palsy along with skew deviation without any sensory features. On evaluation MRI revealed infarction involving the mid brain dorsal area at the superior colliculus level along with medial thalamus infarct.(Fig 2) This is probably due to the occlusion of the artery arising from the basilar which bifurcated to supply the dorsal mid brain and the medial thalamus. The clinical features of vertical gaze palsy is being explained by mid brain lesion while the skew deviation by medial thalamus. Ischemic stroke presenting as vertical gaze palsy is not so common.

REFERENCES

1. Bender ME. Brain control of conjugate horizontal and vertical eye movements. *Brain* 1980; 103:23-69.
2. Yan- Go FL, Yanagihara T, Pierre RV, Goldstein NP. A progressive neurologic disorder with supranuclear gaze paresis and distinctive bone marrow cells. *Mayo Clin Proc.* 1984; 59:404-10.
3. Castaigne P, Lhermitte F, Buge A, Escourolle R, Hauw J, Lyon-Caen O. Paramedian thalamic and clinical and neuropathological study. *Ann Neurol.*1981;10:127-148
4. Bogouslavsky J, Miklossy J, Deruza JP, Regli F, Assal G. Unilateral left paramedian infarction of the thalamus and midbrain: a clinicopathological study. *J Neurol Neurosurg Psychiatry.* 1986; 49:686-694.
5. Buttner-Ennever J, Buttner U, Cohen B, Baumgartner G. Vertical gaze paralysis and the rostral interstitial nucleus of the medial longitudinal fasciculus. *Brain.* 1982;105:125-149
6. Ranalli PJ, Sharpe JA, Fletcher WA. Palsy of upward and downward saccadic, pursuit, and vestibular movements with a unilateral midbrain lesion: pathophysiologic correlations. *Neurology.* 1988; 38:114-122.
7. Margolin E, Hanifan D, Berger MK, Ahmad OR, Trobe JD, Gebarski SS. Skew deviation as the initial manifestation of left paramedian thalamic infarction. *J Neuroophthalmol.* 2008, 28:283-286.