

Retrospective Study to Determine Stability of Mandibular Setback Surgery using Bilateral Sagittal Split Osteotomy Technique

Upadhyaya C,¹ Chaurasian NK,¹ Kafle D²

¹Department of Oral and Maxillofacial Surgery

²Department of Orthodontics and Dentofacial Orthopedics

Dhulikhel Hospital, Kathmandu University Hospital

Kavre, Nepal.

Corresponding Author

Chandan Upadhyaya

Department of Oral and Maxillofacial Surgery

Dhulikhel Hospital, Kathmandu University Hospital

Kavre, Nepal.

E-mail: updch@yahoo.com

Citation

Upadhyaya C, Chaurasian NK, Kafle D. Retrospective Study to Determine Stability of Mandibular Setback Surgery using Bilateral Sagittal Split Osteotomy Technique - A Study in Nepalese Population. *Kathmandu Univ Med J* 2016; 56(4):301-4.

ABSTRACT

Background

Bilateral sagittal split osteotomy of mandible is one of the most commonly performed orthognathic surgical procedure performed in the mandible. According to hierarchy of stability, mandibular setback procedure is considered to be relatively unstable procedure and chances of relapse are higher.

Objective

We conducted this study to determine the skeletal stability of mandibular setback procedure using bilateral sagittal split osteotomy technique in Nepalese population.

Method

Lateral cephalograms of 14 patients who underwent mandibular setback using bilateral sagittal split osteotomy were taken pre-operatively (P1), immediate post-operatively (P2) and eight months to one year post-operatively (P3). Cephalometric tracing was done for all the cephalograms. Various parameters of Burstone's hard and soft tissue, Steiner's and McNamara analysis were used in the study to determine angular and linear changes following surgery. After tracing the cephalograms, changes between P1- P2, P1-P3 and P2-P3 were calculated. Mean difference in changes between P1-P2, P1-P3 and P2-P3 were compared using paired t test. P value less than 0.05 was considered to be significant. Data analysis was done using SPSS software version 20.

Result

Mean setback at Pogonion was 3.03 mm whereas at point B were 4.64 mm. Relapse at Pogonion was 0.03 mm and relapse at point B were 0.02 mm. Mean change in point A-Nasion-point B angle was 5.1 degrees whereas mean changes in NA-Pogonion angle were 4.69 degrees.

Conclusion

There were significant changes in angular as well as horizontal parameters at P2 but there were no significant changes in those parameters at P3. This is a preliminary study that we have carried out at our institution with smaller sample size thus we recommend a study with larger sample size and long term follow up.

KEY WORDS

Bilateral sagittal split osteotomy, mandibular setback, stability

INTRODUCTION

Bilateral sagittal split osteotomy (BSSO) of mandible is one of the most commonly performed orthognathic surgical procedure performed in the mandible. BSSO can be used for either mandibular setback or advancement depending upon the type of deformity. The first BSSO was performed by Trauner and Obweggser in 1953 but it was reported in the literature only in 1957.¹ Since then many modifications of the original procedure has been reported in the literature.^{2,3} Of the various modification, Hunshuck/Epker modification involves variation in lingual cut in which lingual cut ends just posterior to the lingual without extending to the posterior border of ramus as in original technique.^{4,5} The versatility of the BSSO allows it to be used for the congenital and acquired defect resulting in mandibular prognathism, mandibular retrognathism or facial asymmetry. It is used either alone or in combination with other maxillary and mandibular orthognathic surgical procedure. However, according to hierarchy of stability, mandibular setback procedure is considered to be relatively unstable procedure and chances of relapse are higher.⁶ According to Profitt, chances of relapse are higher in the first postoperative year and most of the relapse occurs in first month after surgery.⁶ Various studies have been carried out to determine the stability after BSSO but no such studies have been carried out in Nepalese population till date. Our institution is only the centre in Nepal where we have been performing orthognathic surgery since 2010 on a regular basis. Thus we conducted this study to determine the skeletal stability of mandibular setback procedure using BSSO technique.

METHODS

The study was conducted after obtaining approval from institutional review board of our institute. This study was carried out using lateral cephalograms of 14 patients who underwent mandibular setback procedure using BSSO technique at our institute. After BSSO, fixation was achieved using bicortical screws using extra-oral incision and trocar. Lateral cephalograms were taken pre-operatively (P1), immediate post-operatively (P2) and eight months to one year post-operatively (P3). Cephalometric tracing was done for all the cephalograms. Various parameters of Burstone's hard and soft tissue, Steiner's and McNamara analysis were used in the study to determine angular and linear changes following surgery (fig. 1 and table 1). After tracing the cephalograms, changes between P1- P2, P1-P3 and P2-P3 were calculated. Mean difference in changes between P1-P2, P1-P3 and P2-P3 were compared using paired t test. P value less than 0.05 was considered to be significant.

Data analysis was done using SPSS software version 20. Standard deviation with mean was calculated and compared using paired sample t test. P value less than 0.05 was considered to be significant.

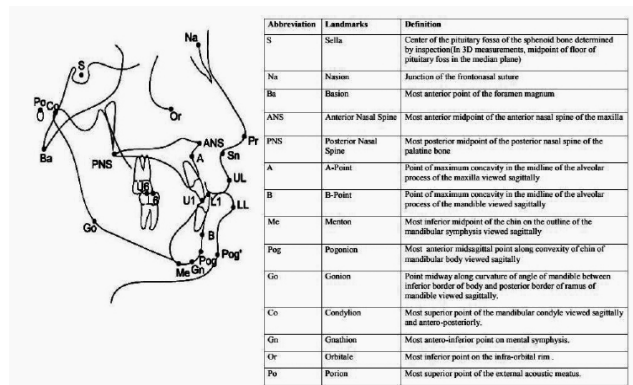


Figure 1. Cephalometric landmarks

Table 1. Various parameters used for cephalometric analysis

Angular parameters	Horizontal parameters
N-A-Pogonion (Angle of convexity)	N-B
MP-HP angle	N-Pog
ANB angle	ANS-Gn
SN-Pog	Go-Pog
Ar-Go-Gn	

RESULTS

The total number of patients who underwent mandibular setback using BSSO was 14. The numbers of male patients were nine and female patients were five. The mean age of the patients was 21.7 (21.78±2.29) years. Mean follow up period was 9.2 months. Mean setback at Pogonion was 3.03 mm whereas at point B were 4.64 mm. relapse at Pogonion was 0.03 mm and relapse at point B were 0.02 mm. Mean change in ANB angle was 5.1 degrees whereas mean changes in NA-Pogonion angle were 4.69 degrees. Angular skeletal changes and horizontal skeletal changes at P1, P2 and P3 are shown in table 2 and 3. There were significant changes in angular as well as horizontal parameters at P2 but there were no significant changes in those parameters at P3.

DISCUSSION

Mandibular setback using BSSO is carried out in patients with class III malocclusion. This surgical procedure dramatically improves the esthetics as well as function post-operatively in patients with class III malocclusion. However mandibular setback is considered to be unstable according to hierarchy of stability in long term. ANB angle and NA-Pogonion angle which are considered to be angle of convexity shows a significant change following setback surgery in the patients. This is confirmed from our study. We can see that there was a significant change in degree of ANB angle as well as NA-Pogonion angle after mandibular setback surgery using BSSO. Some amount of relapse have been noted at P3 but those were not statistically significant (P>0.05). This is in contrast to the study carried out by Mobarak etal and Darshan etal.^{7,8} Similarly mean

Table 2. Comparison of angular parameters at P1, P2 and P3.

Parameters	P1±SD	P2±SD	P3±SD	P1-P2	P value*	P1-P3	P value*	P2-P3	P value
ANB	-3.31±0.38	1.79±0.68	1.8±0.68	-5.1	<0.001	-5.11	<0.001	-0.01	>0.05*
NA-Pog	3.22±0.41	1.47±0.88	1.49±0.89	-4.69	<0.001	-4.71	<0.001	-0.02	>0.05*
MP-HP	37.52±4.99	34.4±7.22	34.41±7.21	3.12	<0.001	3.11	<0.001	-0.01	>0.05*
SN-Pog	81.39±3.26	77.34±4.12	77.35±4.18	4.05	<0.001	4.04	<0.001	-0.01	>0.05*
Ar-Go-Gn	137.65±1.72	132.23±5.17	132.239±5.17	5.42	<0.001	5.41	<0.001	0.009	>0.05*

*Not significant

Table 3. Comparison of horizontal parameters at P1, P2 and P3.

Horizontal Parameters	P1±SD	P2±SD	P3±SD	P1-P2	P value	P1-P3	P value	P2-P3	% change	P value
N-B	7.78±0.48	3.14±0.24	3.17±0.22	4.64	<0.001	4.61	<0.001	-0.03	0.95	>0.05*
N-Pog	7.18±0.41	4.15±0.44	4.17±0.42	3.03	<0.001	3.01	<0.001	-0.02	0.48	>0.05*
ANS-Gn	87.65±1.13	82±1.05	82.11±1.11	5.65	<0.001	5.54	<0.001	-0.11	0.13	>0.05*
Go-Pog	91.72±0.85	85.87±1.58	85.88±1.58	5.85	<0.001	5.84	<0.001	-0.01	0.01	>0.05*

*Not significant

relapse at point B and point Pogonion was also not found to be significant. At P3, percentage of relapse at point B was found to be 0.95 whereas that at point Pogonion was found to be 0.33. This is in contrast to study by Mobarak et al carried out in 2000. In their study, relapse at point B was 19% whereas that at point Pogonion was 21% but these changes were 3 years post-operatively.⁷ In our study, the analysis was carried at around one year following surgery which could be the reason of lesser percentage of relapse. Joss and Thuer found the relapse to be smaller in setback surgeries compared to the advancement surgeries using BSSO.⁹ They considered stretching of soft tissue around mandible to be the major reason of relapse of advancement surgeries. Positioning of condyle also plays a role in stability of BSSO. It is believed that positioning of condyle back into fossa is easier in setback surgeries as soft around the proximal segment of mandible get compressed and not stretched in setback surgeries.⁹ The position of the condyle is mainly determined by muscle tone and rigidity of capsule. During anesthesia, capsule and muscles around condyle may be hypotonic but when they return to normal tone post-operatively, there may be change in the position of condyle which can lead to relapse and visible malocclusion.^{10,11}

Other various factors have been described to be associated with stability of setback surgery. Method of fixation is one of them. Matsushita et al in their study found that use of intra-oral miniplates with monocortical screws gives better stability than bicortical screw fixation.¹² This however is in contrast to study because we used bicortical screws as a method of fixation in 12 out of 14 cases and the amount of relapse was not significant. The use of bicortical screw has a risk of causing inferior alveolar nerve (IAN) injury which has been confirmed by various studies and these studies

also suggest use of intra-oral miniplates and monocortical screws for fixation.^{13,14} There is another advantage with use of intra-oral miniplates and mono-cortical screw fixation that we do not require extra-oral incision to use trocar.^{15,16} Joss believes that monocortical system lacks sufficient stability and other invitro studies also suggest that bicortical screw fixation have stronger resistance to relapse.¹⁷⁻²⁰ Fixation by method of wires has also been reported and Profitt found that use of wire fixation was more stable.²¹ Borstlap and stoelinga in their study reported 7.1%-47.3% relapse when wire was used for fixation. Similarly when they used rigid internal fixation, the relapse rate increased to 9.8-51.4% which is again in contrast to our study. The percentage of relapse in our study is highly in contrast with other studies and an average relapse of 10% to 20% has been reported in the literature.^{22,23}

Etiology of relapse after setback is multifactorial. Conservative reflection of soft tissue and detachment of pterygo-masseteric sling, failure of masticatory muscles to adapt around the repositioned segments, altered condylar position and inability of the tongue to be accommodated in a short space created by setback of mandible are considered to be major factor responsible for relapse.²⁴ Magnitude of horizontal setback is also very important factor determining the stability of setback surgery. It is believed that greater the advancement or setback, greater are the chances of relapse and usually setback greater than 7 mm have higher chances of relapse.^{10,25} Some authors also suggest that surgical clockwise rotation of ramus segment altering the position of condyle increases the chances of relapse.²⁶

In our study, we found the percentage of relapse to be significantly low which could be attributed to adequate

reflection of soft tissue along with pterygomasseteric sling, proper positioning of condyle into the glenoid fossa, and stability offered by bicortical screw fixation. The amount of setback that we performed was also less than 7 mm in all the cases which also attributed to lesser relapse in our study. However the sample size as well as follow up period was relatively small compared to those studies which have shown higher percentage of relapse. This is also a preliminary study carried out at our institute and we hope to have more accurate data with increase in sample size.

REFERENCES

1. Trauner R, Obwegeser H. The surgical correction of mandibular prognathism and retrognathia with consideration of genioplasty. Part I. Surgical procedures to correct mandibular prognathism and reshaping of the chin, *Oral Surg Oral Med Oral Pathol.* 1957;10(7):677-89.
2. Dal Pont G. Retro-molar osteotomy for correction of prognathism, *J Oral Surg.* 1961;19:42-9.
3. Steinhäuser E. Rückblick auf die Entwicklung der Dysgnathiechirurgie und Ausblick, *Mund-Kiefer- und Gesichtschirurgie.* 2003;(7/6):371-379.
4. Hundshuck EE. A modified intraoral sagittal splitting technic for correction of mandibular prognathism, *J Oral Surg.* 1968;26(4):250-3.
5. Epker BN. Modifications in the sagittal osteotomy of the mandible, *J Oral Surg* 1977;35(2):157-9.
6. Proffit WR, Turvey TA, Phillips C. The hierarchy of stability and predictability in orthognathic surgery with rigid fixation: An update and extension. *Head Face Med.* 2007; 3:21.
7. Mobarak KA, Krogstad O, Espeland L, Lyberg T. Long-term stability of mandibular setback surgery: a follow-up of 80 bilateral sagittal split osteotomy patients. *The International journal of adult orthodontics and orthognathic surgery.* 2000;15(2):83-95.
8. Darshan SV, Ronad YA, Kishore MS, Shetty KS, Rajesh M, Suman SD. Long term stability and relapse following mandibular advancement and mandibular setback surgeries: a cephalometric study: *JIOH.* 2014;6(5):42-6.
9. Joss CU, Thuer UW. Stability of the hard and soft tissue profile after mandibular advancement in sagittal split osteotomies: a longitudinal and long-term follow-up study. *European journal of orthodontics.* 2008;30(1):16-23
10. Borstlap WA, Stoelinga PJ, Hoppenreijts TJ, van't Hof MA. Stabilization of sagittal split advancement osteotomies with miniplates: a prospective, multicentre study with two- year follow-up Part II. Radiographic Parameters. *Int J Oral Maxillofac Surg* 2004;33(6): 535-42.
11. Borstlap WA, Stoelinga PJ, Hoppenreijts TJ, van't Hof MA. Stabilization of sagittal split advancement osteotomies with miniplates: a prospective, multicentre study with two- year follow-up Part I. Clinical Parameters. *Int J Oral Maxillofac Surg* 2004;33(5):433-41.
12. Matsushita Y, Nakakuki K, Kosugi M, Kurohara K, Harada K. Does Intraoral Miniplate Fixation Have Good Postoperative Stability After Sagittal Splitting Ramus Osteotomy? Comparison with Intraoral Bicortical Screw Fixation. *J Oral Maxillofac Surg* 2016;74(1):181-9.
13. Obwegeser HL. Orthognathic surgery and a tale of how three procedures came to be: A letter to the next generations of surgeons. *Clin Plast Surg.* 2007; 34:331.
14. Sato FR, Asprino L, Consani S. Comparative biomechanical and photoelastic evaluation of different fixation techniques of sagittal split ramus osteotomy in mandibular advancement. *J Oral Maxillofac Surg.* 2010; 68:160.
15. Danda AK. Comparison of a single noncompression miniplate versus 2 noncompression miniplates in the treatment of mandibular angle fractures: A prospective, randomized clinical trial. *J Oral Maxillofac Surg.* 2010 68:1565.
16. Cole P, Rottgers SA, Cameron H. Improving the minimally invasive approach to mandible angle repair. *J Craniofac Surg.* 2008; 19: 525.
17. Joss CU, Vassalli IM. Stability after bilateral sagittal split osteotomy setback surgery with rigid internal fixation: A systematic review. *J Oral Maxillofac Surg.* 2008;66:1634.
18. Chuong CJ, Borotikar B, Schwartz-Dabney C. Mechanical characteristics of the mandible after bilateral sagittal split ramus osteotomy: Comparing 2 different fixation techniques. *J Oral Maxillofac Surg.* 2005; 63:68.
19. Fujioka M, Fujii T, Hirano A. Comparative study of mandibular stability after sagittal split osteotomies: Biocortical versus monocortical osteosynthesis. *Cleft Palate Craniofac J.* 2000;37:551.
20. Ochs MW. Bicortical screw stabilization of sagittal split osteotomies. *J Oral Maxillofac Surg.* 2003; 61:1477.
21. Proffit WR, Phillips C, Dann C. Stability after surgical orthodontic correction of skeletal Class III malocclusion. I. Mandibular setback. *Int J Adult Orthod Orthog Surg.* 1991; 6:7.
22. Krekmanov L, Lilja L, Ringqvist M. Sagittal split osteotomy of the mandible without postoperative intermaxillary fixation. A clinical and cephalometric study. *Scand J Plast Reconstr Surg Hand Surg.* 1989; 23:115.
23. Sorokolit CA, Nanda R. Assessment of the stability of mandibular setback procedures with rigid fixation. *J Oral Maxillofac Surg.* 1990; 48:817.
24. Joe IC, Hwai JF, Shou HK. A Retrospective Analysis of the Stability and Relapse of Soft and Hard Tissue Change After Bilateral Sagittal Split Osteotomy for Mandibular Setback of 64 Taiwanese Patients. *J Oral Maxillofac Surg.* 2005; 63:355-361.
25. Arnett GW. A redefinition of bilateral sagittal osteotomy (BSO) advancement relapse. *Am J Orthod Dentofacial Orthop* 1993;104(5):506-15.
26. Borstlap WA, Stoelinga PJ, Hoppenreijts TJ, van't Hof MA. Stabilization of sagittal split setback osteotomies with miniplates: a prospective, multicentre study with two- year follow-up. *Int J Oral Maxillofac Surg* 2005;34(5):487-494.

CONCLUSION

There is a significant change in skeletal profile after mandibular setback using bilateral sagittal split osteotomy surgery and percentage of relapse after setback is low. This is a preliminary study that we have carried out at our institution with smaller sample size thus we recommend a study with larger sample size and long term follow up.