

Variable Presentations of Sinonasal Polypoid Masses: A Tertiary Institution Experience

Dutta M,¹ Ghatak S,² Sen I,³ Sinha R¹

¹Department of ENT and Head - Neck Surgery
Medical College and Hospital
Kolkata, West Bengal, India.

²Department of ENT and Head-Neck Surgery
College of Medicine and Sagore Dutta Hospital
Kolkata, West Bengal, India.

³Department of ENT and Head-Neck Surgery
Midnapore Medical College and Hospital
Midnapore, West Bengal, India.

Corresponding Author

Mainak Dutta
Department of ENT and Head-Neck Surgery
Medical College and Hospital
88, College Street, Kolkata - 700073
West Bengal, India.
Email: duttamainak@yahoo.com

Citation

Dutta M, Ghatak S, Sen I, Sinha R. Variable Presentations of Sinonasal Polypoid Masses: A Tertiary Institution Experience. *Kathmandu Univ Med J* 2016; 56(4):322-7.

ABSTRACT

Background

Lesions of the sinonasal area are varied, but they mostly present as polypoid masses which require meticulous work-up to reach at the most probable diagnosis.

Objective

Analysis of polypoid sinonasal masses in terms of etiology, clinical presentations, brief demographic profile, clinico-histologic correlate where possible, and follow-up results.

Method

In this descriptive, longitudinal study, 198 patients with polypoid sinonasal masses attending the otolaryngology clinic of a tertiary teaching institute were selected using proper selection criteria and analyzed through a pre-set proforma and algorithm for a diagnostic work-up (that included histopathology where necessary).

Result

Common presentations were nasal obstruction (~89%), discharge (~70%) and hyposmia (~22%). Though nearly 87% was clinically benign and 8% indeterminate, therapeutic and diagnostic interventions (including histopathology) showed 91% truly benign, of which polyposis formed the bulk. Sensitivity of clinical detection was 75% for benign lesions and 62% for malignancies. Diagnosis depended on histopathology in 52.52% cases, including the clinically malignant, the "grey zone", and more than 40% of the clinically benign lesions. There was male predilection (2.16 for benign lesions and 1.57 for malignant), rural preponderance, and above 60% of the patients were within 50-70 years. There was ~26% recurrence in the follow-up period of a minimum of one year, predominantly in polyposis (29.55%) and malignancies (~39%).

Conclusion

Presentations of polypoid sinonasal masses are variable, etiology of which is mostly benign. Proper clinico-histologic correlate is necessary for correct diagnosis. A low threshold of suspicion is required because of this variability, necessitating follow-up for further evaluation.

KEY WORDS

Histopathology, nasal obstruction, polypoid mass, presentation, sinonasal

INTRODUCTION

Nasal polyp (Gk; poly = many, pous = footed) by definition is the edematous, hypertrophied mucosa of the nose and the paranasal sinuses and refers to ethmoidal polyps (nasal polyposis) if not stated otherwise.¹ However, there are hosts of other pathologic entities involving the nose and paranasal sinuses with polypoid presentation; and not all of them are polyps in the truest sense. For the clinician, it often becomes impossible to distinguish them with the help of history and imaging and find out their etiology. Hence, a combination of clinics and histopathology becomes necessary for diagnosis. In this study, the presentations of the polypoid sinonasal masses have been analyzed and a comparative analysis between the clinical and subsequent tissue diagnosis where necessary has been attempted.

METHODS

The study was performed in the department of ENT and Head-Neck Surgery, R. G. Kar Medical College and Hospital, Kolkata, a tertiary-level Government teaching institution, from April 2008 to March 2013. The cross-sectional study design had two sections (Fig. 1) - one for the selection of patients (from April 2008 to March 2012), and the rest for follow-up, thus adding a prospective component too. The follow-up period for an individual patient did therefore vary, and there had been considerable overlap between the two sections. However, a minimum of one year follow-up period was maintained. One hundred and ninety-eight patients presenting with sinonasal polypoid mass were selected according to the following selection criteria:

Inclusion criteria - a) age range from two to 70 years, b) the nasal mass assuming a polypoid look in gross appearance (both unilateral and bilateral lesions were included); **Exclusion criteria** - a) age <two years and >70 years, b) associated comorbidities like diabetes mellitus, hypertension and other systemic disorders like coagulation abnormalities and infections, c) epistaxis secondary to hypertension or coagulation disorders, d) history of recurrence at first presentation.

Exclusion of the extremes of ages reduced the difficulties encountered due to irregular follow-up and to some extent decreased the load of associated comorbidities. For example, an elderly hypertensive male subject with coincidental sinonasal polyposis presenting with epistaxis might rake up suspicion of malignancy if not the history of hypertension be excluded thoroughly. Coagulation defects and systemic infections might present similarly creating confusion. Patients with polyps with a history of recurrence have also been excluded from the study to add clarity to our plan of management and in the subsequent follow-up sessions.

Each patient selected was put through a pre-designed proforma [vide Appendix] which provided his/

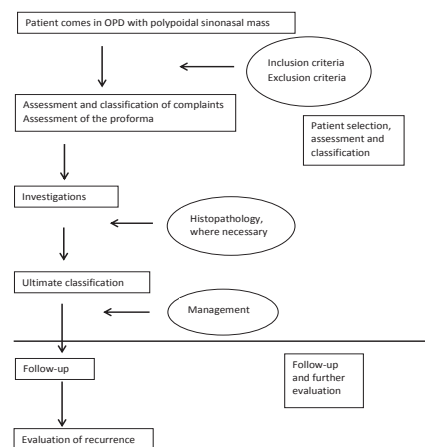


Figure 1. Overview of the methodology followed in the study.

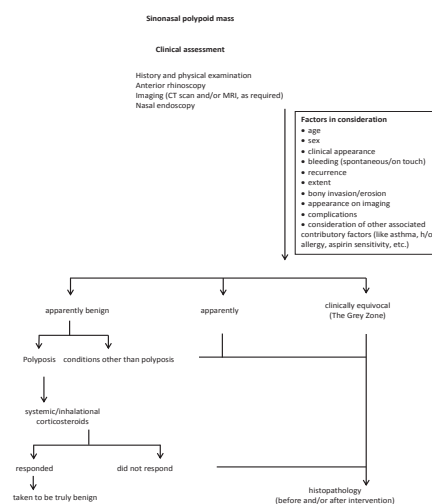


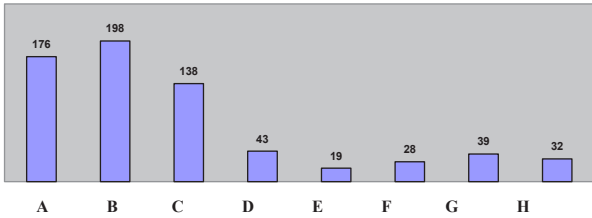
Figure 2. The figure shows the algorithm for approach to diagnosis in a patient presenting with polypoid sinonasal mass.

her details and gave a subjective analysis of his/her clinical presentation. This helped in the assessment and classification of complaints and provided an idea regarding the nature of the presenting lesions. Next, he/she was put through a series of tests [routine hemogram, nasal endoscopy, CT scan and/or MRI, biopsy (wherever applicable/felt necessary)] for a subjective evaluation from the observer’s point of view. Tissue diagnosis was attempted before initiating treatment in clinically suspicious cases and those with equivocal presentations to confirm the provisional diagnosis, and following surgical interventions (where needed) as excisional biopsy. History, presenting complaints and clinical evaluation aided by investigations and histopathology in suitable situations were combined following an algorithm leading to the diagnosis of sinonasal polypoid masses (Fig. 2).

Each patient was followed up for a minimum of one year. Recurrences were noted, and their possible causes evaluated retrospectively. The results have been calculated with basic statistical applications like percentages and proportions, and data was extracted from the composite grand chart put in the Microsoft Excel software.

RESULTS

Considering the nasal mass (or the sensation of fullness) as the yardstick, 138 of the 198 patients evaluated (69.7%) had nasal discharge and 43 (21.72%) complained of diminished or absent smell (fig. 3). Airway obstruction was present in 176 of them (88.89%), but not in all. Pain



A = sensation of nasal obstruction
 B = polypoid mass/sensation of fullness
 C = discharge
 D = hyposmia/anosmia
 E = epistaxis
 F = pain
 G = rhinolalia
 H = cosmesis

Figure 3. The figure shows a comparative representation of presenting complaints of the patients presenting with sinonasal polypoid masses.

and epistaxis were present in 28 (14.14%) and 19 subjects (9.6%) respectively. Though external deformity due to mass effect was often encountered, complaints related to cosmesis were relatively lesser (16.16%).

Clinically, 173 cases (87.37%) were considered benign, 9(4.54%) malignant, and as many as 16(8%) were in the “grey zone” of equivalence (fig. 4, Table 1). Out of the 173 clinically benign lesions, 126(72.83%) were provisionally taken as benign inflammatory polyps (polyposis), seven as fungal sinusitis, 10 as rhinosporidiosis, and eight as lesions of non-specific/other etiologies (Table 1). The clinically diagnosed polyposis lesions were put on systemic/intranasal corticosteroid therapy, of which 106 responded.

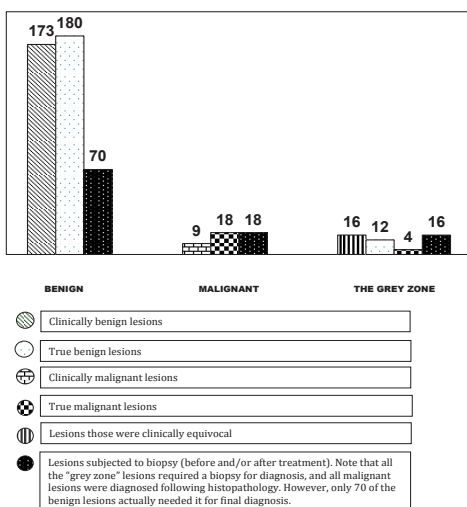


Figure 4. The role of clinics and histopathology in the classification of sinonasal polypoid masses has been presented here in this comparative diagram.

Table 1. The table shows the detailed classification of patients presenting with sinonasal polypoid masses.

CLINICAL	FINAL
Benign	Benign
Polyposis = 126;20*(2)	Polyposis = 132
Choanal polyps = 9	Choanal polyps = 11
Meningocele = 4	Meningocele = 4
Rhinosporidiosis = 10	Rhinosporidiosis = 10
Fungal sinusitis = 7*	Fungal sinusitis = 8
Hemangioma = 7	Hemangioma = 7
JNA = 2	JNA = 2
Undecided (clinically benign)=8*(5)	Others (localized inflammatory polyps with infections) = 6
Malignant	Malignant
9* (7)	Non-Hodgkin’s lymphoma = 2
The “Grey Zone”	Inverted papilloma = 1
16* (4)	Mucosal malignant melanoma =1
	Squamous cell carcinoma = 10
	Adenocarcinoma = 4

JNA = juvenile nasopharyngeal angiofibroma
 N. B.: 1) Figures in parenthesis in the CLINICAL section denote number of cases that ultimately proved malignant.
 2) Figures with asterisk (*) indicate lesions subjected to histopathology before initiation of definitive treatment. These included the 20 cases of clinical polyposis found resistant to corticosteroid therapy.

Dataset: The dataset shows the proportions and sensitivities of the clinical diagnosis of polypoid sinonasal masses.
 Histopathologic examination required for the clinically evaluated sinonasal masses [CH] =60
 Of them, true benign lesions = 42, true malignant lesions =18
 Proportion of true benign lesions among the CH =(42/60)x100=70%
 Proportion of true malignant lesions among the CH =(18/60)x100=30%
 Sensitivity of clinical detection of benign lesions =[42/(42+12)]x100 =75%
 Sensitivity of clinical detection of malignant lesions =[18/(18+7+4)]x 100=62.07%
 (Sensitivity calculations included the Grey Zone lesions)

Table 2. Analysis of the gender and social background of the patients presenting with sinonasal polypoid masses reveals a male preponderance and rural predilection.

PATIENT CHARACTERISTICS	BENIGN	MALIGNANT
Male	123	11
Female	57	7
Rural	128	10
Urban/Industrial	52	8

All the fungal lesions (seven), the suspected polyposis not responding to steroids (20), the clinically malignant lesions (nine) and the so-called “grey zone” (16) were among the 60 lesions that were subjected to histopathology before initiation of definitive treatment (Table 1).

The final composition of the cases studied revealed 180 truly benign lesions (91%); the rest 18 were malignant (Table 1), with a ratio of 10: 1 in favor benignity. While all malignant lesions had to be confirmed by histopathology, only 70 of the benign lesions (i.e., ~38.89%) needed it for final diagnosis (fig. 4). Sensitivity of clinical detection of

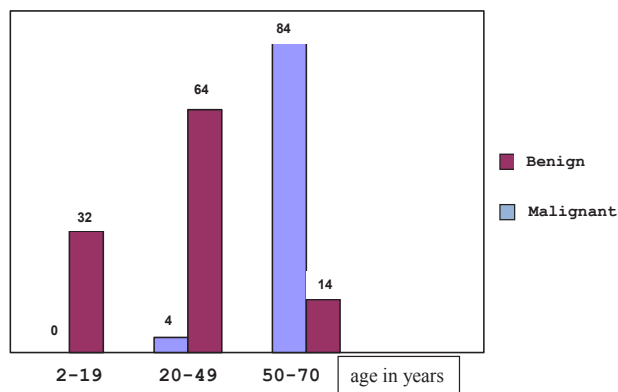


Figure 5. The figure shows the age distribution between the benign and malignant sinonasal polypoid masses.

benign lesions was 75% and that for the malignant lesions 62.07% [Dataset]. Overall, 104 of the 198 subjects (52.52%) required histopathologic examination at some point of time to confirm or diagnose the original nature of the lesion (Fig. 4), of which 60 (30.3%) were before the initiation of definitive treatment (Table 1). Eighty-four of the benign lesions and 14 of the malignant (i.e., ~46.67% and 77.78%, respectively) were in the category of 50-70 years age group (Fig. 5), with a male predilection (2.16 for benign, 1.57 for malignant) and rural preponderance (~71.1% of benign and 55.5% of malignant lesions) (Table 2).

Following a minimum of one year follow-up, the recurrence rate was 26.26% (i.e., 52 out of 198). Attempts to find the causes of recurrence revealed a scope to analyze the intrinsic pathophysiology of the lesions and their management profile. The case-wise split of the recurrences (Fig. 6) revealed ~29.55% relapse among polyposis, and ~38.89% among the malignancies.

DISCUSSION

In this study, in spite of a visible polypoid mass in the nose (by anterior rhinoscopy and nasal endoscopy) or a subjective sensation of fullness, more than 11% of patients did not have a sensation of nasal obstruction (decreased airflow/nasal blockage) as the primary complaint (fig. 3). This was chiefly due to incomplete occlusive effect of the mass, the on-off phenomenon of mucosal inflammation (especially in polyposis, because of the inherent pathology and self-medication), and the neoplastic lesions primarily involving the paranasal sinuses. Moreover, ~30% of the subjects had no symptom of nasal discharge that could have caused nasal obstruction. This establishes the fact that although chronic rhinosinusitis and nasal polyposis are manifestations of the same disease process in continuum, existence of one in the absence of the other is not uncommon.^{2,3} Besides, recent ideas contest the cause-effect relationship between mechanical obstruction in nasal cavity and the sensation of nasal obstruction, the latter being related more to the complex dynamics of airflow in the nose in terms of contact of air with mucosa in a way that is still poorly understood.⁴

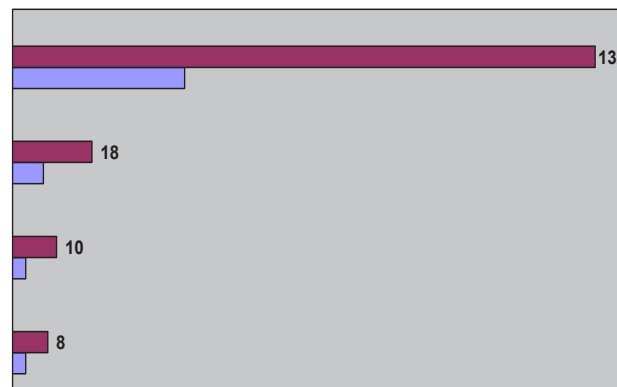


Figure 6. The figure shows a comparative split among the recurred cases. The blue color indicates the recurrence in each case.

Whereas in some literature hyposmia/anosmia has been said to be a more common presentation,² we have found only a little less than 22% of patients having such problem. Cosmesis did not constitute a sizeable fraction of the complaint-chart, probably because of the rural background of most of the patients under evaluation.

It is evident from the results that although most of the lesions were benign, there was proportionate increase in the incidence of malignancy with age.^{1,5} Also there was a definite male preponderance in both benign and malignant categories, keeping with the established world literature.¹ Though patients with benign lesions were mainly from rural background, malignancies were seen proportionately more in the urban segment (Table 2). There was a proportionate increase in fungal sinusitis with each year of our study with a growing urban predilection. Rhinosporidiosis was also found to be prevalent in eastern India (where the study was done), though it is known to be more common in the southern Indian states and Sri Lanka.⁵

The present study attempted to explore the clinico-histopathologic correlate of the sinonasal polypoid masses. The term clinical implied entities preliminary to the stage of tissue diagnosis, including meticulous history-taking, proper assessment of the presenting complaints, clinical examinations (anterior rhinoscopy, nasal endoscopy), followed by imaging (CT and/or MRI). Interestingly, there was gross disparity between the proportion of benign and malignant lesions assumed clinically and on histopathology. Of the 173 clinically benign lesions, 166 (96%) were confirmed as truly benign from histopathology and empirical treatment (steroids in nasal polyposis); similarly, seven out of the nine clinically malignant lesions were truly malignant (78%) (Table 1). This reflects an overdependence on the clinical parameters to reach at a diagnosis. However, when only cases subjected to histopathology were considered, the proportion of true benign lesions dropped to 70%, and of the true malignant lesions at 30% [Dataset]. When the clinically “grey zone” was included, the sensitivity of clinical detection of benign and malignant lesions were 75% and 62% respectively [Dataset]. This indicates the importance of histopathology

(tissue diagnosis) in determining the true nature of lesions. The apparent aberration with clinical evaluation was because not all cases deemed clinically benign were put to biopsy. Polypoid lesions considered as polyposis by history and clinical examinations were empirically treated with local/systemic corticosteroids.¹ Twenty did not respond, of which one came out to be mucosal malignant melanoma and one as non-Hodgkin's lymphoma of nasal cavity. Moreover, the "grey zone" when considered reduced the overall sensitivity of clinical detection.

A significant finding that emerged from the present study was the clinically misleading presentations of malignant lesions (Table 1). Out of the 18 polypoid lesions ultimately diagnosed as malignant, 7 were initially considered benign, including two cases of non-Hodgkin's lymphoma and one mucosal malignant melanoma of nasal cavity. However, it is true that malignant lesions are often detected late as they may get confused in their clinical presentations with the more common benign lesions including polyposis.^{6,7} Adenocarcinoma and squamous cell carcinomas of nasal cavity and paranasal sinuses, along with mucosal malignant melanoma,^{6,8,9} non-Hodgkin's lymphoma and inverted papilloma on the other hand may present at times with a polypoid look.^{10,11} There may also be perilesional edema which may be misdiagnosed as polypoid adding to the clinical dilemma. In this context the benign lesions are also not exceptions. The nine clinically suspected malignant lesions ultimately yielded two genuine benign entities (Table 1). One of them was a unilateral sinonasal mass in a 23 year old boy with massive bone destruction involving the medial wall of maxilla and nasal septum requiring a medial maxillectomy, but finally diagnosed as a benign inflammatory polyp. The 12 benign cases initially grouped into the "grey zone" were found to be comprised of six infective polyps with ulcerations and fungation, two antrochoanal polyps with occasional epistaxis in patients in their seventies, and one case of fungal mass with unusually grave osseous destruction. The remaining four in the "grey zone" were found to be malignant. It becomes evident – the point that deserves repeated re-affirmation – that every sinonasal polypoid mass with considerable clinical doubt should be considered for histopathology for a definitive diagnosis and to formulate the treatment plan.¹²

There were as many as six cases encountered in our study that need special mention owing to their rarity and uniqueness. One of them was a sphenchoanal polyp diagnosed in a 15 year old boy presenting with a sinonasal mass and epistaxis. With an apparent belief as an entity often under-reported, an isolated sphenchoanal polyp is still considered rare.¹³ Also there was an adult patient with bilateral antrochoanal polyp; till now, only three cases of bilateral antrochoanal polyp have been documented.¹⁴ We also had a 36 year old farmer with a pale polypoid nasal mass later diagnosed to be mucosal malignant melanoma – an entity that constitutes 0.67% of malignant melanomas in the body.¹⁵ Apart from the two cases of midline granuloma

of nose (T-cell/non-Hodgkin's lymphoma), there was a 24 year old woman with a grossly destructive, exophytic unilateral polypoid sinonasal mass later confirmed as inverted papilloma.

Almost a quarter of the nasal polypoid masses recurred in the minimum of one year follow-up. The bulk formed benign inflammatory polyps but more than 13% were malignant. Probable explanations could be the chronicity,¹⁶ and mild nature of the polyposis lesions true to their intrinsic pathology.¹⁷ Incomplete surgical removal at the microscopic level and subsequent metastasis could be the possible reasons for recurrence of malignant lesions. We have in our records a case of a 23 year old female patient diagnosed with adenocarcinoma of nasal cavity that later developed ovarian carcinoma following a 5 year symptom-free period after successful excision of the nasal mass by lateral rhinotomy approach. The association was later revealed clinically and histologically to be synchronous indicating a probable syndromic disorder requiring genetic analysis for further confirmation.

This study would have been more complete if the follow-up period could have been extended. The treatment aspect of individual cases has been deliberately omitted here, but the recurrence of the polypoid sinonasal masses could have been better comprehended had the treatment outlines been considered in details. A further study waits in future that would describe the result of the primary management of these polypoid masses of the sinonasal tract in the long term by retrospective record-review of the patient details obtained in successive follow-up sessions. Moreover, the proforma could have been improved had the "allergy" factor been incorporated in to the analysis of history of the patients; this could help us evaluate the association between allergy/atopy and polyposis or fungal sinusitis.^{1,18-21} In such case, there could have been scope to classify the "fungal sinusitis" lesions, especially to find out the proportion of allergic fungal rhinosinusitis. However, evaluation of radioallergosorbent test (RAST) and serum immunoglobulin E were beyond the scope of the present study.

Again, since the study was based on a single institution experience, it might have a regional bias in the patient profile and the ultimate disease classification. That incidence of diabetes mellitus, hypertension and coagulation disorders have uneven distribution in different parts of the world, the population sample under review in the present study might not be representative of that of the world. More elaborative statistical studies like a meta-analysis would have been more suitable to analyze the variability of the polypoid sinonasal masses; but given the heterogeneous and unpredictable nature of human disorders, such effort would only be a better approximation, rather than be accurate.

CONCLUSION

The present study shows the clinical and histologic variations in patients presenting with sinonasal polypoid masses with an attempt to compare the efficacy of the two, and it is wise to accept from the evident resources that a surgeon-clinician cannot afford to have one without the other to

get the true idea about these variations. A high index of suspicion however is required; observations regarding the patient profile and variable presentations would aid in the process. A stringent follow-up schedule also leaves the scope of retrospection, apart from highlighting the inadequacy of our understanding of the sinonasal polypoid masses.

REFERENCES

1. Mygind N, Lund VJ. Nasal Polyposis. In: Scott-Brown's Otorhinolaryngology, Head and Neck Surgery. 7th Ed. Gleeson M et al. (Eds.). London: Hodder Arnold; 2008. Vol.2, Ch. 121, p1549.
2. Schlosser RJ, Woodworth BA. Chronic Rhinosinusitis and Polyposis. In: Ballenger's Otorhinolaryngology, Head and Neck Surgery. 17th ed., Snow JB Jr., Wackym PA (Eds.). Shelton: People's Medical Publishing House; 2009. 47, p575.
3. Larsen PL, Tos M. Origin of Nasal Polyps: An endoscopic autopsy study. *Laryngoscope* 2004; 114(4): 710-9.
4. Olphen AVF. The septum. In: Scott-Brown's Otorhinolaryngology, Head and Neck Surgery. 7th Ed. Gleeson M. et al (Eds.). London: Hodder Arnold; 2008. Vol.2, Ch. 123, p1575.
5. Morelli L, Polce M, Pisciolli F, Del Nonno F, Covello R, Brenna A, et al. Human nasal rhinosporidiosis: an Italian case report. *Diagn Pathol* 2006; 1:25 [doi: 10.1186/1746-1596-1-25]. <http://www.diagnosticpathology.org/content/1/1/25> (accessed: 8th September, 2013)
6. McMonagle BA, Gleeson M. Nasal cavity and paranasal sinus malignancy. In: Scott-Brown's Otorhinolaryngology, Head and Neck Surgery. 7th Ed. Gleeson M. et al (Eds.). London: Hodder Arnold; 2008. Vol.2, Ch. 186, p2417.
7. Chavda SV, Olliff JFC. The Sinuses. In: Textbook of Radiology and Imaging. 7th Ed. David Sutton (Ed.). Edinburgh: Churchill Livingstone; 2003. Vol. 2, Ch. 48, p1527.
8. Intestinal type (enteric) adenocarcinoma; Nasal cavity, paranasal sinuses, nasopharynx; www.pathologyoutlines.com/nasal.html. (accessed: 8th September, 2013).
9. Jones SA. Mucosal malignant melanoma. In: Scott-Brown's Otorhinolaryngology, Head and Neck Surgery. 7th Ed. Gleeson M et al (Eds.). London: Hodder Arnold; 2008 Vol.2, Ch. 185, p2407.
10. Chavda SV, Olliff JFC. The Sinuses. In: Textbook of Radiology and Imaging. 7th Ed. David Sutton (Ed.). Edinburgh: Churchill Livingstone; 2003. Vol. 2, Ch. 48, p1528.
11. Wieneke JA, Koeller KK. Head Neck Pathol Radiology Pathology Classics. *Head Neck Pathol* 2007; 1: 99-101.
12. Diamantopoulos II, Jones NS, Lowe J. All nasal polyps need histological examination: an audit-based appraisal of clinical practice. *J Laryngol Otol* 2000; 114(10): 755-9.
13. Jadia S, Goyal R, Biswas R. Nasal mass mimicking antrochoanal polyp. *BMJ Case Rep* 2010; April 12 [doi: 10.1136/bcr.12.2009.2578].
14. Yilmaz YF, Titz A, Ozcan M, Tezer MS, Ozlugedik S, Unal A. Bilateral antrochoanal polyps in an adult: a case report. *B-ENT* 2007;3(2):97-9.
15. Lewis MG, Martin JA. Malignant melanoma of the nasal cavity in Ugandan Africans. Relationship of ectopic pigmentation. *Cancer* 1967; 20(10): 1699-705.
16. Vento SI, Ertama LO, Hytonen ML, Wolff CHJ, Malmberg CHO. Nasal polyposis: Clinical course during 20 years. *Ann Allergy Asthma Immunol* 2000; 85: 209-14.
17. Larsen K, Tos M. Clinical course of patients with primary nasal polyps. *Acta Otolaryngol* 1994; 114(5): 556-9.
18. Denberg J. Nasal polyposis: Cytokines and inflammatory cells. In: Mygind N, Lildholdt T. (Eds.). Nasal polyposis: An inflammatory disease and its treatment. *Copenhagen: Munksgaard*, 1997: 78-87.
19. Cody DT 2nd, Neel HB 3rd, Ferreiro JA, Roberts GD. Allergic fungal sinusitis: The Mayo Clinic experience. *Laryngoscope* 1994; 104(9): 1074-9.
20. Bent JP 3rd, Kuhn FA. Diagnosis of allergic fungal sinusitis. *Otolaryngol Head Neck Surg* 1994; 111(5): 580-8.
21. Keith PK, Conway M, Evans S, Wong S, Jordana G, Pengelly D et al. Nasal polyposis: effects of seasonal allergen exposure. *J Allergy Clin Immunol* 1994; 93(3): 567-74.