

Thyroid Isthmus Agenesis in a Patient with Papillary Carcinoma of Thyroid

Rajbhandari P, Shrestha BL, Dhakal A, Amatya RCM

Department of Otorhinolaryngology and Head and Neck Surgery

Dhulikhel Hospital, Kathmandu University Hospital

Dhulikhek, Kavre.

Corresponding Author

Pradeep Rajbhandari.

Department of ENT-HNS

Dhulikhel Hospital, Kathmandu University Hospital,

Dhulikhek, Kavre.

E-mail: drprajbhandari@gmail.com

Citation

Rajbhandari P, Shrestha BL, Dhakal A, Amatya RCM. Thyroid Isthmus Agenesis in a Patient with Papillary Carcinoma of Thyroid. *Kathmandu Univ Med J* 2016; 56(4):373-5.

INTRODUCTION

The thyroid gland is reddish brown and a highly vascular endocrine gland located at the anterior region of the neck. It is placed between the fifth cervical and first thoracic vertebrae. The gland consists of two lobes connected by an isthmus which is protected by infrathyroid muscles. The isthmus is localized at the level of the second and third tracheal rings. The gland tissue is about 25 g in weight and produces hormones triiodothyronine, tetraiodothyronine, which play important roles in normal metabolic activity of the human body. Thyroid gland itself has chances of developmental anomalies. Hemi-agenesis of thyroid and thyroid isthmus agenesis have been rarely seen.¹ The incidence varies in literature from 3-10% but still the true figure is unknown.²⁻⁴ However the combination of thyroid

ABSTRACT

Thyroid gland is the largest of all endocrine glands. It is composed of two lobes. These two lobes are joined by an isthmus and this resemble the letter "H". A wide range of morphological variations and developmental anomalies of the thyroid gland like hypoplasia, ectopy, hemiagenesis, and agenesis have been reported in literature. Out of these, the incidence of agenesis of the thyroid isthmus is rare, and very few cases have been reported. In our report, 28 year old male patient was found with agenesis of thyroid isthmus with papillary carcinoma in the right lobe of thyroid. During the operation it was seen that the right and left thyroid lobes were independent from each other and isthmus was absent. We will present a case of thyroid isthmus agenesis and discuss the clinical importance and the incidence of this case.

KEY WORDS

Agenesis, papillary carcinoma, thyroid gland

isthmus agenesis with papillary carcinoma is very rare as we have encountered the case during our clinical practice.

CASE REPORTS

A 28 year old male presented to ENT, OPD with right anterior neck solitary nodule with no other specific complains. On his physical examination a solitary nodule was seen arising from right lobe of thyroid gland, measuring around 1.5 cm in diameter without regional lymphadenopathy. The ultrasonography exam showed a heteroechoic lesion measuring 20x12 mm in right lobe of thyroid with hypoechoic outline and increased vascularity within (Fig. 1). Left lobe appear normal with no mentioning

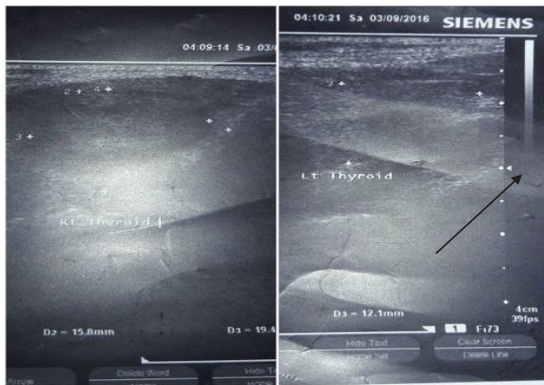

Figure 1. Showing right and left lobe of thyroid gland with absent isthmus.

about isthmus in ultrasonographic report. Fine-needle aspiration cytology was performed which was suggestive of Papillary carcinoma of right lobe of thyroid. Thyroid function test and other preoperative blood parameters were within normal limit. For the treatment, the patient underwent total thyroidectomy. During surgery, isthmus was absent, right and left lobes of thyroid gland were completely separated due to isthmus agenesis. (Fig. 2) Right lobe of thyroid measured 5x3x2 cm. External surface was brownish in colour with firm consistency. Left thyroid lobe measured 4.5x3x1.5 cm. External surface was smooth and brownish in colour. Histopathological report of the specimen was consistent with well differentiated Papillary Carcinoma of right lobe of Thyroid gland and lymphocytic thyroiditis of left lobe of thyroid. His post-operative period was uneventful. Patient was discharged on seventh post operative day and he is under regular follow up.

DISCUSSION

Thyroidectomy is commonly performed surgical procedure in otolaryngology clinical practice for various diseases. Agenesis of thyroid isthmus is a rare developmental anomaly. True incidence of isolated thyroid isthmus agenesis is difficult to find out as majority of persons having such problem is asymptomatic and they do not come to physicians as they have normal levels of thyroid hormones.⁵

In different studies, the prevalence of the thyroid hemiagenesis ranged between 0.05- 0.2%. It is most commonly seen in women and left lobe agenesis is commonly seen.⁶⁻⁸ Study performed by Ranade et al. on 105 cadavers showed that the isthmus was absent in 35 (33%) of them.⁴ Likewise, study performed by Won and Chung² showed that the both lobe of thyroid was separate and there was not isthmus lobe in 3% of the cases. Study performed by Mirkosch et al. showed that isthmus lobe was absent in 10 cases out of 715 cases.⁹

The main reason behind the isolated isthmus agenesis has not been known clearly. However It is thought that the

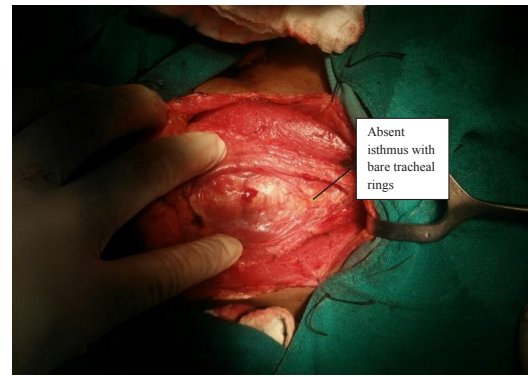


Figure 2. Showing intra-operative findings of absent isthmus with bare tracheal ring.

defect responsible for the thyroid hemiagenesis is failure of descent or from defects in lobulation of gland. The absence of a compensatory growth can explain that lobulation defect is the cause. Genetic mutation has been involved in thyroid morphogenesis.¹⁰ Genetic factors (mutation in TITF 1-2 genes and chromosome 22) and defects in embryological development (failure of the isthmus fusion in the midline) seem to play an important role in thyroid isthmus agenesis.^{11,12}

The thyroid isthmus agenesis is uncommon, and also association with papillary carcinoma is very rare. We recognized the absence of isthmus incidentally during total thyroidectomy surgery for papillary carcinoma of right lobe of thyroid gland. Thyroid isthmus agenesis is not a situation which surgeons often encounter. Thyroid isthmus agenesis does not cause clinical symptoms by itself and most of the times the diagnosis is incidental due to the co-existence of other thyroid pathology.¹³ When USG is done carefully, isthmus agenesis can be seen and this can help in surgery.⁶ Ultrasonography is still the key investigation to diagnose isthmus agenesis but the presence of other pathological conditions diverts the attention and misleads the diagnosis. USG and scintigraphy imaging methods can identify the isthmus agenesis preoperatively so that peroperative surprise and possible complications can be avoided.

Thyroid isthmus agenesis in most of the times is incidental finding due to the co- existence of other thyroid pathology. When agenesis of the isthmus is found, its association with agenesis of the thyroid lobe or ectopic thyroid tissue must be kept in mind. Moreover, diseases such as autoimmune thyroid nodule, thyroiditis, primary thyroid carcinoma, metastasis, and amyloidosis must be considered in the differential diagnosis. The determination of agenesis of the isthmus and other thyroid anomalies during preoperative assessment in the patients for whom thyroid surgery is planned, would contribute significantly to safer surgical procedures and relatively lesser surgery-related complications.

REFERENCES

1. Paneni ST, Soni S, Noman SS, Ali MI, Adil S. Agenesis of the Isthmus of the thyroid with right lateral thyreoglandularis. *JEMDS*. 2013;2(9): 45-6.
2. Won H, Chung I. Morphologic variations of the thyroid gland in Korean adults. *Korean J Phys Anthropol*. 2002;15(2):119-25.
3. Marshall CF. Variation in the form of the thyroid in man. *Journal of anatomy and physiology*. 1895;29:234-9.
4. Ranade AV, Rai R, Pai MM, Nayak SR, Prakash, Krishnamurthy A, et al. Anatomical variation of the thyroid gland: possible surgical implications. *Singapore Med J*. 2008;49(10):831-4.
5. Moore KL, Persaud TVN, Torchia MG. The developing human: clinically oriented embryology. 9th ed. Philadelphia: Saunders Elsevier;2011.
6. Gürsoy A, Anıl C, Ünal AD, Demirer AN, Tütüncü NB. Clinical and epidemiological characteristics of thyroid hemiagenesis. Ultrasound screening in patients with thyroid disease and normal population. *Endocrine*. 2008;33(3):338- 41.
7. Pena S, Robertson H, Walvekar RR. Thyroid hemiagenesis. Report of a case and review of literature. *Indian J Otolaryngol Head Neck Surg* 2011;63(2):198-200.
8. Wu YH, Wein RO, Carter B. Thyroid hemiagenesis. A case series and review of the literature. *Am J Otolaryngol* 2012;33(3):299-02.
9. Mikosch P, Gallowitsch HJ, Kresnik E, Molnar M, Gomez I, Lind P. Thyroid hemiagenesis in an endemic goiter area diagnosed by ultrasonography: Report of sixteen patients. *Thyroid*. 1999;9: 1075-84.
10. Karaby N, Comlekci A, Canda MS, Bayraktar F, Degirmenci B. Thyroid hemiagenesis with multinodular goiter: A case report and review of the literature. *Endocr J*. 2003;50:409-13.
11. Devi Sankar K, Sharmila Bhanu P, Bapuji P. Agenesis of isthmus of thyroid gland with embryological and clinical basis. *NMJ*. 2012;1(1):32-4.
12. Gangbo F, Lacombe D, Alberti EM, Taine L, Saura R, Carles DN. Trisomy 22 with thyroid isthmus agenesis and absent gall bladder. *Genetic Counseling*. 2004;15(3):311-5.
13. Melnick JC, Stemkowski PE. Thyroid hemiagenesis (hockey stick sign):review of world literature and report of four cases. *J Clin Endocrino Metab*, 1981;52:247-51.