

# Correlation between Preoperative High Resolution Computed Tomography (CT) Findings with Surgical Findings in Chronic Otitis Media (COM) Squamosal Type

Karki S, Pokharel M, Suwal S, Poudel R

Department of Radiodiagnosis and Imaging  
Kathmandu University School of Medical Sciences  
Dhulikhel Hospital, Kathmandu University Hospital  
Dhulikhel Hospital, Kavre, Nepal.

## Corresponding Author

Subindra Karki  
Department of Radiodiagnosis and Imaging  
Kathmandu University School of Medical Sciences  
Dhulikhel Hospital, Kathmandu University Hospital  
Dhulikhel Hospital, Kavre, Nepal.  
E-mail: subindrakarki@gmail.com

## Citation

Karki S, Pokharel M, Suwal S, Poudel R. Correlation between Preoperative High Resolution Computed Tomography (CT) Findings with Surgical Findings in Chronic Otitis Media (COM) Squamosal Type. *Kathmandu Univ Med J* 2017;57(1):83-6.

## ABSTRACT

### Background

The exact role of High resolution computed tomography (HRCT) temporal bone in preoperative assessment of Chronic suppurative otitis media atticofacial disease still remains controversial.

### Objective

To evaluate the role of high resolution computed tomography temporal bone in Chronic suppurative otitis media atticofacial disease and to compare preoperative computed tomographic findings with intra-operative findings.

### Method

Prospective, analytical study conducted among 65 patients with chronic suppurative otitis media atticofacial disease in Department of Radiodiagnosis, Kathmandu University Dhulikhel Hospital between January 2015 to July 2016. The operative findings were compared with results of imaging. The parameters of comparison were erosion of ossicles, scutum, facial canal, lateral semicircular canal, sigmoid and tegmen plate along with extension of disease to sinus tympani and facial recess. Sensitivity, specificity, negative predictive value, positive predictive values were calculated.

### Result

High resolution computed tomography temporal bone offered sensitivity (Se) and specificity (Sp) of 100% for visualization of sigmoid and tegmen plate erosion. The performance of HRCT in detecting malleus (Se=100%, Sp=95.23%), incus (Se=100%,Sp=80.48%) and stapes (Se=96.55%, Sp=71.42%) erosion was excellent. It offered precise information about facial canal erosion (Se=100%, Sp=75%), scutum erosion (Se=100%, Sp=96.87%) and extension of disease to facial recess and sinus tympani (Se=83.33%,Sp=100%). high resolution computed tomography showed specificity of 100% for lateral semicircular canal erosion (Sp=100%) but with low sensitivity (Se=53.84%).

### Conclusion

The findings of high resolution computed tomography and intra-operative findings were well comparable except for lateral semicircular canal erosion. high resolution computed tomography temporal bone acts as a road map for surgeon to identify the extent of disease, plan for appropriate procedure that is required and prepare for potential complications that can be encountered during surgery.

## KEY WORDS

*Cholesteatoma, high resolution computed tomography, temporal bone*

## INTRODUCTION

Chronic otitis media atticoid disease remains a significant health problem in terms of prevalence, economics and sequelae. A variety of standard surgical approaches is currently used for treating it, which are categorized as canal wall up or down approaches.<sup>1</sup>

Historically, surgery for Chronic otitis media has been undertaken with only plain x-rays. Recently, high resolution computed tomography (HRCT) scanning has evolved as the standard imaging technique for temporal bone, but its exact role in preoperative assessment of patients with Chronic otitis media atticoid disease still remains controversial.<sup>2-4</sup>

Many experienced otology surgeons seldom use computed tomography scanning arguing that nature and extent of pathology becomes evident during surgical dissection. Some otologists use it regularly aiming to evaluate the extension of disease, schedule the surgical technique to be adopted and identify potential risk of complications.<sup>5</sup> Others reserve its' utilization for cases in which there is suspicion of complication, recurrence or diagnostic doubt.<sup>6,7</sup>

CT scan findings of acquired cholesteatoma of temporal bone consists of a homogenous soft tissue mass with local bone erosion, middle ear opacification, erosion of scutum, erosion of ossicles, labyrinthine fistula, erosion of fallopian (facial) canal, erosion of tegmen, sigmoid sinus erosion, widening of aditus ad antrum, and automastoidectomy.<sup>8</sup>

Prior knowledge about temporal bone anatomy and the extent of disease may help surgeons plan and choose the appropriate type of the surgery and avoid complications. The aim of this study is to evaluate the role of high HRCT temporal bone in diagnosis of Chronic otitis media atticoid disease and to compare preoperative computed tomographic findings with intra-operative findings.

## METHODS

This was a prospective, analytical study conducted among 65 patients with Chronic otitis media atticoid disease in the Department of Radiodiagnosis, Kathmandu University Hospital, Dhulikhel Hospital, Dhulikhel, Kavre between January 2015 to July 2016. Patients with malignancy of the ear, Chronic otitis media tubotympanic disease, patients unfit for surgery or anesthesia and patients who were pregnant were excluded from the study. Written informed consent was taken and approval for the study was obtained from Kathmandu University School of Medical Sciences Institutional Review Committee. A detail clinical history was taken and proforma was filled up. CT scan was performed in 128 slice Siemens somatom perspective machine. Patient was positioned in supine position and using the parameters-130 kV, 146 mAs, and scan time of 3.5 seconds, a volumetric axial CT scan was taken with

3mm slices thickness from lower margin of external auditory meatus and superiorly upto the arcuate eminence of superior semicircular canal. Multiplanar reconstruction was done using 1mm thin slices with 0.5mm interval and images were obtained in all planes. The scans were studied to identify the different types of anatomical variations separately on each side. Demographic data and radiological findings were reviewed and the obtained data analyzed with IBM SPSS statistical software version 21. Operative procedure performed was Modified radical mastoidectomy. In order to determine the real performance and limitations of HRCT scan, a correlation between operative findings and radiological findings were performed by using Sensitivity (Se), specificity (Sp), negative predictive value (NPV), positive predictive value (PPV) were calculated. The parameters of comparison were ossicular status, status of scutum, facial canal, lateral semicircular canal, tegmen and sigmoid plate, extent of cholesteatoma or granulation tissue to sinus tympani and facial recess.

## RESULTS

Out of 65 patients recruited for the study, 30(46.15%) were male and 35(53.84%) were female. The age of patients ranged from 5 to 57 years (mean age 24.02 years). The socio-demographic data are shown in Table 1. CT showed erosion of malleus in 20(30.79%) patients, but intra operatively it was observed in 21(32.30%) cases. Incus appeared eroded on CT scan in 22(50.76%) of cases, whereas intra operatively it was seen in 41(63.07%). Stapes erosion was reported by CT in 7(10.6%), and similar findings were observed per operatively. Fallopian canal erosion was depicted by CT in 3(4.61%) cases, whereas intra operatively it was seen in 4(6.15%). Extension of disease to facial recess and sinus tympani was observed in CT scan in 5(7.69%) and exactly similar findings were observed during surgery. Scutum erosion was visualized in 34(52.30%) patients in CT, whereas intra operatively it was visualized in 33(50.76%). Erosion of lateral semicircular canal was reported only in 7(10.76%) patients. In contrast, surgical findings confirmed it to be positive in 13(20%) cases. Similarly, sigmoid plate erosion was seen both on CT and during surgery in 2(3.07%) cases.

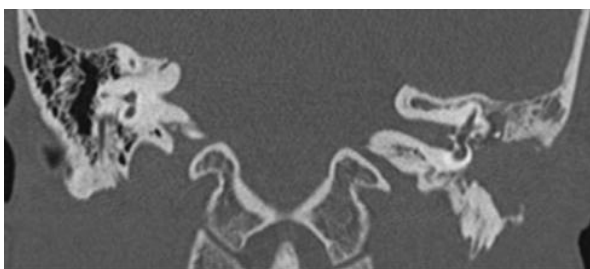**Table 1. Sociodemographic variables**

Variable	Frequency	%	
Sex	Male	30	46.15
	Female	35	53.84
Age	0-15	16	24.61
	16-25	22	33.84
	26-35	15	23.07
	36-45	7	10.76
	46-55	2	3.07
	56-65	3	4.61

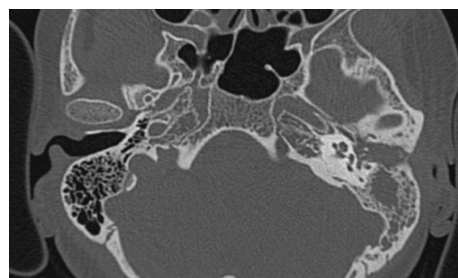
**Table 2.** Comparison between high resolution temporal bone CT findings and intraoperative findings

HRCT Findings	HRCT Finding n(%)	Intra-operative Finding n(%)	Se(%)	Sp(%)	PPV(%)	NPV(%)
Malleus erosion	20(30.79)	21(32.30)	100	95.23	97	100
Incus erosion	33(50.76)	41(63.07)	100	80.48	75	100
Stapes erosion	7(10.76)	7(10.76)	96.55	71.42	96.55	71.42
Facial canal erosion	3(4.61)	4(6.15)	100	75	98.38	100
Extension to sinus tympani and facial recess	5(7.69)	6(9.23)	83.33	100	100	98.33
Erosion of tegmen plate	9(13.84)	9(13.84)	100	100	100	100
Scutum erosion	34(52.30)	33(50.76)	100	96.87	97.05	100
Erosion of Lateral semicircular canal	7(10.76)	13(20)	53.84	100	100	89.65
Sigmoid plate erosion	2(3.07)	2(3.07)	100	100	100	100

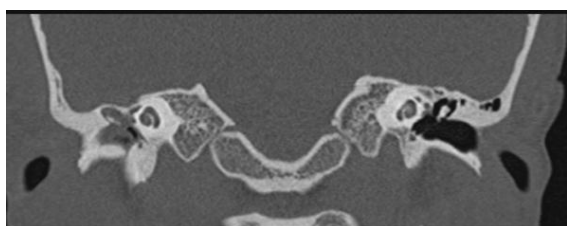Se=Sensitivity,Sp=Specificity,NPV=Negative Predictive value,PPV=Positive predictive value



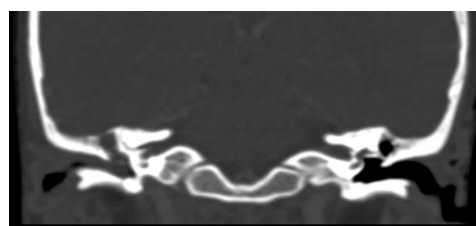**Figure 1.** Coronal HRCT image of temporal bone showing soft tissue opacification at the left external auditory canal extending into tympanic cavity with erosion of inferior wall of external auditory canal, scutum and left incus.



**Figure 2.** Axial HRCT temporal bone image showing soft tissue opacification at left tympanic cavity and mastoid antrum with erosion of left malleus and incus.



**Figure 3.** Coronal HRCT image showing soft tissue opacification at right tympanic cavity with erosion of right incus and right facial canal.



**Figure 4.** Soft tissue opacification within right tympanic cavity ossicular erosion and breach of tegmen plate.

Table 2 shows the comparison between high resolution temporal bone CT findings and intra operative findings along with sensitivity, specificity, positive predictive value and negative predictive value for the different CT findings.

## DISCUSSION

HRCT is considered as imaging modality of choice for anatomical and pathological evaluation of temporal bone, prior to surgery, including chronic otitis media.<sup>9</sup>

In this study, incus was most commonly affected ossicle followed by malleus and stapes. The sensitivity of HRCT for visualization malleus was 100%, incus was also 100% and stapes was 96.55%. Similarly, the specificity of CT scan for detecting malleus erosion was 95.23%, incus erosion was 80.48% and stapes erosion was 71.42%. These findings are consistent with the findings of Chee et al. and in contrast to study by Tatlipinar et al. who observed sensitivity of 62.8% and specificity of 85.7% for the same.<sup>5,10</sup>

In our series, HRCT had a sensitivity of 100% and specificity of 100% with regards to detection of erosion of tegmen plate, which is comparable to study by Jackler et al.<sup>11</sup>

Sirigiri et al., O'Reily et al. and Jackler et al. were able to diagnose dehiscence in the horizontal part of facial canal with a sensitivity of 60% and specificity 90%.<sup>11-13</sup> However, Mafee et al. found CT to be very accurate in the diagnosis of erosion of facial canal.<sup>14</sup> In the present study, erosion of the horizontal part of the facial canal was correctly diagnosed in three cases out of four with a sensitivity of 100% and specificity of 75%.

We found a very impressive 100% sensitivity and 100% specificity of CT scan in detecting sigmoid plate erosion. This finding is similar to study by Rogha et al.<sup>8</sup>

Conversely, Tatlipinar et al. reported a relatively low sensitivity of 33% and specificity of 100%.<sup>5</sup> We had encountered six cases with extensions into sinus tympani and facial recess which was correctly depicted in CT scan in

five cases reporting a sensitivity of 83.33% and specificity of 100%. Our findings are similar to that of Mafee et al.<sup>14</sup>

Variable results have been reported in literature with regard to ability of CT scan in detection of lateral semicircular canal. Rogha and colleagues reported a sensitivity of 75% and specificity of 87.5%.<sup>8</sup> On the other hand, Sirigiri et al. reported a sensitivity of 100% and specificity of 94%.<sup>12</sup> We found that the sensitivity of CT in detecting lateral semicircular canal erosion was 53.84% and specificity was 100%. The variability in impression about lateral semicircular canal fistulization could be due to volume averaging of these structures with adjacent soft tissues. These findings highlight the fact that, although HRCT temporal bone is helpful for diagnosing chronic otitis media, the findings must be interpreted cautiously in view of its' limitations.

The results of our study show that high resolution computed tomography of temporal bone gives precise information about the location and extent of disease. The sinus tympani and facial recess, known as the hidden areas of middle ear, can be easily identified in a HRCT. Information regarding the status of ossicular chain erosion, erosion of lateral semicircular canal and fallopian canal can also be well appreciated by this scan. The delineation of pathology prior to surgical exploration allows the operating surgeon to plan

the most appropriate surgical approach that is required. The information about the possible anatomic variations helps in preparing for the difficulties that might not have been contemplated otherwise. Pre-surgical knowledge about status of ossicular chain also allows the surgeon to be ready for ossicular chain reconstruction and to advise the patient regarding degree of hearing attainable after surgery.

The current study also has some limitations. The limited sample size in this study could have affected the interpretation of the obtained result. Clearly, more studies involving a larger sample size are warranted in future.

## CONCLUSION

The findings of pre-operative high resolution computed tomography findings and intra-operative findings were well comparable except for lateral semicircular canal erosion. High resolution computed tomography temporal bone acts as a gold standard investigation for diagnosis of Chronic otitis media atticofacial disease. It acts as a road map for the surgeon to identify the extent of disease, plan for the appropriate procedure that is required and prepare for the potential complications that can be encountered during surgery.

## REFERENCES

- Olszewska E, Wagner M, Bernal-Sprekelsen M, Ebmeyer J, Dazert S, Hildmann H et al. Etiopathogenesis of cholesteatoma. *Eur Arch Otorhinolaryngol*. 2004 Jan;261(1):6-24.
- Banerjee A, Flood LM, Yates P, Clifford K. Computed tomography in suppurative ear disease: does it influence management? *J Laryngol Otol*. 2003 Jun; 117(6):454-8.
- Schuring AG. Cholesteatoma and imaging. *Am J Otol*. 1991 Sep; 12(5):394-5.
- Walshe P, McConn, Walsh R, Brennan P, Walsh M. The role of computerized tomography in the preoperative assessment of chronic suppurative otitis media. *Clin Otolaryngol Allied Sci*. 2002 Apr; 27(2):95-7.
- Tatlipinar A, Tuncel A, Ögredik EA, Gökçeer T, Uslu C. The role of computed tomography scanning in chronic otitis media. *Eur Arch Otorhinolaryngol*. 2012 Jan;269(1):33-8.
- Yates PD, Flood LM, Banerjee A, Clifford K. CT scanning of middle ear cholesteatoma: what does the surgeon want to know? *Br J Radiol*. 2002 Oct;75(898):847-52.
- Leighton SE, Robson AK, Anslow P, Milford CA. The role of CT imaging in the management of chronic suppurative otitis media. *Clin Otolaryngol Allied Sci*. 1993 Feb; 18(1):23-9.
- Rogha M, Comparison of preoperative temporal bone CT with intraoperative findings in patients with cholesteatoma. *Iran J Otorhinolaryngol*. 2014 Jan;26(74):7-12.
- Shaffer KA, Houghton VM, Wilson CR. High resolution computed tomography of the temporal bone. *Radiology*. 1980 Feb;134(2):409-14.
- Chee NW, Tan TY. The value of pre-operative high resolution CT scans in cholesteatoma surgery. *Singapore Med J*. 2001 Apr;42(4):155-9.
- Jackler RK, Dillon WP, Schindler RA. Computed tomography in suppurative ear disease: a correlation of surgical and radiographic findings. *Laryngoscope*. 1984 Jun; 94(6):746-52.
- Sirigiri RR, Dwaraknath K. Correlative Study of HRCT in Attico-Antral Disease. *Indian J Otolaryngol Head Neck Surg*. 2011 Apr;63(2):155-8.
- O'Reilly BJ, Chevretton EB, Wylie I, Thakkar C, Butler P, Sathanathan N, Morrison GA, Kenyon GS. The value of CT scanning in chronic suppurative otitis media. *J Laryngol Otol*. 1991 Dec;105(12):990-4.
- Mafee MF, Levin BC, Applebaum EL, Campos M, James CF. Cholesteatoma of the middle ear and mastoid. A comparison of CT scan and operative findings. *Otolaryngol Clin North Am*. 1988 May;21(2):265-93.