

Clinico-Pathological Correlation of Colorectal Diseases by Colonoscopy and Biopsy

Makaju R,¹ Amatya M,¹ Sharma S,¹ Dhakal R,¹ Bhandari S,¹ Shrestha S,¹ Gurung R,² Malla BR³

¹Department of Pathology,

²Department of Gastroscopy,

³Department of Surgery,

Dhulikhel Hospital, Kathmandu University Hospital

Dhulikhel, Kavre.

Corresponding Author

Ramesh Makaju

Department of Pathology,

Dhulikhel Hospital, Kathmandu University Hospital,

Dhulikhel, Kavre.

E-mail: makajuram@yahoo.com

Citation

Makaju R, Amatya M, Sharma S, Dhakal R, Bhandari S, Shrestha S et al. Clinico-Pathological Correlation of Colorectal Diseases by Colonoscopy and Biopsy. *Kathmandu Univ Med J* 2017;58(2):173-8.

ABSTRACT

Background

Colonoscopy is a simple, safe and well tolerated procedure, the visualization of the mucosa of the entire colon and terminal ileum to detect intestinal abnormalities and obtain biopsy leads to the early detection of the pathologic process and institution of appropriate therapy.

Objective

To find out the correlation between clinical and histopathological diagnosis of colorectal diseases.

Method

A cross-sectional study was conducted at Department of Pathology, Dhulikhel Hospital, Kathmandu University Hospital from Jan. 2015 - Jan. 2016. Altogether, 95 colonoscopic biopsies were examined and recorded clinical data using pre-designed pro forma. The specimens were grossed, processed and embedded using standard procedures, stained with Hematoxylin and Eosin stain and were analyzed using light microscope. Special stains Ziehl Neelsen, and Periodic Acid-Schiff were used whenever necessary.

Result

Analyses of 95 cases of colonoscopic biopsies were done. The most common clinical diagnosis was polyp in 49 cases (51.57%) and the common histopathological diagnosis was non-neoplastic polyps 31(32.63%). There was no correlation in cases for suspected infectious colitis, microscopic colitis and hemorrhoids.

Conclusion

Colonoscopy is incomplete without biopsy and histopathology is the gold standard for the diagnosis of colorectal lesions. The clinico-pathological correlation for neoplastic lesions was excellent. However, correlation was poor in non-neoplastic lesion.

KEY WORDS

Colonoscopy, colorectal lesions, histopathology

INTRODUCTION

The colon and rectum accounted various diseases which include both non neoplastic and neoplastic conditions. It can be sites for infections, inflammatory bowel diseases, vascular disorders, motor and mechanical conditions and various neoplasm.¹

The development of flexible endoscopes has led to the great increase in the examination and mucosal biopsy evaluation of all portions of the large intestine and rectum.² To facilitate diagnosis of different colorectal lesions, colonoscopy and histopathological examination are complementary. Colonoscopy is incomplete without biopsy and histopathology is gold standard for diagnosis of colonoscopically detected colorectal lesions.³

According to WHO, colorectal cancer is the third most common cancer in men (746,000 cases, 10.0% of the total) and the second in women (614,000 cases, 9.2% of the total) worldwide. Almost 55% of the cases occur in more developed regions but with less mortality than in less developed regions. In South Asian countries the incidence of colorectal cancer in men is 56.66% and in women 48.33%.⁴ However, they are reported to be increasing in economically developing countries including Nepal.⁵ Furthermore, epidemiological change of colorectal cancer has been observed in the past with increased incidence among young.^{6,7}

We aim to investigate the spectrum of colorectal lesions and correlate its diagnosis by colonoscopy and histopathology.

METHODS

A descriptive cross-sectional study was conducted at Department of Pathology, Dhulikhel Hospital, Kathmandu University Hospital from January 2015 to January 2016 after taking ethical approval from local Institutional review committee. All colonoscopic biopsies for histopathological examination were included in this study. However, autolysed and inadequate biopsy specimens were excluded from this study. A total number of 95 colorectal biopsies received were studied. Patients from outpatient and inpatient department who were clinically indicated were enrolled for colonoscopy. The colonoscopy was performed by the senior consultant gastroenterologist and clinical diagnosis was made on gross visualization of the lesions. However, biopsies were sent to Department of Pathology for histopathological examination. Histopathology was performed as per the standard protocol of the hospital. Moreover, age, sex and the positive endoscopic findings related to the patient were also recorded in the pro forma.

Patient's data was entered in Microsoft Excel and descriptive data analysis was done using Statistical Package for Social Sciences (SPSS) 16.0 software.

RESULTS

Total 95 cases were included in the study. The age of the patients was ranging from 12th day of life to 100 years of age with mean age of 41.2 years (Fig 1). Maximum cases were in the age group of 20-39 years (31.58%) whereas minimum cases were in the age greater than 80 years (1.05%). Out of the 95 cases, 67(70.52%) were male and 28 (29.47%) were female with male to female ratio of 2.4:1.

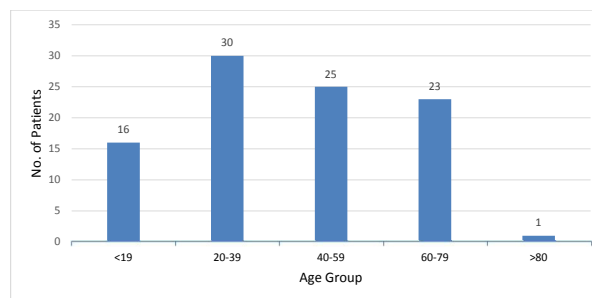


Figure 1. The distribution of the age of the patients.

Most of the biopsies received were from rectum (34.73%) which was followed by sigmoid colon (16.84%).

The colonoscopic findings have shown that more than fifty percent of cases were found to be of polypoid lesions (53.68%: Fig 2 and 3) and ulcerative lesions (21.05%) were the second most common case (Fig 3). However, ulceroproliferative lesions, erosions and edematous cases were also equally present (6.31%).

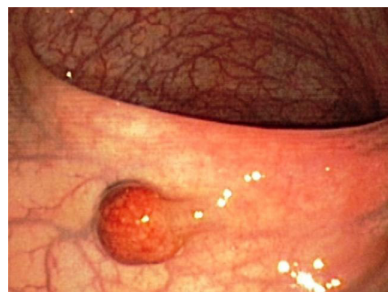

Figure 2. Polypoid lesion shown by colonoscopy.

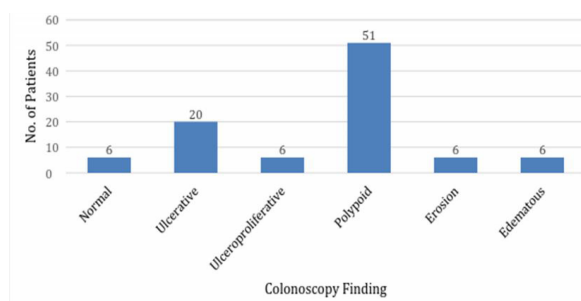


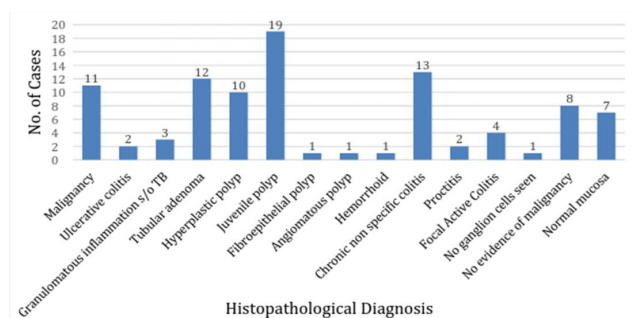
Figure 3. The bar chart showing the colonoscopic findings among the enrolled patients.

On the other hand while considering both clinical history and colonoscopic findings, the most common clinical diagnosis was polyp (51.57%) followed by colitis (12.63%) but Carcinoma of colon (10.53%) cases also cannot be overlooked (Table 1).

Table 1. The distribution of the cases after considering clinical history and colonoscopic findings of the patients (n=95).

Clinical Diagnosis	Number of cases n (%)
Polyp	49(51.57)
Carcinoma colon	10(10.53)
Colitis	11(11.57)
Infectious colitis	8(8.42)
TB colon	7(7.37)
Ulcerative colitis	4(4.21)
Hirschsprung's Disease	1(1.05)
Diabetic gastropathy	1(1.05)
Anal Fissure	1(1.05)
Micorscopic colitis	1(1.05)
Hemorrhoid	1(1.05)

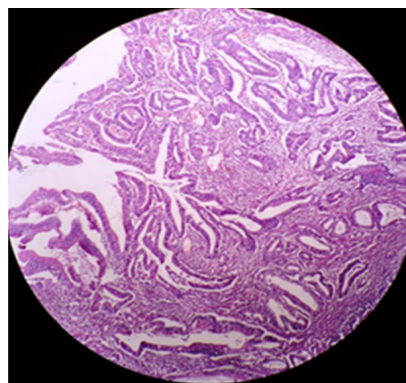
Moreover, the most common case was found to be non-neoplastic polyps (32.63%) after histopathological diagnosis among 95 cases (Fig 3). The second common cases were chronic non-specific colitis (13.68%) and neoplastic polyp (12.63%) cases with 11.58% of malignancy and 3 cases of tuberculosis (Fig. 4).

**Figure 4.** Distribution of cases after histopathological examination (n=95).

Furthermore, while investigating malignancy cases (n=11), all cases were found to be adenocarcinoma. Most of adenocarcinoma was found in the age above 40 years (81.81%) and the highest occurrence in male (72.72%). Microscopic observation revealed that 45.45% cases were well-differentiated adenocarcinoma (Fig. 5) including 36.36% was moderately differentiated adenocarcinoma and 18.18% was poorly differentiated adenocarcinoma. In addition, while relating with their dietary pattern, all the adenocarcinoma cases were found to be non-vegetarian while 81.82% was smokers and 54.55% being smokers.

Correlation between histopathological diagnosis and colonoscopy findings

Out of 44 polypoid lesions in colonoscopy, 43 cases were confirmed as polyp in histopathological examination and one case was diagnosed as Hemorrhoid (Table 2). Similarly, among 20 ulcerative lesions in colonoscopy, on histopathological examination, five cases were malignant, four cases chronic non-specific colitis, four cases normal

**Figure 5.** Well differentiated adenocarcinoma (H and E X100).

mucosa, two cases tuberculosis of colon, two cases ulcerative colitis, two cases focal active colitis and one case proctitis. Further, the histopathological examination revealed five cases of chronic non-specific colitis, three cases of normal mucosa, one case of proctitis and one case of focal active colitis in 10 erosions cases detected by colonoscopy. In the other hand, while relating colonoscopic findings and histopathological examinations, among 8 cases of ulceroproliferative lesions on colonoscopy, 6 cases was of malignant with one case of TB colon and one case of hemorrhoid. Additionally, out of seven edematous lesions on colonoscopy, three cases of chronic non-specific colitis, three cases of normal mucosa and one case of focal active colitis were found during histopathological examinations.

Correlation between histopathological diagnoses with clinical diagnosis

In the effort to correlate histopathological diagnosis and clinical diagnosis, cases were compared (Table 3). Among 11 histopathological proven malignancy cases, 10 cases were suspected as malignancy and one case was suspected as TB colon while among 49 clinically suspected polyp, 43 were confirmed by histopathological examination. The rest five cases suspected as polyp turned out to be two cases as normal, one case as hemorrhoids, one case as chronic non-specific colitis, one case as proctitis and one case as Focal active colitis. Similarly, out of 10 suspected cases of colitis, on histopathological examination six cases normal mucosa, three cases chronic non-specific colitis and one case proctitis. Further, eight cases clinically suspected as Infectious colitis were found to be normal (n=4) and chronic non-specific colitis (n=4) on histopathological examination.

DISCUSSION

Age range of the patient was from neonate to 100 years with mean age of 41.2 years and most of them were male. These findings were similar to findings of Shefali et al. where age range was from 3 years to 87 years with mean age of 56.6 years with male to female ratio of 1.8:1.² Similarly study done by Rangaswamy et al. showed age range from 16-83 years with mean age of 47.78 years with male to female ratio of 1.74:1.⁸ The age range between 20 to 40 years with

Table 2. Correlation between histopathological diagnosis and colonoscopy findings (n=95).

Histodiagnosis/Colonoscopy	Normal	Ulcerative	Ulceroproliferative	Polypoid	Erosion	Edematous
Malignancy		5	6			
Chronic non-specific colitis	1	4			5	3
TB colon		2	1			
Ulcerative colitis		2				
Tubular adenoma				12		
Juvenile Polyp				19		
Hyperplastic polyp				10		
Fibroepithelial polyp				1		
Proctitis		1			1	
Focalactive colitis		2			1	1
Angiomatous polyp				1		
Normal mucosa	4	4	1		3	3
Hemorrhoid				1		
Hirschsprung's	1					

Table 3. Correlation between histopathological diagnosis and clinical diagnosis (n=95).

Diagnosis	Polyp	Ca colon	UC	TB	Hirs	Diabe	Hmd	AF	Mc	Ic	C
Malignancy	0	9	0	2	0	0	0	0	0	0	0
CNSC	1	0	1	0	0	1	0	1	1	4	4
TB colon	0	1	0	2	0	0	0	0	0	0	0
UC	0	0	2	0	0	0	0	0	0	0	0
Tubular Adenoma	12	0	0	0	0	0	0	0	0	0	0
Juvenile Polyp	19	0	0	0	0	0	0	0	0	0	0
Hyperplastic Polyp	10	0	0	0	0	0	0	0	0	0	0
Fibroepithelial Polyp	1	0	0	0	0	0	0	0	0	0	0
Proctitis	1	0	0	0	0	0	0	0	0	0	1
FAC	1	0	0	2	0	0	0	0	0	0	1
Angiomatous polyp	1	0	0	0	0	0	0	0	0	0	0
Normal	2	0	1	1	0	0	1	0	0	4	6
Hemorrhoid	1	0	0	0	0	0	0	0	0	0	0
Hirschsprung's	0	0	0	0	1	0	0	0	0	0	0

UC-Ulcerative colitis, Hirs-Hirschsprung's disease, Hmd- Hemorrhoid, AF- Anal fissure, Diabe- Diabetic gastropathy, Mc-Microscopic colitis, Ic- Infectious colitis, C-Colitis

higher male incidence which was consistent with findings of Terda where peak incidence was in third decade of life and male predominance.⁹

The present study showed that thirteen cases of chronic non-specific colitis and was the most common diagnosis. This finding was similar to Shefali et al., Rangaswamy et al., Rajbhandari et al. and Bashir et al. where chronic non-specific colitis was the most common diagnosis comprising 47.1%, 45.21%, 27% and 38.3% respectively.^{2,7,8,10}

Tuberculosis of gastrointestinal tract occurs as primary lesion or secondary to pulmonary tuberculosis. In the present study, three (3.16%) cases were diagnosed as Granulomatous inflammation suggestive of Tuberculosis characterized by areas of granulomas, Langhans giant cells and caseous necrosis in the mucosa. Studies done by Shefali

et al., Rangaswamy et al. and Rajbhandari et al. showed similar findings of three (4.4%), six (7.32%) and 14 (11.1%) cases of tuberculosis in colonoscopic biopsies.^{2,8,10} Mukhtar, Bromberg et al. and Ergun et al. have reported hypertrophic type of tuberculosis can mimic malignancy.¹¹⁻¹³ Tandan and Prakash in their study of 212 cases described 159 cases of tuberculosis and highlighted the importance of granulomas and the distinguishing features of Tuberculosis and Crohn's disease.¹⁴

In the present study 31 (32.63%) cases were non-neoplastic polyps which was comparable with findings of Shefali et al. and Rajbhandari et al. where Non-neoplastic polyps were 20.5% and 16.7% respectively.^{2,10} Similarly, the distribution of non-neoplastic polyps was similar as of Shefali et al., Jhaji et al. and Chitale et al. where juvenile polyps were

the most common type of polyps comprising 57.14% and 75.7% respectively.^{2,15,16} Further, this study has revealed 12 cases of adenomas among 95 cases and most of them found in the patient having more than 50 years old. They are uncommon before 49 years of age and become more common with increasing age.¹⁷ This finding was supported by the previous study who reported 45% cases of adenomas after 50 years.¹⁸ However five (41.67%) cases were present in patients younger than 50 years. Molaei suggested mismatch repair dysfunction as the cause of sporadic colorectal adenoma in young adults.¹⁹ Males were more frequently affected than females in this study with male to female ratio of 3:1 which was consistent with findings of Albasri et al. with male to female ratio of 1.7:1.²⁰

Moreover, alcohol, smoking and meat consumption have been shown to be risk factors for colorectal carcinoma by Cappellani et al.²¹ In the present study patients diagnosed as colorectal carcinomas (n=11) were found to be non-vegetarian (100%), nine (81.81%) had consumed alcohol and six (54.55%) were smokers. However, the data included in this study is not sufficient to validate this correlation. Therefore, further population based study need to be done to correlation dietary pattern with colorectal carcinoma.

In the present study there was overall correlation between clinical and histopathological diagnosis. This correlation was more for polyps, malignancies and Hirschsprung's

Disease. All polyps suspected clinically were confirmed by histopathology and suspected malignancies were also established by histopathology.¹⁰ Similarly, out of four cases clinically suspected as inflammatory bowel disease, only two cases could be confirmed by histopathology as ulcerative colitis. The histopathologic changes of early bowel disease differ from that of established disease and degree of clinical severity of disease correlates with histologic degree of inflammation to a lesser extent.²² Moum et al. have shown biopsy as a better indicator of prognosis in follow up examination of ulcerative colitis.²³ Hence, multiple repeat biopsies are required in cases suspected to be inflammatory bowel disease for better clinico-pathological correlation.

CONCLUSION

This study showed an overall correlation between clinical and histopathological diagnosis with more reliable correlation in neoplastic lesions. However, the correlation in non-neoplastic lesions should be re-evaluated. In conclusion, colonoscopy is a better tool for the clinical diagnosis of colorectal disease however, without histopathology, the diagnosis will be incomplete. Therefore, it is always advisable to correlate colonoscopic findings with histopathological findings for the final clinical diagnosis of colorectal disease.

REFERENCES

- Singh H, Turner D, Xue L, Targownik LE, Bernstein CN. Risk of developing colorectal cancer following a negative colonoscopy examination. *JAMA*. 2006; 295(20): 2366-73.
- Shefali H, Vidya K, Shivarudrappa AS, Prakash CJ. The Spectrum of colonic lesions: A Clinico-pathological study of colonic biopsies. *Indian Journal of Pathology and Oncology*. 2015;2(4);189-209.
- Hopkins H, Berci G, Optical principles of endoscope. *Endoscopy*. 2nd ed. New york: Appleton Century Granta;1976.p.3-26.
- World Health Organization. IARC. Globocan Cancer Fact Sheets: colorectal Cancers [http://globocan.iarc.fr/Pages/fact_sheets_cancer.aspx?cancer=colorectal] Accessed on July 17, 2016]
- Pradhananga K, Baral M, Shrestha B. Multi institutional hospital -based cancer incidence data for Nepal - an initial report. *Asian Pac J Prev*. 2009; 10: 259-62.
- Iarsen K, Bray F. Trends in colorectal cancer incidences in Norway 1962- 2006; an interpretation of the temporal patterns by anatomic subsite. *Int J Cancer*. 2010; 126: 721-32.
- Bashir S, Nadeem R, Khan NR, Suleman BA, Qureshi GR. Histopathological Analysis of 1000 Colorectal Biopsies in Two Years in Shaikh Zayed Hospital, Lahore. *APICP*. 2012;13(3): 975-8.
- Rangaswamy R, Sahadev R, Suguna BV, Preethan KN, Ranjeeta SB. Clinico-colonoscopy and Histomorphological Spectrum Of Colonic Diseases in an Academic Tertiary Care Centre. *Journal of Evolution of Medical and Dental Sciences*. 2014 Jan;3(1):1-9.
- Terada T. Histopathologic study of the rectum in 1,438 consecutive rectal specimens in a single Japanese Hospital: I. Benign lesions, *Int J Clin Exp Pathol*. 2013; 6(3):349-57.
- Rajbhandari M, Karmacharya A, Khanal K, Dhakal P, Shrestha R. Histomorphological Profile of Colonoscopic Biopsies and Pattern of Colorectal Carcinoma in Kavre District. *Kathmandu Univ Med J*. 2013 Jul-Sep; 11(43); 196-200.
- Mukhtar AU. Ileo-caecal tuberculosis mimicking colonic tumor-case report. *Cent Afr Med*. 2000;46(2):44-5.
- Bromberg SH, Faroud S, de Castro FF, Morrone N, de Godoy AC, Franca LC. Isolated ileocecal tuberculosis simulating malignant neoplasia and Crohn's disease. *Rev Assoc Med Bras*. 2001;47(2):125-8.
- Ergun M, Cindoruk M, Alagozlu H, Unal S, Karakan T, Dursun A. Hypertrophic colonic tuberculosis tumorous mass. *Colorectal Dis*. 2008;10(7):735-6.
- Morson BC. The large intestine. In alimentary tract. Symmer's series Systemic pathology, 3rd ed. Vol. 3. Churchill Livingstone, Edinburgh; 1987.
- Jhaji K, Sood N, Malhotra V. Histopathological profile of tumors of midgut and hindgut-five year study in tertiary care hospital with review of literature. *Internet Journal of Pathology*. 2010;13(10). Available from: ispub.com/IJPA/13/1/5484.
- Chitale AR. Pathology of colorectal polyps: An overview. *Bombay Hospital Journal*. 2000;42(2):276-81.
- Owen DA, Kelly JK. Diseases of the digestive system: Large intestine and anus. Damjanov I, Linder J, Anderson's Pathology; 10th ed. St. Louis: Mosby;1996.p.1741-78.
- Webb WA, McDaniel L, Jones L. Experience with 1000 colonoscopic polypectomies. *Ann Surg*. 1985; 201(5): 626-32.

19. Molaei M, Yadollahzadeh M, Almasi S, Shivarani S, Fatemi SR, Zali MR. Sporadic colorectal polyps and mismatch repair proteins. *Indian J Pathol Microbiol.* 2011;54(4):725-9.
20. Albasri A, Yosef H, Hussainy A, Bukhari S, Alhujaily A. Profile of colorectal polyps: a retrospective study from King Fahad Hospital, Madinah, Saudi Arabia. *Asian Pac J Cancer Prev.* 2014;15(6):2669-73.
21. Cappellani A, Zanghi A, Di Vita M, Cavallaro A, Piccolo G, Veroux P, et al. Strong correlation between diet and development of colorectal cancer. *Front Biose.* 2013;18:190-8.
22. Finkelstein SD, Sasatomi E, Regueiro M. Pathologic features of early inflammatory bowel disease. *Gastroenterol Clin North Am.* 2002;31(1):17-23.
23. Moum B, Ekbohm A, Vatn MH, Elgjo K. Change in the extent of colonoscopic and histopathological involvement in ulcerative colitis over time. *Am J Gastroenterol.* 1999;94(6):1564-9.