

Usefulness of Flexible Airway Endoscopy for the Diagnosis of Pulmonary Diseases in Children

Rijal P, Giri A, Kumar P

Department of Pediatrics
Nepal Medical College and Teaching Hospital,
Kathmandu, Nepal.

Corresponding Author

Prashant Rijal
Department of Pediatrics
Nepal Medical College and Teaching Hospital,
Kathmandu, Nepal.
E-mail: prashant_rijal@hotmail.com

Citation

Rijal P, Giri A, Kumar P. Usefulness of Flexible Airway Endoscopy for the Diagnosis of Pulmonary Diseases in Children. *Kathmandu Univ Med J.* 2017;59(3): 235-9.

ABSTRACT

Background

Flexible airway endoscopy is a highly valuable procedure for evaluating pediatric airway and pulmonary disorders. However, its use in our setup is limited.

Objective

The main objective of this study is to analyze indications for flexible airway endoscopy in our population, explore its diagnostic yield and highlight potential complications.

Method

Seventy flexible airway endoscopies performed in children at Nepal Medical College and Teaching Hospital from June, 2013 to May, 2015 were analyzed.

Result

Fifty six (80%) of airway endoscopy had a meaningful outcome. Diagnostic yield for individual indications ranged from 50 to 87.5%. Recurrent/persistent pneumonia was the most rewarding indication. Complications were minimal and easily reversible.

Conclusion

The overall diagnostic yield of flexible airway endoscopy in our study population was 80%. The procedure was safe with minimal complication. Hence, earlier intervention and utilization of bronchoscopy should be encouraged after a careful clinical consideration of patients who could potentially benefit from this procedure.

KEY WORDS

Bronchoscopy, Bronchoalveolar lavage, Flexible bronchoscope

INTRODUCTION

Flexible airway endoscopy (FAE) of the pediatric airway includes examination of the nose, pharynx, larynx and tracheobronchial tree.¹ The technique has improved and with the advent of smaller-sized bronchoscopes, flexible fibreoptic bronchoscope (FFB) use has increased in pediatric patients and neonates.²⁻⁴ Bronchoalveolar Lavage (BAL) provides a very useful tool for diagnosing lower respiratory tract infections in both immune competent and immune compromised patients. One useful application of BAL combined with polymerized chain reaction (PCR) is in the diagnosis of pulmonary tuberculosis in smear-negative patients.⁵

Various studies have reported the use of FFB in pediatric age group. The indications, methods, diagnostic utility and safety of this procedure have been described.⁶⁻⁸

Despite its wide diagnostic and therapeutic implications there has not been any study conducted in Nepal till date to evaluate the efficacy and safety of FAE in pediatric patients. Hence, we conducted a prospective hospital based study to evaluate indications, diagnostic yield and potential complications of FAE in children in our setup.

METHODS

This is an observational prospective hospital based study conducted from June, 2013 to May, 2015 in pulmonology division of pediatric department at Nepal Medical College and Teaching Hospital (NMCTH), Kathmandu, Nepal. Simple convenient and purposive sampling technique was adopted to enroll children from one day old to 15 years of age with suspected pulmonary pathology. Since there has not been any previous study to estimate prevalence of any pulmonary pathology in children in our setup, we decided to enroll all children in whom FAE was performed. An informed written consent was obtained from the caretakers/parents of all children. Ethical clearance was taken from Institutional Review Board in NMCTH. Clinical details of patients including the demographic characteristics, indications, complications, findings and laboratory results were recorded and retrieved for analysis. Data was entered in SPSS ver. 17. Frequency and percentage were calculated for all qualitative data.

In children with stridor, FAE was performed when there was a high index of suspicion for diagnosis other than laryngomalacia or when the patient had failure to thrive. Children with recurrent infection were bronchoscoped when they failed to respond to appropriate antimicrobial treatment. Persistent wheezing was an indication for bronchoscopy when it showed no response to antiasthmatic medication and there was a high index of suspicion for alternative diagnosis such as foreign body inhalation or

tracheomalacia. Patients with significant hypoxemia, hypotension, arrhythmias, known coagulopathy and those whose guardians were unwilling to participate in the study were excluded.

All Children were kept nil per oral for 4-8 hours pre-procedure. The procedure was performed by fibreoptic bronchoscope (karlstorz) with 3.7 mm external diameter. Sedation protocol included: midazolam (0.05-0.15 mg/kg) and ketamine (2 mg/kg). FAE was performed via nasal route in all cases. All procedures were video recorded which enabled us to review the findings. In all children, 1% xylocaine solution was sprayed just above the glottis and at carina through the suction channel. The visual findings of the airway anatomy were recorded. BAL was obtained from the right middle lobe or lingula according to European respiratory society (ERS) guidelines.⁹ Sterile saline (3-4 ml/kg) was injected after the scope was wedged and sucked back in sterile mucus trap immediately by using suction. All children received free flow oxygen through nasal cannula kept in front of nostrils and oral cavity. During the procedure, clinical monitoring for respiratory effort, cyanosis, peripheral perfusion, oxygen saturation and heart rate was done. After the procedure, children were monitored every 30 minutes for next 2-4 hours. Once child regained full consciousness oral feeds was started and sent home on the same day. Complications during FAE and the recovery period were recorded in all patients. Analysis of the material was performed by dividing the subjects according to the clinical indication as recorded in the referral letter or the report of clinical consultation prior to the investigation. When the diagnosis of foreign body was confirmed the patient was referred for rigid bronchoscopy straight away.

RESULTS

During the study period, 70 FAE were performed. The age distribution was from one day old to 15 years of age. Most of the FAE were performed in children below one year of age which constituted 42.8% cases (fig. 1). Male to female ratio was 1.12. The most common indication for doing FAE was recurrent/persistent pneumonia in 34.2% patients, followed by stridor 31.4% patients. The commonest findings in FAE were increased secretions in 25.7% patients. The indications for doing FAE and yield are shown in (Table-1) and (Table-2) respectively. Broncho-alveolar lavage as indicated was performed in 60.0% children. Microbial pathogens were isolated in 40.4% cases. Most common organism was acid fast bacilli detected in 11.9% patients followed by pseudomonas, kleibseilla, acinitobacter species (Table-3). Most common complication was fever which was seen only in 5.7% patients (fig. 2). Procedure was abandoned only in one patient due to oxygen desaturation.

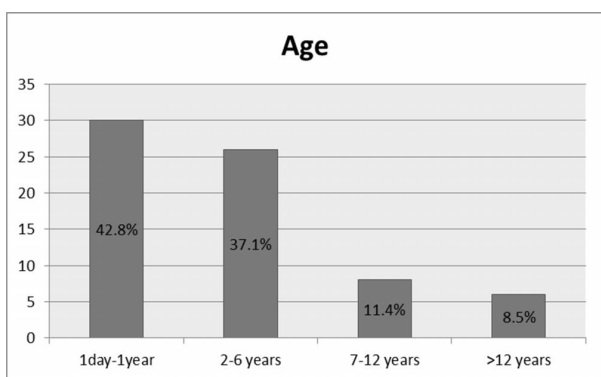


Figure 1. Distribution of age

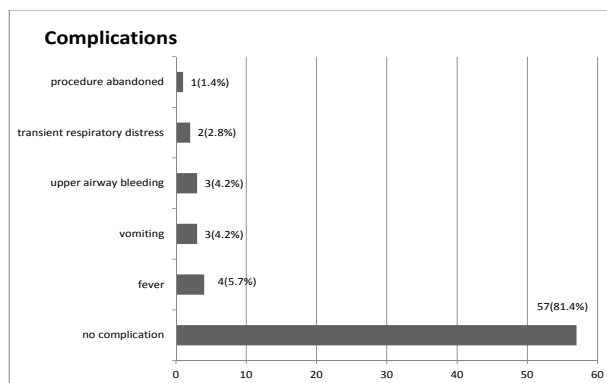


Figure 2. Complications after bronchoscopy

Table 1. Indications and positive findings on bronchoscopy

Indications	Number	Abnormal
Stridor	22	19(86.3%)
Suspected Tracheo esophageal fistula	6	4(66.6%)
Suspected pulmonary haemorrhage	2	1 (50.0%)
Persistent/recurrent pneumonia	24	21(87.5%)
Persistent Collapse of lung	6	5 (83.3%)
Suspected TB/resistant TB	8	5(62.5%)
Interstitial lung disease	2	1(50.0%)
Total	70	56(80%)

Table 2. Abnormal Findings on Bronchoscopy

Abnormal findings	Number	%
Increased secretions	18	25.7
Laryngomalacia	17	24.2
Endobronchial TB	4	5.7
Tracheomalacia	2	2.8
Bronchomalacia	2	2.8
Tracheoesophageal fistula	3	4.2
External compression	4	5.7
Foreign body aspiration	4	5.7
Subglottic stenosis	2	2.8

DISCUSSION

We conducted this study in order to analyze indications for FAE in our population, explore its diagnostic yield for each indication and highlight potential complications. Similar analyses done from other centers have reported variable outcomes.¹⁰ In our series, 80% of FAE had a meaningful outcome. This is similar to study done by Kirvassilis et al in which outcome was 75%.¹¹ Khan et al. found overall diagnostic yield of 70% whereas diagnostic yield for individual indications ranged from 25% to 100%.¹² We looked into diagnostic yield for individual indications and found a range of 50 to 87.5%. This difference might be due to limited individual indications for bronchoscopy in our study as compared to studies by Kiravassilis et al. and Khan et al.^{11,12}

Table 3. Finding of organisms in Broncho alveolar lavage

Organisms	Number (n=40)
Acid fast bacilli	5
Pseudomonas spp	2
Acinetobacterspp	2
Klebsiella pneumonia	2
H. Influenzae	1
Staphylococcus aureus	1
Sreptococcus pneumoniae	1
Nocardia species	1
Candidaalbicans	1
Cladosporidium species	1
No Growth	23

FAE in patients with recurrent and persistent pulmonary infection had the highest diagnostic yield of 87.5% which is higher than reported by Gokdemir et al which was only 32% in their study.¹³ Here, 50% of these children with recurrent/persistent pneumonia were diagnosed as bronchiectasis and they were bronchoscoped in order to identify previously unrecognized respiratory pathogens. Abnormal findings in bronchoscopy included congested and edematous mucosa with abundant secretions. Positive BAL cultures was obtained in 58.3% (n=17) which is higher as compared to 33.3% done by Chang et al. justifying the indication for bronchoscopy and making us consider routine bronchoscopy for all children with bronchiectasis.¹⁴ Acid Fast Bacilli (AFB) was the commonest pathogen identified in 11.9% patients followed by pseudomonas, kleibseilla, acinitobacter species. Among various bronchoscopic specimens, BAL should be considered best for diagnosis of TB as we detected acid fast bacilli in 11.9% children, out of which two cases were identified as multi-drug resistant tuberculosis. Studies have shown a better diagnostic yield for AFB from BAL with an additional benefit of rapid detection drug resistance in MDR TB.^{15,16} Menon et al found that diagnostic yield for AFB from BAL was 30.8% which is better than that from gastric aspirate in children with probable pulmonary TB.¹⁷

Stridor was the second most common indication for airway endoscopy in our study after recurrent/persistent pneumonia. Here, 86.3% of these children had laryngomalacia. Similar data of 75.0% was reported by Bluestone et al.¹⁸ We diagnosed foreign body inhalation in 5.7% patients. Hence, FFB may be the diagnostic modality of choice when foreign body inhalation is not certain as shown by other studies.¹⁹ Bronchoscopy was also performed in four children with wheezing unresponsive to antiasthmatic medication with a diagnostic yield of 66.6%. Infectious or internal/external airway compression was attributable to establish the cause for persistent wheezing after FFB. Our finding is slightly lower than Aslan et al as their diagnostic yield was 85%.²⁰ This may be because less number of children in our study had indication of FAE for persistent wheezing than in the study done by Aslan et al.²⁰

We did flexible bronchoscopy in children with radiological abnormalities (e.g. persistent collapse of lung) with high diagnostic yield of 83.3%. Stenosis of a bronchus and abundant secretions with mucous plugging were common findings as compared to study done by Raghu which show 60.0% of abnormal findings.²¹ However, bronchoscopy gave us the opportunity for therapeutic suctioning and installation of saline that led to significant clinical improvement in most of the cases. We also diagnosed endobronchial tuberculosis in 5.7% children which is lower than Chan et al. where he found 41.7% of children with endobronchial tuberculosis.²² This might be due to small sample size in our study and also as less number of flexible bronchoscopy were performed in our setup.

In our study, 82% of the study patients had no complication. Fever was the most common side effect which occurred only in 5.8% patients. Other complications included transient respiratory distress, vomiting and airway bleeding which were in small numbers and easily reversible. Our findings are in accordance to what has previously been reported by De Blic et al.²³ However, since fatalities have been reported; continuous vigilance and adherence to international standards are highly recommended. It has been suggested that bronchoscopy is more risky in children with severe hypoxia, uncontrolled bleeding diathesis, cardiac failure or severe pulmonary hypertension.²⁴

To our knowledge, this is a first study in Nepal to report diagnostic implications of FAE in pediatric population. Our study emphasizes the high diagnostic yield of FAE in pediatric patients and recommends FAE as a simple and safe procedure with excellent therapeutic benefits. However, we acknowledge that our sample size is small and also diverse which might have led to significant variations in results as compared to other studies. We strongly feel that studies with large sample size are needed in our setup to corroborate our findings.

CONCLUSION

Fiberoptic airway endoscopy is safe and valuable in diagnosis and treatment of pediatric airway disorders. Besides, Bronchoalveolar Lavage which can be done with this procedure can play a significant role in the early differentiation of infectious versus non-infectious conditions, and also aid in identifying the exact pathogens and best treatment options.

REFERENCES

1. Wood RE. Spelunking in the pediatric airways: explorations with the flexible fiberoptic bronchoscope. *Pediatr Clin North Am.* 1985; 31:785–99.
2. British Thoracic Society guidelines on diagnostic flexible bronchoscopy. *Thorax* 2001; 56:1–121.
3. De Blic J. Bronchoscopy In: Greenough A, Robertson NRC, Milner AD, eds. Neonatal Respiratory Disorders London, Arnold, 1996; 89–96.
4. Tang LF, Chen ZM. Fiberoptic bronchoscopy in neonatal and pediatric intensive care units: a 5-year experience. *Med Princ Pract.* 2009; 18:305–9.
5. De Blic J, Delacourt C, Scheinmann P. Ultrathin flexible bronchoscopy in neonatal intensive care units. *Arch Dis Child.* 1991; 66:1383–85.
6. Nakano T, Shikada M, Nomura M, Kuwayama KF, Suganuma E, Ishikawa KM et al. Feasibility of fiberoptic bronchoscopy for small infants including newborns. *Tokai J Exp Clin Med.* 2004; 29:1–5.
7. Ernst A, Silvestri GA, Johnstone D. Interventional pulmonary procedures: Guidelines from the American College of Chest Physicians. *Chest.* 2003; 123:1693–1717.
8. Chen NH, Liu YC, Tsao TC, Wu TL, Hsieh MJ, Chuang ML et al. Combined bronchoalveolar lavage and polymerase chain reaction in the diagnosis of pulmonary tuberculosis in smear-negative patients. *Int J Tuberc Lung Dis.* 2002; 6:350–55.
9. De Blic J, Midulla F, Barbato A, Clement A, Dab I, Eber E et al. Bronchoalveolar lavage in children. ERS Task Force on bronchoalveolar lavage in children. *European Respiratory Society. Eur Respir J.* 2000; 15:217–31.
10. Barbato A, Magarotto M, Crivellaro M, Novello A Jr, Cracco A, de Blic J et al. Use of the paediatric bronchoscope, flexible and rigid, in 51 European centres. *Eur Respir J.* 1997; 10:1761–66.
11. Kirvassilis F, Gidaris D, Ventouri M, Zampouri A, Mylona M, Keramidiotis A et al. Flexible fiberoptic bronchoscopy in Greek children. *Hippokratia.* 2011; 15(4): 312–15.
12. Khan MY, Ali S, Umar M. Paediatric flexible broncoscopy: experience form Peshawar. *Pak J Chest Med.* 2015; 21(2): 61-7.
13. Gokdemir Y, Cakir E, Erdem E, Ersu R, Karadag B, Karakoc F. The role of flexible bronchoscopy in evaluation of recurrent and persistent pneumonia in children. *European Respiratory Journal.* 2011 38: 1415
14. Chang AB, Boyce NC, Masters IB, Torzillo PJ, Masel JP. Bronchoscopic findings in children with non-cystic fibrosis chronic suppurative lung disease. *Thorax.* 2002; 57:935–38.
15. Walters E, Goussard P, Bosch C, Hesselting AC, Gie RP. GeneXpert MTB/RIF on bronchoalveolar lavage samples in children with suspected complicated intrathoracic tuberculosis: A pilot study. *Pediatr Pulmonol.* 2013; 1137:1133–7.

16. Khalil KF, Butt T. Diagnostic yield of Bronchoalveolar Lavage gene Xpert in smear-negative and sputum-scarce pulmonary tuberculosis. *J Coll Physicians Surg Pak.* 2015; 25(2):115–8.
17. Menon PR, Lodha R, Singh U, Kabra SK. A prospective assessment of the role of bronchoscopy and bronchoalveolar lavage in evaluation of children with pulmonary tuberculosis. *J Trop Pediatr.* 2011; 57(5):363–7.
18. Bluestone CD, Healy GB, Cotton RT. Diagnosis of laryngomalacia is not enough. *Arch Otolaryngol Head Neck Surg.* 1996;122:1417.
19. Cohen S, Avital A, Godfrey S, Gross M, Kerem E, Springer C. Suspected Foreign Body Inhalation in Children: What Are the Indications for Bronchoscopy? *The Journal of Pediatrics.* 2009;155:276–80.
20. Aslan AT, Kiper N, Dogru D, Karagoz AH, Ozcelik U, Yalcin E. Diagnostic value of flexible bronchoscopy in children with persistent and recurrent wheezing. *Allergy Asthma Proc.* 2005;26:483–86.
21. Raghu RTS, S Mathew, Kumar R, Garcha PS. Atelectasis in children. *Indian Pediatrics* 1998; 35:329-35.
22. Chan S, Abadco DL, Steiner P. Role of flexible fiberoptic bronchoscopy in the diagnosis of childhood endobronchial tuberculosis. *Pediatr Infect Dis J.* 1994; 13(6):506-9.
23. De Blic J, Marchac V, Scheinmann P. Complications of flexible bronchoscopy in children: prospective study of 1,328 procedures. *Eur Respir J.* 2002; 20(5):1271-6.
24. Bush A. Bronchoscopy in paediatric intensive care. *Paediatr Respir Rev.* 2003; 4: 67-73.