

# Traumatic Diaphragmatic Hernia: Diagnostic Dilemma

Vaidya S,<sup>1</sup> Biswas M,<sup>2</sup> Rai K<sup>1</sup>

<sup>1</sup>Department of CardioVascular and Thoracic Surgery

Banghabandhu Sheikh Mujib Medical University (BSMMU), Dhaka, Bangladesh.

<sup>2</sup>Department of Thoracic Surgery

National Institute of Diseases of Chest Hospital,

Dhaka, Bangladesh.

## Corresponding Author

Satish Vaidya

Department of CardioVascular and Thoracic Surgery

Banghabandhu Sheikh Mujib Medical University (BSMMU), Dhaka, Bangladesh.

E-mail: satish\_vaidya@hotmail.com

## Citation

Vaidya S, Biswas M, Rai K. Traumatic Diaphragmatic Hernia: Diagnostic Dilemma. *Kathmandu Univ Med J.* 2017;59(3):265-7.

## INTRODUCTION

Traumatic rupture of the diaphragm is an uncommon condition. The prevalence of diaphragmatic rupture among blunt trauma victim ranges from 0.8 to 8%.<sup>1</sup> The etiologic factors are blunt trauma and penetrating trauma.<sup>2</sup> Diaphragmatic rupture can have an acute presentation or delayed as respiratory distress or obstruction.<sup>3</sup> The course of events following disruption varies highly.<sup>1</sup> Diaphragmatic injury can be classified according to the time of presentation; there are three clinical phases; acute, latent and obstructive. The acute phase begins with the original trauma and ends with the apparent recovery from other injuries and thus the diaphragm injury may be masked. In latent phase symptoms are variable and nonspecific. Symptoms are suggestive of other symptoms such as peptic ulcer disease, gallbladder disease partial bowel obstruction. In obstructive phase, bowel obstruction occurs after incarceration of the herniated bowel.<sup>3</sup> The most serious complication of a diaphragmatic hernia is strangulation, and the occurrence of symptoms of intestinal obstruction or pulmonary compression in a patient with a

## ABSTRACT

Traumatic rupture of the diaphragm is an uncommon condition. The prevalence of diaphragmatic rupture among blunt trauma victim ranges from 0.8 to 8%. The etiologic factors are blunt trauma (for example, in motor vehicle accidents) and penetrating trauma. The diagnosis is often missed because of non-specific clinical signs, and the absence of additional intra-abdominal and thoracic injuries. We present a case which was misdiagnosed as a case of left sided hemopneumothorax and treated with tube thoracotomy in other center.

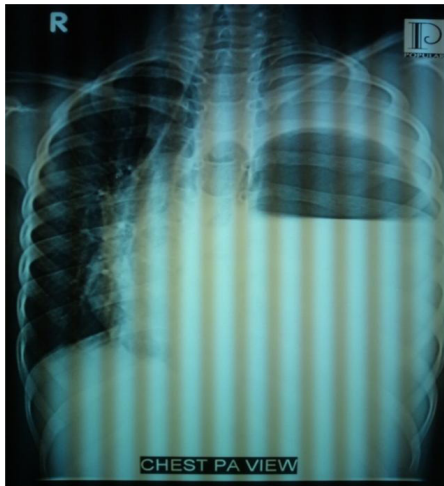
## KEY WORDS

*Diaphragmatic, Thoracotomy, Traumatic rupture*

recent or old wound of the chest or upper abdomen should arouse suspicion. However, early recognition and prompt surgical treatment appears to be within the capability of surgeons.<sup>4</sup> It can be managed through a laparotomy or a thoracotomy and in the current scenario even with minimal access surgery as Video Assisted Thoracoscopic Surgery (VATS) or Laparoscopic approach in abdomen.<sup>5</sup>

## CASE REPORTS

A 6 and half years child hailing from Meyemensigh, Bangladesh presented with the complaints of shortness of breath, epigastric pain, vomiting and fever for 5 days following fall from lap of mother while playing and sustaining injury to left chest and abdomen. Shortness of breath was gradual in onset and increased during exertion. Epigastric pain was continuous in nature nonradiating, increased on movement and associated with abdominal distention. Gradually she had multiple episodes of vomiting, which was yellowish and greenish in color and occurred



**Figure 1.** Chest X-ray Suggestive of Left sided Hydropneumothorax

after food intake. She also had fever with maximum recorded up to 101o F. She was initially taken to a nearby hospital where chest x-ray was done and was diagnosed as hemopneumothorax (fig. 1), following which chest tube insertion was done. However no fluid was drained and the patient was referred to National Institute of Diseases of the Chest Hospital (NIDCH) for further management.

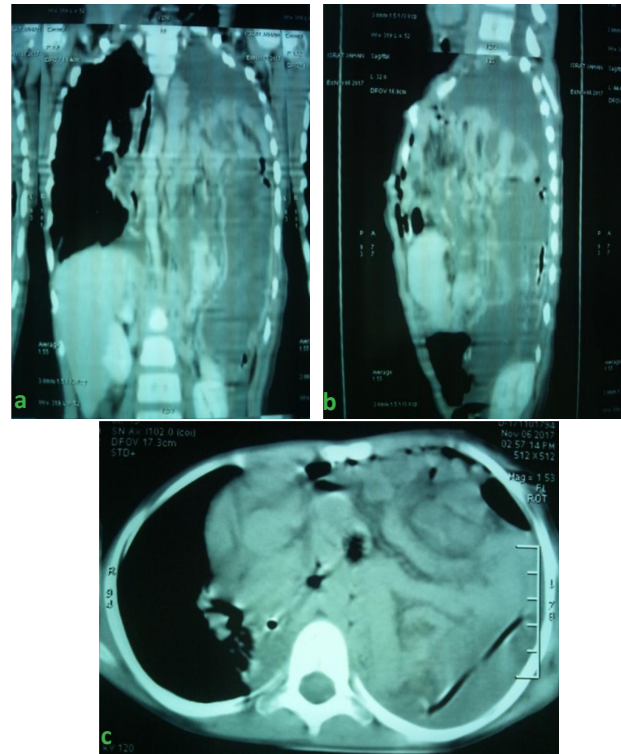
On examination she was ill looking with average body built and poor nutritional status. Clinical examination revealed hyperresonant sound during percussion on left 2<sup>nd</sup> and 3<sup>rd</sup> ICS and dull on 4<sup>th</sup> and 5<sup>th</sup> ICS. Bowel sound was heard on the left lower aspect of the chest. Right sided thoracic findings were normal.

NG tube was placed with drainage of yellowish and greenish fluid with food particles. CT scan was suggestive of diaphragmatic hernia due to rupture of left hemidiaphragm. (fig. 2a,b,c). Other routine investigations were also done including general anesthesia investigations which were all within normal limit.

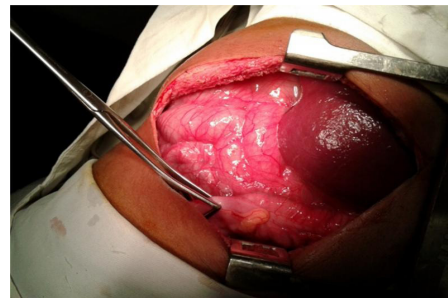Patient underwent primary repair of the diaphragmatic hernia defect in two layers by left posterolateral thoracotomy incision. Small gut, large gut, omentum and spleen were found in the chest cavity. Abdominal Viscera were reduced to abdominal cavity. There was adhesion of omentum to the diaphragmatic rent which was released. There was a rent of the diaphragm located posterolaterally, it was repaired in two layers (fig. 3, fig. 4, and fig. 5). Post-operative period was uneventful and patient was discharged on 12<sup>th</sup> POD. At the time of her discharge, she was hemodynamically stable and her wound was healthy.

**DISCUSSION**

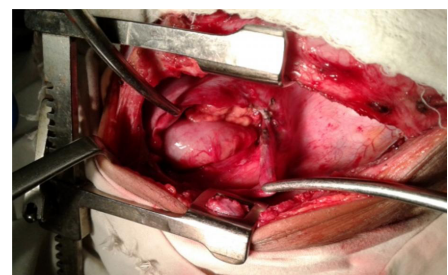
Injury to diaphragm from blunt trauma is occasionally seen. The prevalence of diaphragmatic rupture among blunt trauma victims ranges from 0.8 to 8%. Usually Diaphragmatic injury can be traced back to a violent forced



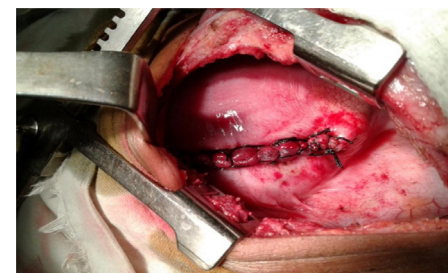
**Figure 2a, b, c.** Suggestive of Diaphragmatic rupture with abdominal content in the left hemothorax.



**Figure 3.** Post Diaphragmatic herniation of abdominal content



**Figure 4** Rent of Hernia



**Figure 5.** Post Hernia Repair

applied to the chest or abdomen. In our case patient was misdiagnosed as a case of left sided hydropneumothorax as patient only provided history of shortness of breath, epigastric pain, vomiting and fever. So, proper history and suspicion of the diaphragmatic rupture is key to early diagnosis of such kind of cases. Missed blunt diaphragmatic rupture results in herniation of the abdominal organs into the chest due to the abdominothoracic pressure gradient, which progressively enlarges the defect in the diaphragm. Progressive herniation results in abdominal or/and chest pain, constipation, strangulation and perforation of the abdominal viscera, with shortness of breath, dyspnea, and respiratory infections due to compression of the lung on the affected side.

The surgical approach to repairing acute diaphragmatic injury or rupture depends on the mechanism of injury, the condition of the patient and the time of presentation. Shock should be corrected and nasogastric tube should be inserted to decompress the stomach. There are various surgical approaches for diaphragmatic hernias repair. Mesh patches are widely used.

Polytetrafluoroethylene (Gore-Tex), polyethylene terephthalate (Dacron) and polypropylene are the most

common materials used in prosthetic patches to repair large diaphragmatic defects that are not amenable to primary repair. Recently, some authors suggested the use of a newer biologic material which is composed by a sheet of collagen derived from porcine dermis.<sup>6</sup> However, there are cases in the literature reporting patch infection and hernia recurrence after the use of a mesh thus we believe that primary repair with nonabsorbable sutures is the best alternative for diaphragm repair, as it reduces infection risk and the costs of the procedure.<sup>7,8</sup>

This was the case which was misdiagnosed as a case of left sided hydropneumothorax which later turned up as diaphragmatic injury with herniation of abdominal content to left hemithorax. Early diagnosis is very important for appropriate surgical management, reducing the risks of visceral strangulation and its complications. Surgical repair remains the only curative treatment for diaphragmatic hernias because such hernias are invariably associated with strangulation. Primary repair with non-absorbable sutures remains the gold standard for the closure of small to moderate sized defects. Patients with large defects may require patch closure with a mesh, but these can carry risks.

## REFERENCES

1. Sellke FW, delNido PJ, Swanson SJ, editor. Sabiston and spencer surgery of the chest. 8<sup>th</sup> ed. Philadelphia: Elsevier Saunders; 2010. 96.
2. Rajesh S, Sabaratnam S, Alan JM, Amit KC. Traumatic rupture of diaphragm. *Ann Thorac Surg.* 1995; 60:1444-9.
3. Cameron JL. Diaphragmatic injury. In: Current Surgical Therapy. 7<sup>th</sup> ed. St Louis, MO: Mosby-Year Book; 2001. p. 1095-100.
4. Simpson J, Lobo DN, Shah AB, Rowlands BJ. Traumatic diaphragmatic rupture: Associated injuries and outcome. *Ann R Coll Surg Engl.* 2000; 82:97-100.
5. Hood RM. Traumatic diaphragmatic hernia. *Ann Thorac Surg.* 1971; 12:311-24.
6. Mitchell IC, Garcia NM, Barber R, Ahmad N, Hicks BA, Fisher AC. Permacol: a potential biologic patch alternative in congenital diaphragmatic hernia repair. *J Pediatr Surg.* 2008; 43:2161-64.
7. Moss RL, Chen CM, Harrison MR. Prosthetic patch durability in congenital diaphragmatic hernia: a long-term follow-up study. *J Pediatr Surg.* 2001;36:152-4.
8. Bekdash B, Singh B, Lakhoo K. Recurrent late complications after congenital diaphragmatic hernia repair with prosthetic patches. A case series. *J Med Case Rep.* 2009;3:7237.