

Abdominal tuberculosis – a study of 25 cases

Sharma YR¹

¹Lecturer, Department of Medicine, Kathmandu University Medical School

Abstract

Abdominal tuberculosis is one of the common extra pulmonary tubercular infections. Its clinical presentation is protean and it has diagnostic dilemma, as most of the investigations are non-specific and less sensitive. Therefore this study was undertaken to define the most suggestive clinical features of abdominal tuberculosis, to find out the efficacy of most commonly available investigations and also to evaluate the response of abdominal tuberculosis to conventional antitubercular therapy. Twenty five cases of either sex were studied in department of gastroenterology in BSMMU (earlier IPGMR), Dhaka from January 2001 to June 2003. All patients were clinically evaluated and were investigated by available tests. Eighteen patients were diagnosed by investigations (One by detecting AFB, 9 with caseating granuloma in iopsy specimen and 8 with suggestive radiological findings). Diagnosis of 7 patients were made from the common clinical features (fever, weight loss, altered bowel habit, abdominal pain and distension, positive non-specific findings and from response by antitubercular therapy. All patients received conventional 9 month anti-tubercular treatment with Rifampicin, Isoniazide and Pyrazinamide and were followed up clinically during and one year after completion of treatment. All patients were improved with minimum side effects of drug. Therefore, it is observed that a representative tissue biopsy (when approachable) and radiological findings are good method of diagnosis of abdominal tuberculosis. Strongly suggestive clinical features with positive non specific investigation findings are also an indication for anti tubercular treatment in all endemic countries like Nepal, Bangladesh and India. Treatment of abdominal tuberculosis is in no way different from that of other conventional anti- TB therapy.

Keywords: Tuberculosis, Abdominal Tuberculosis.

The problem of tuberculosis is worldwide and is a major health problem in developing countries¹⁻². The diagnosis of gastrointestinal tuberculosis is often delayed, increasing the morbidity associated with this treatable condition³. The disease may develop secondary to primary focus elsewhere in the body, usually the lungs, or it may originate within intestinal tract from swallowed sputum or rarely ingestion of cow's milk⁴. Its non-specific and protean clinical manifestations cause intestinal tuberculosis to be confused with many other diseases, especially Crohn's disease and Intestinal neoplasms. Many cases go unrecognized until a surgically removed specimen is examined histopathologically, particularly when active pulmonary disease is absent. Gastrointestinal (GI) tract is reported to be the sixth most common extrapulmonary site, and 15 to 50 % of patients with GI involvement may have active pulmonary disease. Abdominal tuberculosis can involve the luminal gastrointestinal tract, liver, spleen, lymph nodes, peritoneum and female genital tract, the most common site being the ileocecal region. Tuberculous peritonitis occurs in less than 1% of cases of tuberculosis. The organisms may enter the peritoneal cavity through the bowel wall, by direct

extension from the gynaecological tract, or by haematogenous spread from a primary pulmonary focus. The diagnosis of tubercular peritonitis is often difficult to make and requires a high index of clinical suspicion. The onset usually is insidious, with symptoms present for many months before diagnosis. Peritoneal tuberculosis may also present in some clinical conditions like cirrhosis of liver with portal hypertensive Ascites. In such patients, the diagnosis of concomitant tuberculous peritonitis may be suspected and is often overlooked.

Routine laboratory and radiographic analyses are of limited diagnostic value. Total leukocyte count is usually normal and negative mantoux test does not exclude the disease. Active pulmonary disease may be evident only in 14% of cases and AFB smears on ascitic fluid are rarely positive.

Correspondence

Dr. Yuba Raj Sharma
Lecturer Department of Medicine
Kathmandu University Medical School (KUMS).
B&B Hospital, Gwarko, Lalitpur, Nepal.
Email : yuraj@info.com

Cultures require weeks to mature and are positive in a few as 20% of diagnosed cases. Polymerase chain reaction (PCR) analysis for rapid detection of bacillus, tubercles and ascitic adenosinase levels are currently being evaluated as diagnostic tools. Laparoscopy is the gold standard for the diagnosis of peritoneal tuberculosis. It allows a presumptive visual diagnosis in more than 85% of cases and with guided biopsy allows a definitive diagnosis in over 97% of cases. Therefore, due to less specific clinical presentations and less sensitive and non specific available investigations, abdominal tuberculosis may have diagnostic dilemma. Clinicians should maintain a high index of suspicion for tuberculosis so that anti-tubercular drug therapy which is very effective in absence of drug resistance, may be initiated early and treatment delay is associated with significant mortality⁵⁻⁶. Therefore, we decided to evaluate the patients with abdominal tuberculosis who attended a Tertiary level referral hospital in Dhaka, Bangladesh.

Materials and Methods

This was a prospective observational study carried out in the department of gastroenterology, Bangabandhu Sheikh Mujib Medical University (BSMMU) Dhaka during, January 2001 to June 2003. Twenty-five consecutive patients with either sex with

abdominal tuberculosis were enrolled in the study. All patients were clinically evaluated with meticulous history and physical examination and were investigated by available tests like blood counts including TC DC, ESR, HB, mantoux test, chest X-ray, abdominal X-ray, abdominal ultrasonography, barium X-rays, ascitic fluid study, fine needle aspiration cytology, abdominal laparoscopic study and Histopathology and CT Scan of abdomen in selected patients.

All patients received 9 months of standard anti tubercular treatment with Rifampicin; Isoniazide and pyrazinamide and were followed up clinically during and one year after completion of treatment.

Results

A total number of 25 patients 18 male and 7 female, age ranging from 18 to 62 years (mean age 35 years) were diagnosed to have abdominal tuberculosis. Among the common presenting symptoms, abdominal pain, weight loss and anorexia were found in 20 (80%); 21(84%) and 18 (72%) of patients respectively. Fever was found in 6 (24%), diarrhoea in 12 (48%) and constipation in 4 (16%) of cases. Whereas, nausea and or vomiting in 8 (32%) and melena was present in 1 (4%) of cases (Table-1).

Table 1 Common presenting symptoms

Symptoms	Number of patients N=25 (%)
Abdominal pain	20 (80)
Fever	6 (24)
Weight loss	21 (84)
Anorexia	18 (72)
Diarrhoea	12 (48)
Constipation	4 (16)
Nausea / vomiting	8 (32)
Melena	1 (4)

Table 2 Presenting Signs:

Signs	Number of patients N= 25 (%)
Abdominal tenderness	12 (48)
Abdominal distension or ascites	7 (28)
Hepatomegaly	4 (16)
Splenomegaly	2 (8)
Abdominal mass or doughy abdomen	6 (24)
Peritoneal signs	2 (8)
Cervical lymphadenopathy	2 (8)

Table 3 Disease sites

Site of involvement	No of patients N=25(%)
Peritoneum	9 (36)
Upper GI (Oesophagus, stomach, duodenum)	0
Jejunum / Ileum	4 (16)
Ileocaecal	7 (28)
Colon & rectum	2 (8)
Multiple intestinal sites	1 (4)
Liver	2 (8)
Miliary	2 (8)
Active pulmonary tuberculosis	6 (24)

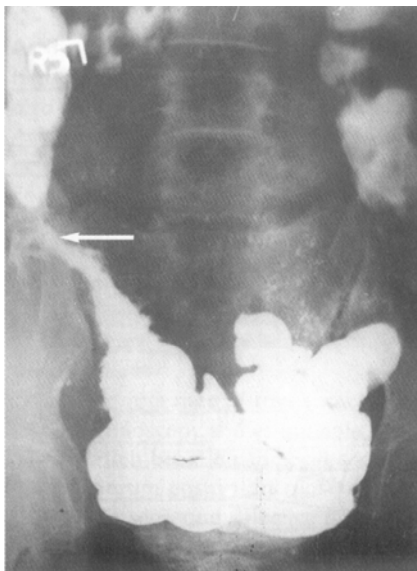
Note: Some patients are counted in more than one group

Table 4. Investigations

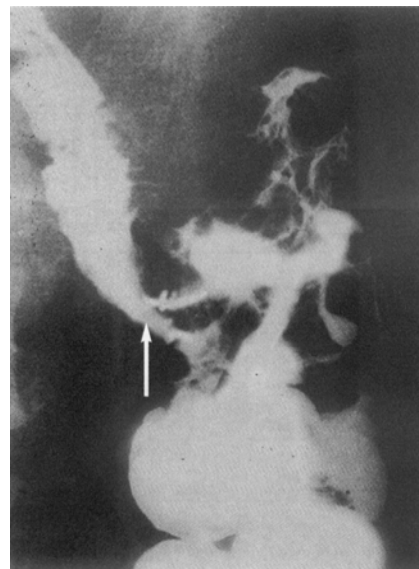
Test	Number of patients N=25 (%)
Anaemia (HB <41% in male and <36% in female)	16 (64)
WBC count (> 11000/ cumm)	4 (16)
Monocytosis (> 9%)	7 (28)
Mantoux test (> 10 mm in duration)	8 (32)
Albumin (<35 g/l)	12 (48)
Ascitic fluid study (n=7)	
Exudative	7 (28)
AFB detection	1 (4)
Barium meal and follow through (n=18) (Ulceration, narrowing deformity)	8 (32)
Laparoscopy (n=14)	
Morphology (e.g. tubercles)	6(24)
Biopsy (e.g. Caseating Granuloma)	13 (52)
CT Scan of abdomen (n=10)	
Enlarged lymphnodes	6 (24)
Mass (Matted loops or omental thickening)	4 (16)

Fig-1. Ileocaecal tuberculosis.

The caecum and terminal ileum are stenotic

**Fig-2.** Ileocaecal tuberculosis.

The caecum and terminal ileum are stenotic; and ulcerated



The abdominal pain was of varying quality, and frequently cramping or dull aching in nature mostly located in right side of abdomen and was correlated with the site of disease. Among the presenting signs, abdominal tenderness was found in 12 (48%), abdominal distension or ascites in 7 (28%), hepatomegaly in 4 (16%) and splenomegaly in 2 (8%) patients. Abdominal mass or Doughy abdomen was detected in 6 (24%), peritoneal signs in 2 (8%) and cervical lymphadenopathy in 2 (8%) of cases.

In the present study, sites of involvement of abdominal tuberculosis were peritoneum in 9 (36%), and ileocaecal region in 7 (28%), jejunum or ileum in 4 (16%), colorectum in 2 (8%) and liver in 2 (8%) of cases. Multiple intestinal sites were involved in 1 (4%) and 2 (8%) patients presented as military tuberculosis. Active pulmonary tuberculosis as found in 6 (24%) of patients (Table-3).

In this study, Laboratory investigations revealed anaemia in 16 (64%), WBC count > 11000/ cumm in 4 (16%) and monocytosis in 7(28%) patients. Mantoux test was reactive in 8 (32%) and hypoalbuminaemia in 12 (48%) of patients. Ascitic fluid study was performed in 7 patients who had ascites and exudative type was present in all the patients. one (4%) patient also was detected to have AFB positive. Barium meal and follow through x-ray was done in 18 patients and 8 (32%) patients revealed suggestive lesions of tuberculosis as having ulceration, narrowing or deformity in Intestine. Laparoscopy was performed in selected 14 patients, out of them, tubercles were visualized morphologically, in 6 patients and histopathology revealed caseating granuloma in 13 patients. CT Scan of Abdomen was done in selected 10 patients, out of them 6 patients revealed abdominal lymphadenopathy and 4 patients showed mass lesions in abdomen (Table-4).

Discussion

One half of the world population is infected with M. tuberculosis and it is the leading cause of infectious death, with approximately 2 million deaths annually. Up to 5 % of patients with myco tuberculosis have GI involvement, and the GI tract is reported to be the sixth most common extra pulmonary site. GI TB is often difficult to diagnose and sign and symptoms are non-specific and in our samples, clinicians often failed to consider TB in the initial differential diagnosis. Time to specific diagnosis ranged from >1 week to >3 months. In the present series, most common clinical symptoms were abdominal pain in 20 (80%), weight loss in 21 (84%) and Anorexia in 18 (72%) patients. Similarly, Bernhard JS etal³ has

also mentioned for these features as most common symptoms in his series of 18 patients. Fever was present only in 6 (24%) of patients; which was not a common feature in abdominal tuberculosis. Diarrhoea was present in 12 (48%) of patient and nausea/ vomiting in 8 (32%) patients. These features were consistent with other studies³. Present study revealed abdominal tenderness in 12 (48%), abdominal distension/ ascites in 7 (28%), abdominal mass or doughy abdomen in 6 (24%) and hepatomegaly in 4 (16%) of patients. These signs were closely related to findings of Bernhard JS etal³. Sites of involvement of Abdominal tuberculosis were peritoneum in 9 (36%), ilececal region in 7 (28%), jejunum/ Ileum in 4 (16%) and colorectum in 2 (8%) of patient, where as involvement of liver was present in 2(8%) of patients which were later confirmed by liver histology. Two (8%) of patient had miliary presentation with involvement of lungs as well as other organs. Active pulmonary tuberculosis was noticed in 6 (24%) of patients. These features were closely related to findings of other workers^{3, 8-10}. A series of 99 patients carried out by Paustian FF etal¹⁰ has also noticed common involvement of ilaoeal region followed by colorectum and jejunum. Rare sites are, stomach, oesophagus and anal regions^{1, 11-13}. Present study revealed, anaemia in 16 (64%) leucocytosis in 4(16%) and monocytosis in 7 (28%) patients. Mantoux test (MT) was positive in 8(32%) of the patients. Therefore, this study revealed that in most of the patients with abdominal tuberculosis, MT may be negative which could be due to GI loss of protein and anorexia, due to which they may have hypo albuminemia. In this series, 12 (48%) of patients were detected to have hypo albuminaemia. These findings were close to previous studies^{1, 14}. Ascites was present in 7 (28%) patients and in ascitic fluid study all had straw coloured exudative fluid. One patient was detected to have AFB positive while all drained fluid (about 2 litres) was submitted to the laboratory. Eighteen patients were selected for barium contrast X ray of GIT, among them 8 patients had radiological features suggestive of Intestinal Tuberculosis, (such as ulceration, narrowing or deformity). Fourteen patients were selected for laparoscopy and among them 6 patients had morphology suggestive of tuberculosis (such as Tubercles) and all patients but one revealed histopathology suggestive of tuberculosis (such as caseating granuloma). One patient was negative for histopathology due probably to inappropriate selection of tissue for biopsy however this patient was cured with anti tubercular therapy. In present study, only 10 patients were selected for CT scan of abdomen and amongst them 6 patients had enlarged abdominal lymphnodes, and 4 patients had mass due

to matted loops or omental thickening. CT guided fine needle aspiration cytology performed in selected 8 patients and out of them 5 patients revealed caseating material most of these features were consistent with findings of previous worker¹⁵.

Conclusion

Abdominal tuberculosis is one of the common extra-pulmonary tubercular infections. The diagnosis of GI tuberculosis is often delayed. The onset usually is insidious with symptoms present for many months before diagnosis. A considerable number of patients can be diagnosed from common but non specific clinical features (like fever, weight loss, altered bowel habit, Abdominal pain and distension) and from response by anti tubercular therapy. Laparoscopic examination is the Gold standard for diagnosis of peritoneal tuberculosis. Although AFB detection is difficult, a representative tissue biopsy (when approachable) and radiological findings are good method of diagnosis of abdominal tuberculosis. Strongly suggestive clinical features with positive non specific investigation findings are also an indication for anti tubercular treatment in all endemic countries. Treatment of abdominal tuberculosis is no way different from that of other conventional anti tubercular therapy.

Reference

1. Harries A, Maher D and Uplekar M. TB a clinical manual for SEA 1997. 19-23
2. Rahim MA, Alam MN, Alam MR et al. A controlled clinical study of Ciprofloxacin in the Retreatment cases of Tuberculosis. Bangladesh Journal of Medicine 2001; 12:69-75.
3. Bernhard JS, Bhatia G, Knauer CM. Gastrointestinal Tuberculosis Jclin Gastroenterol 2001; 1 : 397-402
4. Raviglione MC, Brien RJ. Tuberculosis. In: Fauci AS, Braunwald E, Wilson JD, Editors,

- Harrison's Principles of Internal Medicine (14th ed.). Mc graw- Hill 1998; 1:1004-14.
5. Bernhard JS, Bhatia G, Knauer CM. Gastrointestinal tuberculosis an eighteen patient experience and review. J. Clin Gastroenterol 2000; 30:397.
 6. Karawi MA et al. Protean manifestations of Gastrointestinal tuberculosis 1995; 20:225.
 7. Marshall JB Tuberculosis of the Gastrointestinal Tract and peritoneum. Am J Gastroenterol 1993, 158:92.
 8. Jahukowaki A, Elwanol RK, Enaison DA. Clinical features of Abdominal Tuberculosis, J Infect. Dis 1993,88:989.
 9. Sherman S, Rohwedder JJ; Ravikishan KP, Weg JG. Tuberculous enteritis & peritonitis. Report of 36 general Hospital cases Arch Intern Med 1980; 506-8
 10. Paustian FF, Monto GL. Tuberculosis of the Intestines. Bockus HL editor, Gastroenterology (3rd ed). Philadelphia- SB Saunders, 1976: 750-77.
 11. Abrams JS, Holden WD. Tuberculosis of Gasrointestinal tact. Arch Surg 1964, 89:282-93
 12. Schulze K, Warner HA, Murray D. Intestinal Tuberculosis experience at Canadian Teaching Institute. Am J Med 1977,63:735-45.
 13. Mandal BK, Schofield PF. Abdominal tuberculosis in Britian practitioner 1976; 216:683-9.
 14. Chien RN, Lin PY, Fiaw Pl. hepatic Tuberculosis Comparision of miliary and local form. Infections. 1995; 215-8.
 15. Julien TY. Miscellaneous Diseases of the peritoneum and mesentery. Friedman SL, McQuaid KR, Grendell JH editors. Current Diagnosis and Treatment in Gastroenterology (2nd ed). Lange Medical Books/ Mcgraw Hill 2003,166-77