

# A Large Dermoid Cyst in the Floor of the Mouth

Upadhyaya C,<sup>1</sup> Paunju N,<sup>1</sup> Chaurasia N,<sup>1</sup> Srii R<sup>2</sup>

<sup>1</sup>Department of Oral and Maxillofacial Surgery

<sup>2</sup>Department of Oral Histology and Pathology

Kathmandu University School of Medical Sciences,  
Dhulikhel, Kavre.

## Corresponding Author

Chandan Upadhyaya

Department of Oral and Maxillofacial Surgery

Kathmandu University School of Medical Sciences,

Dhulikhel, Kavre.

E-mail: updch@yahoo.com

## Citation

Upadhyaya C, Paunju N, Chaurasia N, Srii R. A Large Dermoid Cyst in the Floor of the Mouth. *Kathmandu Univ Med J.* 2018;64(4):348-50.

## INTRODUCTION

Dermoid cysts are developmental lesions which arise either from the entrapped pluripotent cells (according to congenital theory), or by implantation of epithelial cells in deep tissue (according to acquired theory).<sup>1</sup> Dermoid cyst is covered with epithelium showing keratinization and are filled with keratinous sebum like material with evidence of skin derivatives.<sup>2,3</sup> Dermoid cysts account for 23% to 34% occurrence in the head and neck region.<sup>3</sup> The floor of mouth is the 2<sup>nd</sup> most common site of dermoid cyst in Head and Neck region after the lateral eyebrow and is most frequently located along the midline.<sup>3</sup>

In this report, we outline a case of a dermoid cyst diagnosed in a 12 year old boy and an evaluation with regard to its clinical and histopathological findings, differential diagnosis, and treatment is discussed.

## ABSTRACT

The dermoid cyst in the floor of mouth is considered to be a rare condition which comprises only 1.6 to 6.5% of all body dermoid cysts. Dermoid cyst in the floor of mouth may be congenital or acquired. The congenital form results from defective embryonic development and the acquired form may be due to traumatic or iatrogenic causes; and as a result of the occlusion of a sebaceous gland duct. We report an unusual case of huge dermoid cyst in the floor of the mouth in a 12 year old male who presented with progressively increasing swelling below his tongue and reviewed the relevant literature.

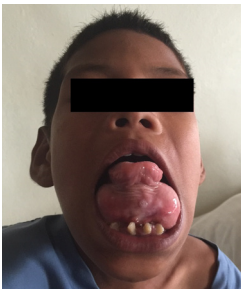## KEY WORDS

*Congenital lesions, Cysts, Dermoid cyst, Floor of the mouth*

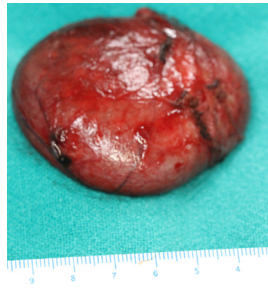## CASE REPORT

A 12 year old male patient was referred to the Department of OMFS of Dhulikhel Hospital for examination of a progressively increasing swelling below his tongue since birth. The patient had difficulty in chewing and swallowing of food and in speech. There was no history of previous trauma to any oral structures. The patient gave history of previous surgery (i.e. incision and drainage with aspiration of yellowish fluid) done 1 month back.

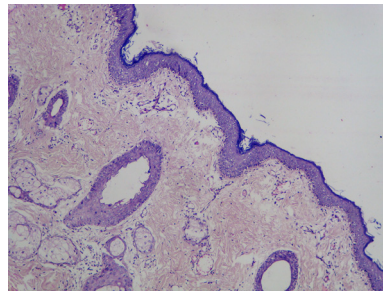
General and systemic examination of the patient was normal. On local oral examination, there was a non-tender, soft and fluctuant swelling of around 5x5 cm<sup>2</sup> in the anterior floor of the mouth below the tongue. There was superior and posterior displacement of the tongue. The patient had developing Class III malocclusion and generalized spacing secondary to cystic mass in floor of the mouth.



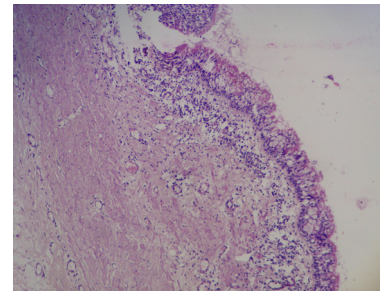
**Figure 1.** Cystic mass in the floor of the mouth resulting in elevation of tongue.



**Figure 2.** Excised cystic mass



**Figure 3.** 10 x shows cystic cavity lined by orthokeratinized stratified squamous epithelium with fibrous connective tissue wall consisting of hair follicle and sebaceous glands.



**Figure 4.** 10 x Focal areas showing pseudo stratified columnar ciliated epithelium with goblet cells.

Contrast CT scan was planned and done. The CT scan revealed a large well defined thick walled homogenous mass of approximately 5.5 x 5.4 x 4.8 cms below the tongue in the anterior floor of the mouth. The lesion had a pushing effect on the anterior mandible leading to enlarged mandible. It was abutting and splaying the body of mandible and was superiorly displacing the tongue.

Ultrasonography was performed which showed well defined cystic lesion measuring 50 x 45 mm at midline, floor of mouth. Multiple echogenic foci were noted within the lesion. No e/o calcification/vascularity within the lesion.

Under general anesthesia and with nasotracheal intubation, horizontal sublingual mucosal incision was given on anterior floor of mouth over the swelling. Underlying cystic lesion with fibro-vascular lining attached to genial tubercle with genial muscle attachment was carefully separated by blunt dissection and removed in toto. Intracystic content showed dirty white fluid with yellowish granules of keratin like flecks. The wound was closed with resorbable sutures after repositioning the genioglossus muscles. The sutures were removed on the fifth post-operative day.

Histopathological examination revealed a cystic lumen lined by orthokeratinized stratified squamous epithelium with focal areas showing ciliated tall columnar cells along with ovoid mucous cells. The supporting connective tissue capsule was fibro-collagenous with dense chronic inflammatory cell infiltration and dilated endothelial cell-lined capillaries. These findings were suggestive of a diagnosis of dermoid cyst.

The patient was well postoperatively and duly discharged and planned for regular follow-up in every 6 months. Definitive surgery for prognathic mandible will be carried out at around 18 years of age.

## DISCUSSION

Dermoid cysts of the floor of mouth are considered rare and have been the subject of a considerable number of researches.<sup>4</sup> Dermoid cysts of the mouth are most frequently located on the median line of the floor of the

mouth.<sup>2</sup> Although dermoid cyst typically manifest during 2<sup>nd</sup> or 3<sup>rd</sup> decade of life, it may be present since birth and with no gender predilection.<sup>2,5</sup>

Etiologically, dermoid cysts may be classified into 2 major categories: congenital and acquired forms.<sup>6</sup> The congenital type is derived from entrapment of epithelial cells during midline fusion in embryonic development. Acquired forms develop from traumatic or iatrogenic implantation of epithelial cells into surrounding tissues.<sup>6</sup>

Histologically, according to Meyer's classification, dermoid cyst in floor of the mouth can be classified into dermoid, epidermoid and teratoid/teratoma cysts.<sup>7</sup> All true dermoid cysts are lined by epidermis with the presence of adnexae such as sweat glands, sebaceous glands, hair and hair follicles. If no adnexa is present, the entity is termed as epidermoid cyst. If there are structures derived from all 3 germinal layers in the cystic wall, then the entity is called a teratoma or teratoid cyst.<sup>4</sup>

Anatomically, dermoid cyst is divided into median genioglossal, median geniohyoid and lateral cysts based on anatomic relationship between the cyst and the muscles of the floor of the mouth.<sup>7</sup>

Clinically, dermoid cyst presents as a painless, slow growing lesion.<sup>4</sup> The lesion usually displaces the tongue and hence the patient presents with dysphagia, dysphonia and dyspnea.<sup>1,3</sup> Sudden increase in size of the lesion can occur either due to onset of puberty when there is an increase in secretion of sebum from the sebaceous glands or due to infection occurring by blockage of salivary glands involved in the cyst or by implantation of oral microbials into the cyst through trauma.<sup>2,4</sup> This can result in pain, trismus, fever, dysphagia, odynophagia and cervical lymphadenopathy.<sup>2,4</sup>

The cyst contents are often keratinous, caseous, sebaceous, or purulent with hair, nails, fat globules, cholesterol and even cartilage.<sup>4</sup> Diagnostic imaging of the lesion includes ultrasonography, computed tomography, magnetic resonance imaging together with cytologic examination by Fine Needle Aspiration Cytology.<sup>3,4,8</sup> Plain radiographs and ortho-pantomogram are not always sufficient in making differential diagnosis.<sup>2,8</sup>

Differential diagnosis of cystic lesion of floor of the mouth is important because the recommended surgical technique is not exactly the same in all of them.<sup>2</sup> Differential diagnosis of the lesion include ranula, lipomas, acute infection, blockage of submandibular gland duct, neoplasm of the sublingual and minor salivary glands, cystic hygroma, thyroglossal cyst, neurofibroma, hemangioma, ludwig's angina and lymphangioma.<sup>2,4</sup>

The definite management of dermoid cyst is complete surgical excision.<sup>2,4</sup> The recurrence rate is very low and the fibrous capsule that surrounds the cyst makes it easy to be enucleated.<sup>2,4</sup> Treatment for small cyst above the geniohyoid muscle maybe done through intraoral approach and lead to very good cosmetic as well as functional results, whereas the cysts occurring below the geniohyoid muscle may require an extraoral approach.<sup>1,6</sup>

Prognosis is very good with very low incidence of relapse, usually related to bone remnant to the genial tubercles or to the hyoid bone.<sup>5-7,9</sup>

We report a rare case of dermoid cyst involving the floor of the mouth that was treated successfully with surgical excision. Based on the case report, it was possible to observe how the onset and progressive growth of a voluminous dermoid cyst of the floor of the mouth may interfere with function and with normal development of mandible. It is very important to differentially diagnose the lesion from other diseases and condition of the area and the need of appropriate imaging techniques for the same cannot be overlooked. The definite diagnosis of the disease is via histopathological examination. Surgical intervention is the only effective treatment for this kind of lesions and has a very good prognosis.

## REFERENCES

- Vieira EMM, Borges AH, Volpato LER, Porto AN, Carvalhosa AA, BotelhoGdA, Bandeca MC. Unusual dermoid cyst in oral cavity. *Case Rep Pathol*. 2014; Article ID 389752:1-4.
- Jain H, Singh S, Singh A. Giant sublingual dermoid cyst in floor of the mouth. *J Maxillofac Oral Surg*. 2012; 11(2):235-7.
- Marino R, Pentenero M, Familiari U, Gandolfo S. Dermoid cysts of the floor of the mouth: a case report. *J Clin Case Rep*. 2012; 2(9):doi1000150
- Seah TE, Sufyan W, Singh B. Case report of a dermoid cyst at the floor of the mouth. *Ann Acad Med Singapore*. 2004; 33:77-9.
- Jadwani S, Mishra B, Kallianpur S, Bansod S. Dermoid cyst of the floor of the mouth with abutment hair: a case report. *J Maxillofac Oral Surg*. 2009; 8(4): 388-9.
- Dillon J R, Avillo AJ, Nelson B. Dermoid cyst of the floor of the mouth. *Head Neck Pathol*. 2014; 9(3): 376-8.
- Makos C, Noussios G, Peios M, Gougousis S, Chouridis P. Dermoid cysts of the floor of the mouth: two case ceports. *Case Rep Med*. 2011; 2011 Article ID 362170.
- Kandogan T, Koc M, Vardar E, Selek E, Sezgin O. Sublingual epidermoid cyst: a case report. *J Med Case Rep*. 2007; doi20071:87.
- Verma S, Kushwala JK, Sonkar AA, Kumar R, Gupta R. Giant sublingual epidermoid cyst resembling plunging ranula. *Natl J Maxillofac Surg*. 2012; 3(2):211-3.