

Complete Right Ovarian Vein Thrombosis Extending to the Inferior Vena Cava during Early Postpartum Period in a Low Risk Patient

Fatema N,¹ Acharya Y,² Dahal R,³ Sayed A,² Al Yaqoubi HN¹

¹Department of Obstetrics and Gynaecology, Ibri Regional Hospital, Sultanate of Oman.

²Department of Epidemiology, Preventive and Evidence-based Medicine
Avalon University School of Medicine,
Curacao, Netherlands Antilles.

³Departmental of Internal Medicine
Saint Peter's University Hospital,
New Jersey, USA.

Corresponding Author

Yogesh Acharya

Department of Epidemiology, Preventive and Evidence-based Medicine

Avalon University School of Medicine,

Curacao, Netherlands Antilles

E-mail: dryogeshach@gmail.com

Citation

Fatema N, Acharya Y, Dahal R, Sayed A, Al Yaqoubi HN. Complete Right Ovarian Vein Thrombosis Extending to the Inferior Vena Cava during Early Postpartum Period in a Low Risk Patient. *Kathmandu Univ Med J.* 2019;67(3):251-3.

INTRODUCTION

Postpartum ovarian vein thrombosis (POVT) is rare (0.05 - 0.2% deliveries), but life-threatening complication of puerperium.^{1,2} Approximately 90% presents within two weeks of delivery, and women with twin pregnancy and multiparity are at increased risk.^{3,4} Here, we reported a 28-year-old female with no significant underlying risk factors, who was found to have right-sided complete ovarian vein thrombosis extending to the inferior vena cava.

CASE REPORT

A 28-year-old woman, para 01 presented four days after an uncomplicated cesarean delivery to our emergency department with the history of sudden onset of right lower

ABSTRACT

Postpartum ovarian vein thrombosis is rare but life-threatening complication of puerperium. It predominantly occurs in the right side of the abdomen, mimicking various other conditions like acute appendicitis, ureteral stones or tubo-ovarian abscess. It is imperative to envisage the possibility of this rare disease even in an uncomplicated pregnancy. Here, we reported a 28-year-old female with no significant underlying risk factors who presented with high-grade fever and right lower abdominal pain after four days of an uncomplicated cesarean delivery. A right-sided complete ovarian vein thrombosis extending to the inferior vena cava was diagnosed and subsequently managed with long-term anticoagulant therapy. She had an uneventful recovery, with repeat imaging after three months showing complete resolution of thrombus.

KEY WORDS

Ovarian vein thrombosis, Postpartum, Pregnancy complications

abdominal pain accompanied by high-grade fever. Her antenatal and post-operative period was uneventful. She did not have a thrombotic disorder in the past and there was no family history of thrombophilia. She was on low molecular weight heparin (LMWH) (enoxaparin 40 mg once daily) for deep vein thrombosis (DVT) prophylaxis during her previous hospital stay.

On examination, the patient was average built and weighed 65 kilograms. She was febrile with rectal temperature 38°C, pulse 102 beat/min and BP 118/70 mm of Hg. Physical examination revealed localized tenderness as well as rebound tenderness in the right lower abdomen. Pelvic examination was otherwise normal. Her laboratory test during admission showed hemoglobin 10.66 g/dl, platelet 405x10³/unit/cubic mm, WBC 13.5x10³/cubic mm,

hematocrit 33.4%, and elevated C-reactive protein (CRP) (128 mg/l). She had normal liver and renal function test with negative blood cultures.

Radiological investigations were performed with clinical suspicion of right tubo-ovarian mass, appendicular abscess or right ovarian vein thrombophlebitis. Ultrasonography (USG) abdomen revealed a cord-like structure in the lower right abdomen arising next to the right ovary, which could not be visualized clearly. Computed tomography (CT) of the abdomen with contrast showed dilated right ovarian vein (1.8 cm in diameter) with complete thrombosis measuring 1.8 cm x 0.8 cm x 0.6 cm and extending into the inferior vena cava (IVC) (fig. 1). Similarly, lower limbs venous duplex USG had no signs of DVT. Electrocardiography and echocardiography were normal.

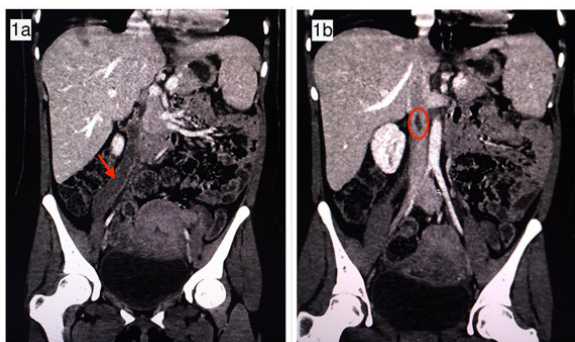


Figure 1. Computerized tomography (CT) scan - coronal section: (a) an enlarged ovarian vein representing complete thrombosis (arrow) (b) thrombus in inferior vena cava (red circle)

Based on CT, she was diagnosed with POVT, and immediately started on LMWH (enoxaparin 1 mg/kg every 12 hours) with warfarin and antibiotic (ceftriaxone 1 gm BID for 5 days). LMWH was discontinued after the normalized ratio (INR) had attained therapeutic levels (INR level: 2-3). Warfarin was continued for three months till the convincing evidence of complete regression was obtained on follow-up CT-abdomen (fig. 2).

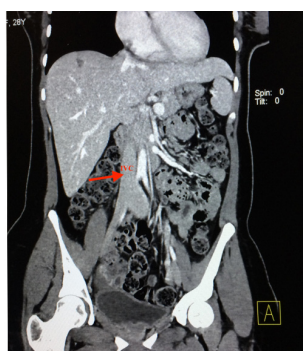


Figure 2. Follow up computerized tomography (coronal section) image after three months with no evidence of thrombus in the inferior vena cava.

DISCUSSION

POVT is the presence of thrombus in the ovarian vein that has the potential to propagate into the systemic circulation. Its importance lies in the fact that it possesses a significant risk of mortality and morbidity during the puerperium.

POVT is common in cesarean deliveries (0.1% cesarean vs. 0.02% vaginal) and multiple/twin pregnancies.² Hypercoagulable pregnancy state in combination with venous stasis and endothelial injury (Virchow's triad) is the nidus for thrombus.⁵ Other, possible causes include puerperal state, gynecological/gastrointestinal malignancies, hypercoagulable conditions, surgery, pelvic inflammatory disease, and sepsis. But it may occur also in low-risk patients without impending signs.⁶ The very first case reported in 1956 had the right ovarian vein thrombosis with the involvement of the inferior vena cava. Interestingly, an extension to IVC is relatively rare and there is a dearth of literature reporting it.⁷ Our patients had no discernible risk and thrombosis extended to IVC.

Nearly 80-90% of POVT occurs in the right ovarian vein, possibly explained based on its anatomic position and blood flow dynamics.⁸ Right ovarian vein drains in the IVC at an acute angle, whereas left drains in the left renal vein at the right angle. In the immediate postpartum period, anterograde flow is observed in the right ovarian vein increasing the risk for thrombus formation. Contrary, retrograde flow is protective and observed in the left ovarian vein.⁹ Similarly; the right ovarian vein is longer and has many valves, which may act as a nidus for thrombus formation. Venous stasis occurs during pregnancy and following childbirth as veins enlarge to accommodate increased blood volume. Finally, dextrorotation of the involuting uterus can also compress the right ovarian vein causing stasis of the already enlarged right ovarian vein leading to thrombosis.⁸

Patients present with fever (80%) and pain in right iliac fossa (55%), left lower quadrant (3.6%), flank and chest.^{6,10} Symptoms usually occur after 2-15 days postpartum.⁸ A high index of vigilance is important as female after abortion and preterm deliveries can present only with fever, potentially obscuring the diagnosis.¹¹ Our patient presented with an acute abdominal pain/tenderness in right lower abdomen along with fever, tachycardia, and leukocytosis.

Diagnosis is challenging as many conditions mimics POVT, including but not limited to acute appendicitis, broad-ligament, adnexal torsion, pelvic infection/abscess, pyelonephritis, retroperitoneal lymphadenopathy and puerperal endometritis.^{6,8}

Inflammatory markers, like CRP and WBC, are usually elevated. But their role is limited to negative predictive importance. They are commonly high during pregnancy, reaching highest around delivery and declining thereafter.¹² Therefore, serial decrement after delivery favors normal postpartum while increment needs to be investigated. In our case, both the CRP and WBC were elevated.

Magnetic resonance imaging (MRI), CT, and USG aid in the diagnosis with MRI and CT having sensitivity more than 90%, and USG around 50%.⁶ A Doppler USG shows an anechoic tubular structure without blood flow. CT

demonstrates a thrombotic mass anterior to the psoas muscle, with a round low attenuation center, surrounded by higher attenuation margins of enhancing vessel wall.⁷ CT or MRI is preferred for the precise diagnosis as ultrasound has low sensitivity and specificity.¹³ In our case, presumptive diagnosis was made by USG, which showed large, dilated, tubular structure originated from the right adnexa. It was later confirmed with the CT scan. It revealed ovarian vein enlargement with perivascular edema, low-density appearance of venous lumen and extension of thrombus into IVC. We preferred CT to MRI due to unavailability of MRI in our institutional setting.

POVT can have a catastrophic complication, if associated with sepsis and extension to major veins, like renal veins and inferior vena cava. Other fatal consequences include ovarian infarction, ureteral obstruction, hydronephrosis or renal failure, pulmonary emboli, and death.^{2,3} Pulmonary embolism is seen in 1/3 of cases.^{1,8,12} Our case had an uneventful pregnancy course without any history of previous thromboembolic events.

Management depends on oral anticoagulation, antibiotics, and heparin. Although proven benefit is only established with anticoagulation therapy, a definitive guideline regarding duration and safety is lacking. Therefore,

anticoagulation rests on the general DVT prophylaxis in high-risk patients, with subsequent management of the venous thrombosis. Resolution is typically observed after 1-2 weeks of anticoagulation initiation, and many authors, including the British Committee for Standards in Haematology, recommend treatment to be continued for 3-6 months.^{14,15}

Antibiotics are conservatively used for a week, although is no definitive evidence for its usefulness.¹³ Fever of unknown origin that persists despite antibiotics is a predictive clue to the formation of thrombus in the postpartum period.¹ Roles of endovascular or surgical procedures, such as thrombectomy, cava filters, ovarian or cava vein ligation, is limited and reserved in cases with treatment failure, contraindication to anticoagulation, and high risk of pulmonary embolism.^{16,17}

POVT is a rare but serious complication of puerperium. Early diagnosis is crucial to prevent unnecessary interventional procedures. A high index of suspicion is important as untreated ovarian vein thrombosis can have catastrophic complications. Multidisciplinary management strategies, starting with early anticoagulation and close monitoring, will significantly reduce the patient morbidity and mortality.

REFERENCES

1. Togan T, Turan H, Ciftci E, Çiftci C. Ovarian and Renal Vein Thrombosis: A Rare Cause of Fever Outer the Postpartum Period. *Case Rep Obstet Gynecol.* 2015;2015:817862.
2. Ortín Font X, Ugarriza A, Espax RM, et al. Postpartum ovarian vein thrombosis. *Thrombosis and Haemostasis.* 2005;93(5):1004–5.
3. Sinha D, Yasmin H, Samra JS. Postpartum inferior vena cava and ovarian vein thrombosis—a case report and literature review. *Journal of Obstetrics and Gynaecology.* 2005;25(3):312–13.
4. Klima DA, Snyder TE. Postpartum ovarian vein thrombosis. *Obstet Gynecol.* 2008;111(2 Pt 1):431–5.
5. Stafford M, Fleming T, Khalil A. Idiopathic ovarian vein thrombosis: A rare cause of pelvic pain - case report and review of literature. *Aust New Zeal J ObstetGynaecol.* 2010;50(3):299–301.
6. Sorbi F, Mannini L, Aldinucci M, Ghizzoni V, Fambrini M. Ovarian Vein Thrombosis Presenting as Acute Abdomen in Puerperium. *J ClinDiagn Res.* 2016;10(2):QD03–4.
7. Lee E-H, Im CY, Kim JW. Ultrasound diagnosis of postpartum ovarian vein thrombosis: case report. *Ultrasound Obstet Gynecol.* 2001;18:384–6.
8. Arslan H, Ada S, Celik S, Toptaş T. Postpartum ovarian vein and inferior vena cava thrombosis. *Case Rep Med.* 2014;2014:609187.
9. Simons GR, Piwnica-Worms DR, Goldhaber SZ. Ovarian vein thrombosis. *Am Heart J.* 1993;126(3 Pt 1):641–7.
10. Suleyman T, Gultekin H, Abdulkadir G, et al. Acute right lower quadrant abdominal pain as the presenting symptom of ovarian vein thrombosis in pregnancy. *J Obstet Gynaecol Res.* 2008;34(4 Pt 2):680–2.
11. Dunning DR, Gallaspy JW, Wise RB, Otterson WN. Postpartum ovarian vein thrombophlebitis: a review. *Obstet Gynecol Surv.* 1991;46 (7):415–27.
12. Dougan C, Phillips R, Harley I, Benson G, Anbazhagan A. Postpartum ovarian vein thrombosis. *The Obstetrician and Gynaecologist.* 2016;18:291–9.
13. Herek D, Kocyigit A, Yagci AB. Total right ovarian vein thrombosis after cesarean section. *J Emerg Med.* 2015;48(1):e25–7.
14. De Stefano V, Martinelli I. Abdominal thrombosis of splanchnic, renal and ovarian veins. *Best Pract Res Clin Haematol.* 2012;25(3):253–64.
15. Tait C, Baglin T, Watson H, Laffan M, Makris M, Perry D, et al. Guidelines on the investigation and management of venous thrombosis at unusual sites. *Br J Haematol.* 2012;159(1):28–38.
16. Takach TJ, Cervera RD, Gregoric ID. Ovarian vein and caval thrombosis. *Tex Heart Inst J.* 2005;32(4):579–82.
17. Royo P, Alonso-Burgos A, García-Manero M, Lecumberri R, Alcázar JL. Postpartum ovarian vein thrombosis after cesarean delivery: a case report. *J Med Case Rep.* 2008;2:105.