

Choledochoduodenostomy: a study of 28 consecutive cases

Gupta BS¹

¹Assoc. Prof., Dept. of Surgery, College of Medical Sciences, Nepal

Abstract

Objectives: Choledocholithiasis is a common problem in South Asia. Proper drainage of the CBD is essential to reduce the chance of residual stones and recurrent stones. The paper highlights the surgical management of choledocholithiasis by side to side choledochoduodenostomy and the post surgical complications.

Method: 28 cases of choledocholithiasis treated by choledochoduodenostomy between March 1995 and June 2003 were studied. After pre operative diagnosis and per operative confirmation, side to side choledochoduodenostomy was done. It is a triangulated anastomosis between the bile duct and post bulbar duodenum using single layer interrupted suture. The cases were meticulously followed up for detecting complications

Results: 79% of the patients who underwent choledochoduodenostomy were female and majority (43%) belonged to the 51 to 60 age group. All the patients selected for CDD had a dilated common duct of at least 1.5 cm diameter and 71% of them had multiple stones. 79% were asymptomatic during the follow up, two patients developed wound infection. 18% developed alkaline reflux gastritis and only one patient suffered from recurrent cholangitis because of inadequate stoma size. No case of "sump syndrome" was observed in this series.

Conclusion: Side to side CDD is an easy, effective and definitive method of decompression, especially when there are multiple stones in a dilated CBD.

Keywords: Choledochoduodenostomy,

Cholecystectomy with exploration of the common bile duct (CBD) remains the gold standard for the treatment of choledocholithiasis. Proper drainage of the CBD is essential to reduce the chance of residual stones and recurrent stones which may require further intervention and increase the morbidity and mortality of the patients¹. Side to side choledochoduodenostomy (CDD) is an established procedure for effecting internal drainage of the CBD² and is performed for multiple common duct calculi or biliary sludge in a dilated duct^{3, 4}. There is however some controversies regarding the development of long term complications^{3, 4, 5, 6}. This paper reviews twenty eight patients with choledocholithiasis for whom CDD was done after bile duct exploration. It highlights the surgical management of choledocholithiasis by CDD and the post surgical complications in a South Asian setting.

Material and methods

All the cases in this study have been selected from the surgical out patient department of SSKM hospital, Calcutta, India and College of Medical Sciences, Nepal, between March 1995 and June 2003 (Table 1). All the patients presented with signs and symptoms of obstructive jaundice. Cases of bile duct obstruction other than calculus disease have been excluded from the series.

All the patients underwent routine investigative protocol. Diagnosis of bile duct pathology was established primarily by Liver Function Test (LFT) and Ultrasonography (USG) in all cases. Endoscopic Retrograde Cholangio Pancreatogram (ERCP) was

done in only 8 patients for improved delineation of the biliary tract. Percutaneous Trans-Hepatic Cholangiogram (PTC), CT scan, and MR Cholangiogram were not necessary for diagnostic purpose in any of the patients.

Preoperative preparation was undertaken meticulously with particular emphasis on prevention of bleeding tendencies and renal impairment. The final decision on the choice of drainage procedure for the CBD was reserved till the patients were examined peroperatively and the investigation findings were corroborated. Only those patients with common bile duct dilated more than 1.5cm, with multiple stones, biliary sludge or stone impacted in the lower end of CBD were selected for CDD (Table 5).

After cholecystectomy, choledochotomy of about 2.5cm length was done through conventional longitudinal incision. A horizontal duodenotomy, slightly smaller than the choledochotomy, was made after Kocherisation of the duodenum. The lower and upper halves of the choledochotomy were anastomosed with the posterior and anterior wall of the duodenotomy respectively, applying interrupted sutures with 3/0 Vicryl. Thus a triangulated anastomosis between the CBD and duodenum with a stoma size of about 2.5cm was made, effecting drainage of the biliary tract.

Correspondence

Dr. Bodhisatwa Sen Gupta
Dept. of Surgery,
College of Medical Sciences, Nepal
Email: bodhisatwasengupta@rediffmail.com

Four patients were lost during follow-up, while the rest were followed up between one and three years with an objective of identifying adequacy of biliary drainage and identifying any complication resulting from the operative procedure. Follow up investigations depended primarily on LFT and USG. Patients who developed post operative complications were also assessed with upper GI Endoscopy to assess the adequacy of the stoma. Barium study, ERCP and pneumocholangiogram were done in a few. Biliary Scintiscan was not available for assessment in any of the patients.

Results

Out of 28 patients who underwent CDD, 22 (79%) were female, and 6 (21%) were male. 43% (n=28) of the patients were between the age group of 51 to 60, while 31% belonged to the 41 to 50 age group (Table 1). Twenty one (75%) patients had features of obstructive jaundice and 16 (57%) had pain upper abdomen on presentation. Features of cholangitis were evident in 12 (43%) patients and only one patient had presented with Pancreatitis. None of the patients who underwent CDD were asymptomatic (Table2).

All the patients selected for CDD had a dilated

common duct of at least 1.5 cm diameter. Twenty patients (71%) had multiple stones within the bile duct and only one had a single stone impacted in the lower end of the duct. Seven patients (25%) were detected to have biliary sludge necessitating the adequate drainage of the bile duct.

Twenty two patients (79%) were asymptomatic during the follow up. Five patients (18%) suffered from attacks of epigastric pain, nausea, bilious vomiting and subsequent endoscopy revealed alkaline reflux gastritis. Two patients (7%) developed wound infection while two others developed features of cholangitis about four weeks after the procedure. One of the patients with cholangitis had persistent symptoms and was later detected as having an inadequate stoma. The other patient was asymptomatic after the initial attack. Only one patient developed an anastomotic fistula followed by peritonitis and finally succumbed to septicemia. The average post operative hospital stay was about eleven days. Follow up of at least three years was possible for eighteen patients while five were followed up for at least one year. During this period none of the patients developed cholangitis, sump syndrome and recurrent or residual stone.

Table 1. Age and Sex distribution

Age (yrs)	No. of cases	Female	Male
Less than 20	0	0	0
21-30	0	0	0
31-40	4	3	1
41-50	9	7	2
51-60	12	10	2
61-70	3	2	1
71-80	0	0	0
Total	28	22	6

Table 2. Presenting features

Presenting Features	No. of cases
Abdominal Pain	16
Jaundice	21
Fever with Chills	12
Nausea / Vomiting	7
Pancreatitis	1
Asymptomatic	0

Table3. Peroperative findings

Peroperative findings	No. of Cases
Dilated CBD > 1.5cm	28
Multiple Stones	20
Single Stone (impacted)	1
Biliary sludge	7

Table 4. Complications of CDD

Complications	No. of Cases
Wound Infection	2
Cholangitis	2
Biliary fistula	1
Residual / Recurrent Stone	0
Alkaline reflux gastritis	5
Sump Syndrome	0
Septicemia	1

Table 5. Some Indications for CDD

- Dilated common duct > 15mm with stones
- Multiple common bile duct stones
- Intra hepatic calculi
- Primary common bile duct stones
- Residual / Recurrent stones
- Stone impacted in the ampulla of Vater

Figure 1 USG showing dilated CBD with calculus

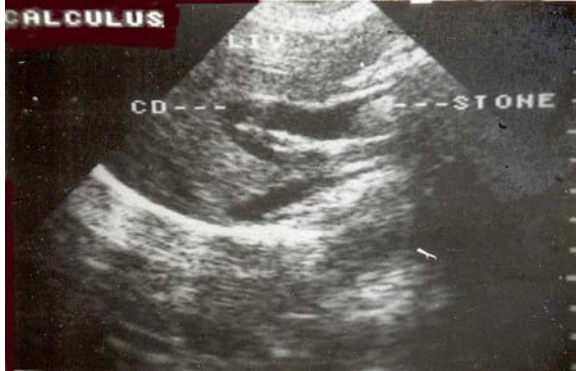

Figure 2 Posterior layer of CDD in place

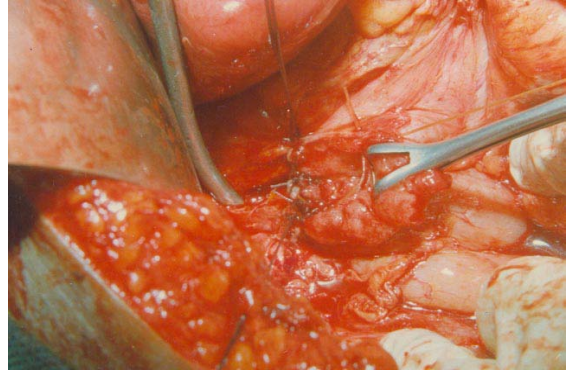


Figure 3 ERCP showing dilated CBD with multiple calculi

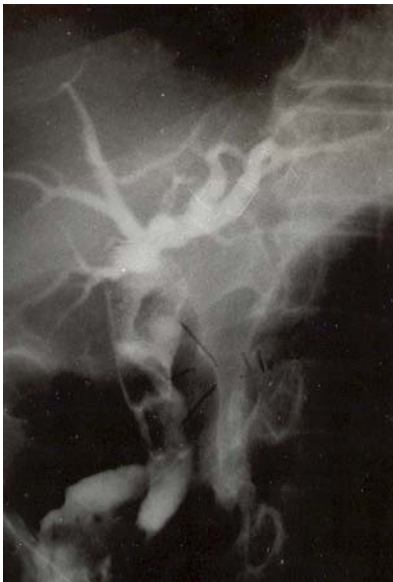

Figure 4 Side to side Choledochoduodenostomy completed

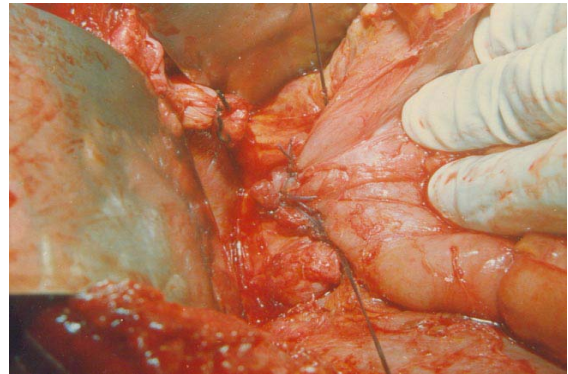
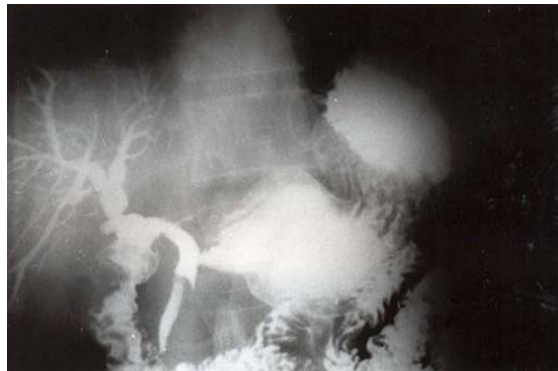

Figure 5 Post CDD Barium study of the biliary tract



Discussion

The first successful CDD was performed by Sprengel in 1913⁷ and ever since has been accepted as an easy and effective measure to drain the CBD. In 1928 Florcken reported 100 cases and the results were excellent. It was Florcken who established the need for an adequate stoma to prevent cholangitis and stressed that “more the barium the better” in barium study of the biliary tract⁸.

There are a number of indications for performing CDD (Table 5). The common indications as noted in this series and various others^{1, 3, 5, 6} are dilated CBD (>15mm) with stones and multiple CBD stones.

That CDD virtually eliminates the chance of residual or recurrent stones is evident from the findings of the present study (0%), as well as those done earlier^{5, 6, 8, 9}. Following exploration of bile duct and T-Tube drainage 7 to 10% patients develop symptoms due to residual or recurrent stones.

The primary objection to CDD is that it produces ascending cholangitis. However, it was proved unequivocally through animal experiments⁹ and experience gathered from patients^{1, 5, 6, 9}, that a stoma size greater than 2.5cm prevents cholangitis. The patient in my series who developed persistent cholangitis had a stoma of smaller size.

Another objection to CDD is the incidence of “sump syndrome” due to the blind pouch created in the distal CBD with the accumulation of debris^{2, 11}. It can either present with recurrent cholangitis or features of malabsorption and steatorrhea. However none of the series published by Madden⁹, Stuart & Hoerr⁴, Thomas¹⁰, Dagenshein⁵ and Srivengadesh⁶ have recorded complications attributable to sump syndrome. None of my patients developed complication which could be due to sump syndrome. There are a few case reports of cholangiocarcinoma occurring years after CDD^{12, 13}. No such case has come to the author’s notice during his clinical practice or during this study.

With laparoscopic cholecystectomy getting popular, endoscopic sphincterotomy (ES) has become a popular method of extracting stones from the CBD and effecting drainage. Laparoscopic choledocholithotomy, transcystic extraction of stones with Dormia basket, laparoscopic choledochoduodenostomy¹⁴ are now available in technically advanced nations. In the setting of South Asia, CDD will continue to be an important adjunct to the treatment of choledocholithiasis for some more years to come.

Conclusion

There is a significant risk of developing a recurrent or residual stones following choledocholithotomy and T-tube drainage. This risk is virtually eliminated if choledochoduodenostomy is done following exploration of bile duct. Claims of ominous complications like recurrent cholangitis and “sump syndrome” resulting from CDD have not been substantiated. Side to side CDD is an easy, effective and definitive method of decompression, especially when there are multiple stones in a dilated CBD.

References

1. Freund H. et al. Choledochoduodenostomy in the treatment of benign biliary tract disease. *Arch Surg.* 1977, 112: 1032-36.
2. Baker A.R et al. Sump Syndrome following choledochoduodenostomy and its Endoscopic treatment. *Br J Surg.* 1985, 72: 433-435
3. Schen CJ. et al. Choledochoduodenostomy as an adjunct to Choledocholithotomy. *Surg Gynaecol Obstet* 1978, 146: 25-32
4. Stuart M. et al. Late results of the side to side choledochoduodenostomy and of transduodenal Sphincterotomy for benign disorders. *AM J Surg* 1972: 123 67-72
5. Dagenshein G.A. Choledochoduodenostomy: An 18 yr study of 175 consecutive cases. *Surgery.* 1974, 76: 319-24
6. Srivengadesh G et al. Evaluation of long term results of choledochoduodenostomy for benign biliary obstruction. *Trop. Gastroenterol.* 2003, 24(4): 205-7
7. Glenn F. et al. Historical events in biliary tract surgery. *Archives of Surgery.* 1966, 93: 848-852
8. Florcken H. *Zentralbi.Chir.* No3. 1928 cited by Dagenshein G.A. Choledochoduodenostomy: An 18 yr study of 175 consecutive cases. *Surgery.* 1974, 76: 319-24
9. Madden JL et al. Choledochoduodenostomy: One unjustly maligned surgical procedure? *Am. J. Surg.* 1970, 119: 45-51
10. Thomas CG et al. Effectiveness of choledochoduodenostomy and transduodenal sphincteroplasty in the treatment of benign obstruction of the common duct. *Ann. Surg.* 1971, 173: 845-56
11. Jones SA. et al. Sphincteroplasty in the treatment of biliary tract disease. *Surg. Clin. N. Am.* 1983, 53: 1123-37
12. Maeda A. et al. Bile duct cancer developing 21 years after choledochoduodenostomy. *Dig Surg.* 2003, 20(4): 331-4
13. Kuo KK et al. Bile duct cancer developing 25 years after choledochoduodenostomy: a case report. *Kaoshiung J Med Sci.* 2002,

18(9): 466-70
14 Millat B. Prospective evaluation of 121
consecutive patients undergoing laparoscopic

treatment of choledocholithiasis. Br. J. Surg.
1995, 82: 1266-69