

Case of Schizencephaly: a case report

Pradhan M¹, Malla KK², Chowdhury SR³, Baral MR⁴

¹Medical Officer, ²Lecturer, ³Intern, ⁴ Professor, Dept. of Paediatrics, KMCTH

Abstract

Schizencephaly is a rare developmental disorder of neuronal migration, characterized by early focal destruction of the germinal matrix and surrounding brain before the cerebral hemispheres are fully formed at 1-5 months of gestation. The lesion is most likely related to multiple aetiologies including genetic, toxic, metabolic, vascular or infectious agents. This case is reported due to its rarity. The prevalence of schizencephaly is very uncommon internationally.

Key Words: Schizencephaly, septum pellucidum, septo-optic dysplasia.

Schizencephaly is a disorder characterized by cleft in cerebral mantle, which communicates between the subarachnoid space laterally and ventricular system medially. This disorder was originally described by Wadsworth and Yakolev.¹ Their original work describes schizencephaly to result from failure of normal migration of primitive neuroblasts resulting in cerebral cleft. The cardinal neuropathological features are i) Hemispheric cleft ii) communication of subarachnoid space with lateral ventricle medially iii) Infolding of grey matter along the cleft iv) Multiple associated intracranial malformations including polymicrogyria, absent septum pellucidum, optic nerve hypoplasia. The presentation and outcome are variable i.e. hemiparesis, developmental delay, microcephaly, mental retardation and most patients have seizures.

Case Report:

A 5 month old male child residing in Diktel was admitted in paediatric ward of KMCTH on 13/12/60 with complaint of excessive cry and uprolling of eyes with jitteriness since two months of age. There was no frank convulsion. In the last one week before admission, child had developed fever for which he had been taken to a local hospital of Diktel and treated as a case of meningitis. Injection ceftriaxone had been given for 4 days. Fever subsided on the second day of treatment of ceftriaxone.

The child was delivered full term normally at home with maternal history of fever at 5 months of pregnancy with no other complications. He cried soon after birth and there were no postnatal

complications. There is no history of consanguineous marriage.

On physical examination child had macrocephaly, no dysmorphism of face, sunset appearance and convergent squint present, fixing of gaze absent, No vision and hearing, Macewen's sign (crack pot) positive, Anterior fontanelle was bulged, non pulsatile and measured 7cm by 7cm. Sutures were widely open, transillumination test was positive. There was a global delay in the developmental milestones. Muscle tone showed occasional spasticity with normal reflexes. Vitals were normal. Anthropometric measurements of weight and length were within normal limits, except the head circumference was 44 cm (90th centile). Serial measurements of head circumference taken for 5 days showed no increment in head circumference i.e. 44cm.

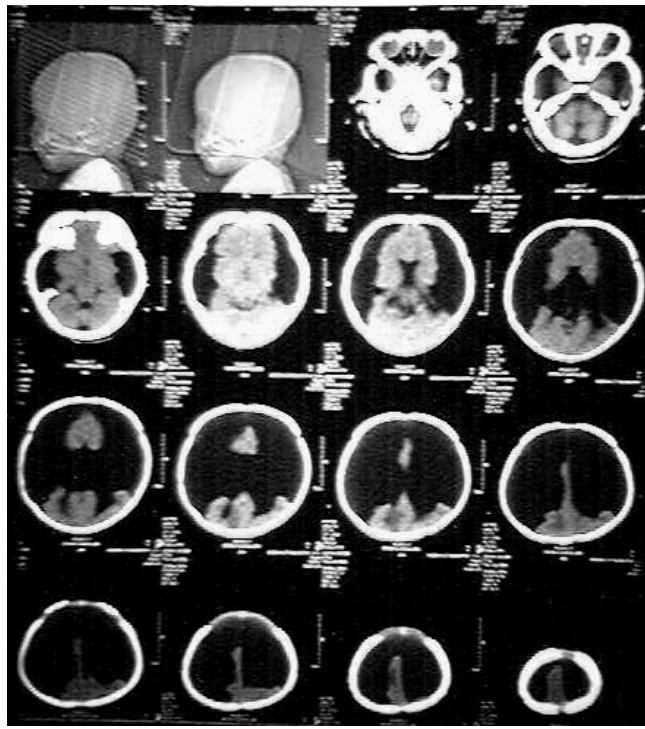
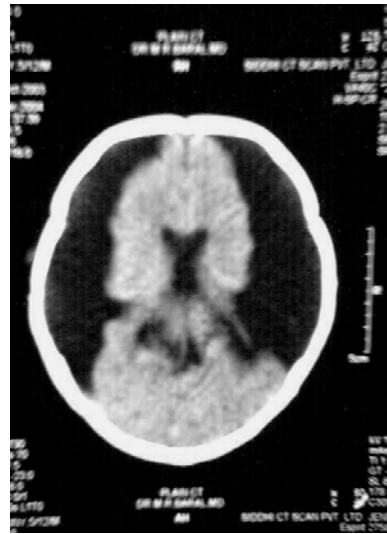
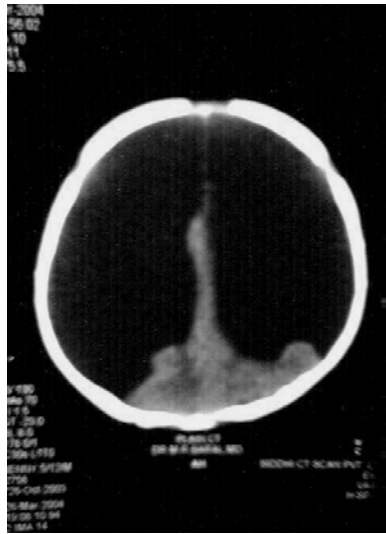
The child was admitted with provisional diagnosis of bacterial meningitis with differential diagnosis partially treated meningitis with hydrocephalus.

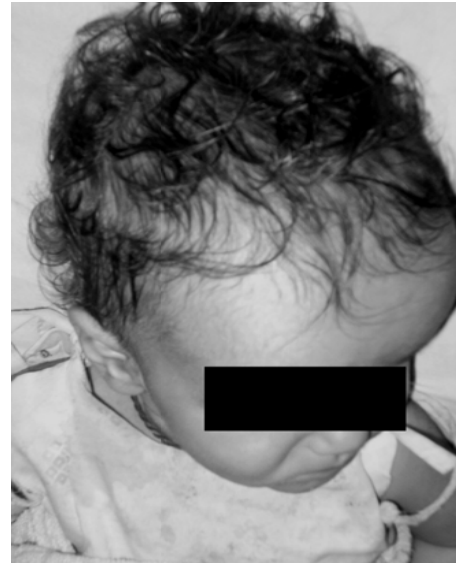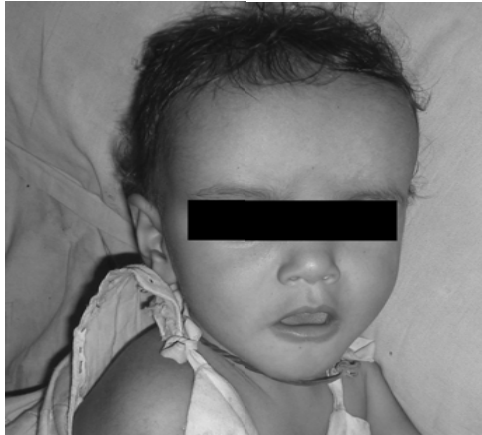Investigations done revealed normal Hb, Tc, Dc. EEG showed abnormal record with seizure pattern. CT scan showed-OPEN LIP SCHIZENCEPHALY. Monoventricle with falx and interhemispheric fissure -Implies a Septo-optic dysplasia. TORCH screening and MRI was suggested but the party was not willing for these tests. Thus the diagnosis was clinched with the help of CT scan report. The prognosis was explained to the parents. Counselling was given and physiotherapy was advised.

Correspondence

Dr. Mallika Pradhan,
Medical Officer, Dept. of Paediatrics, Kathmandu Medical College,
Sinamangal, KTM
Email: mallika_pradhan@hotmail.com

CT scan of schizencephaly





Discussion

Schizencephaly is an uncommon disorder of neuronal migration characterized by CSF filled cleft, lined by grey matter and extends across the entire cerebral hemisphere from ependyma to the periphery of the brain.^{1,2} . Types of Schizencephaly:

- Type I : Closed type (lips of cleft are fused)
- Type II : Open type (clefts are separated)
- Type II is more common than type I

Incidence

It is present at birth with no sex predilection. The lesion is related to multiple aetiologies including genetic, toxic, metabolic, vascular or infectious agents such as cytomegalo virus infections. As genetic cause, it is found to have a mutant gene,EMX2^{3,4,5}

Clinical features

Severity of symptoms is related to the extent of cortex involved in the defect. The symptoms of schizencephaly are variable. In closed type (Unilateral case)- Mild hemiparesis and seizure but normal development. In open type there is mild to moderate developmental delay with hemiparesis. In bilateral clefts there is severe mental deficits, severe motor anomalies including spastic quadraparesis⁶. Frequently these patients present with blindness often associated with optic nerve hypoplasia.

Investigations

MRI is the imaging modality of choice because of its superior differentiation of grey matter and its ability to image in more than one plane.^{7,8} . Identification of gray matter lining the cleft is the pathognomic finding in differentiating schizencephaly from disorders like porencephaly.^{11,12} Other modalities of choice are CT Scan, Ultrasound but the degree of confidence is not as high as MRI.

Treatment

It consists of treatment of seizures, physiotherapy, and in cases that are complicated by hydrocephalus ,a ventriculoperitoneal shunt is needed.

Prognosis

It depends upon the amount of brain involved. In open lip schizencephaly the patients die at early age. Death is mainly due to failure to thrive, chronic infections and respiratory problems. Whereas in closed lip schizencephaly patients may not present until later in infancy and they live upto adulthood.

Conclusion

Schizencephaly is a rare congenital disorder of cerebral cortical development which mainly manifests as two types i.e. open type and closed type for diagnostic purposes. Most of the cases (80-90%) present with absent septum pellucidum. Presentation is variable with poor prognosis.

Acknowledgement

We would like to thank Dr. Raju Pradhan for his radiological support which has helped us to come to a diagnosis.

References

1. Denis D, Chateil JF, Brun M, Brissaud O, Lacombe D, Fontan D, Flurin V, Pedespan J. Schizencephaly : Clinical imaging features in 30 infantile cases. *Brain Dev* 2000 Dec ; 22(8):475-83
2. Iannetti P, Nigro G, Spalice A, Faiella A, Boncinelli E. Cytomegalovirus infection and schizencephaly: case report *Ana Neuronal* 1998 Jan ; 43(1); 123-7
3. Pati S, Helmbrecht GD. Congenital schizencephaly associated with utero warfarin exposure *Reprod Toxicol* 1994 Mar- Apr 8(2) : 115-20
4. Capra-V; De-Marco-P; Moroni-A; Faiella-A; Brunelli-S; Tortori-Donati-P; Andreussi-I; Boncinelli-E; Cama-A Schizencephaly : Surgical features and new molecular genetic results. *Emr J Pediatr Surg* 1996 dec ; suppl 1:27-9
5. Al-Qudah-AA Clinical patterns of neuronal migration disorder & parental consanguinity. *J T Prop Pediatr*.1998 Dec ; 44(6):351-4
6. Gasparetto EL, Warszawiak D, de Carvalho Neto A, Benites Filho PR, Bruck I, Antoniuk S. Septo optic dysplasia plus a case report. *Arq Neuropsiquitar* 2003 Sep; 671-6
7. Hayashi N, Tsutsumi Y, Barkovich AJ. Morphological features and associated anomalies of schizencephaly in the clinical population: detailed analysis of MR images. *Neuroradiology* 2002 May ; 44(5):418-27 Epub 2002 Feb
8. Granata T, Battaglia G, D'Incerti L, Franceschetti S, Spreafico R, Battino D, Savoiaro M, Avanzini G. Schizencephaly: neuroradiologic and epileptologic findings. *Epilepsia*. 1996 Dec;37(12):1185-93.