

## Intermediate uveitis: a hospital based study

Malla OK<sup>1</sup>, Karki DB<sup>2</sup>, Byanju RN<sup>3</sup>, Shrestha S<sup>4</sup>

<sup>1</sup>Visiting consultant ophthalmologist, <sup>2</sup>Senior ophthalmologist, <sup>3</sup> Senior ophthalmologist, <sup>4</sup>MD Resident, Nepal Eye Hospital

---

### Abstract

Intermediate uveitis affecting pars plana, peripheral retina and underlying choroid affects primarily healthy children and young adults. **Objective:** To study the components of intermediate uveitis at Nepal Eye Hospital in the year 2003 August to 2004 March. **Materials and Methods:** A prospective study was done in patients with intermediate uveitis visiting Nepal Eye Hospital. Sample size was 50. Specially designed proforma of intermediate uveitis was used to collect particulars of the patients, history, clinical examination findings, investigation reports, management protocols used and the final visual outcome. **Results:** Intermediate uveitis was seen more in 20 to 29 years age group (38%) and more prevalent in males (52%). Among the study population farmers constituted maximum proportion (36%) and Mongoloid origin was mostly affected (30%). High number of patients were from the central development region with highest proportion from Dhading district (34%). Anterior segment affection with keratic precipitates and anterior chamber cells were noted in 72% of involved eyes. Vitreous cells were noted in all affected eyes while 4% had vitreous snow banking and 3% had vitreous snow balls. Most of the patients (52%) received between topical steroid and posterior subtenon injection of Triamcinolone. Visual Acuity was improved in 52% of cases and remained static in 46%.while deteriorated in 2%. **Conclusion:** Significantly high number of patients with intermediate uveitis has been reported from the central development region, mainly from Dhading, Kathmandu and Nuwakot districts. People in their third decade were found to be commonly involved and Mongloid origin were more commonly affected. Anterior chamber spill over was seen in higher percentage of patients than described in literature. As the patients presented in milder forms, visual acuity improved is 52% of cases with the treatment protocol followed.

---

Intermediate uveitis is an idiopathic, insidious, inflammatory disease affecting the pars plana, peripheral retina and underlying choroid<sup>1</sup>. It accounts for 8% of all cases of uveitis and affects primarily healthy children and young adults<sup>2</sup>.

Inspite of advanced investigational and research facilities intermediate uveitis still remains a significant cause of visual impairment in the developing and also in the developed countries. Intermediate uveitis is a clinical condition which runs a chronic course and gives rise to a number of complications like complicated cataract, cystoid macular oedema, vitreous haemorrhage, secondary glaucoma, vitreous membranes and neovascularization. It has been found that different systemic diseases like multiple sclerosis, lyme disease are associated with intermediate uveitis globally. Whether the situation has anything to do in Nepal is yet to be seen.

Intermediate uveitis, running a chronic course and sometimes being misdiagnosed, as the presenting symptoms are minimal to begin with, can lead to permanent visual impairment. The disease has been frequently observed in ophthalmological clinical

practice. This holds true also in Nepalese context. The disease has been frequently encountered in Nepal Eye Hospital outpatient clinic and accounted for 5% of the cases in an analysis of 400 cases of posterior segment affections attending Nepal Eye Hospital<sup>3</sup>. Our observation in Nepal Eye Hospital had shown that the disease has been seen more in certain ethnic group i.e. Mongoloid and in the residents of Nuwakot and Dhading. This disease entity although frequently encountered, has not been studied in Nepalese population and hence the study was conducted at NEH with the objective to find out the prevalence, systemic association, clinical presentation, ethnicity, demographic profile, management outcome and complications of intermediate uveitis.

---

### Correspondence

Dr. O. K. Malla  
Visiting Consultant Ophthalmologist,  
Nepal Eye Hospital, Tripureshwor, Kathmandu

## **Objectives**

### **General:**

To study the components of intermediate uveitis at Nepal Eye Hospital in the year 2003 August to 2004 March.

### **Specific:**

1. To study the prevalence of intermediate uveitis.
2. To study the association of intermediate uveitis with systemic diseases.
3. To study the management outcome following treatment of intermediate uveitis
4. To study the complications of intermediate uveitis.

## **Materials and methods**

It was a prospective study done in Nepal Eye Hospital. The study was conducted from August 2003 through March 2004. The target population was the patients with Intermediate Uveitis visiting Nepal Eye Hospital. Convenient sampling was done. Sample size was 50. A especially designed performa of intermediate uveitis was used to collect particulars of the patients, history, clinical examination findings, investigation reports, management protocols used and the final visual outcome. Informed consent was taken from all the patients enrolled in the study. Pre-testing was done in ten patients with intermediate uveitis.

### **Exclusion criteria**

1. Patients having other ocular diseases
2. Patients on long term treatment for systemic diseases (on steroids, immunosuppressives or anti- cancer drugs).

The examination procedure consisted of history taking, Snellen acuity charting, slit lamp bio-

microscopy and funduscopy with 78 diopter lens in all cases. All patients also underwent indirect ophthalmoscopy with scleral depression and intra ocular pressure measurement with schiotz tonometer. The study was monitored and supervised by the principal investigator through out the study period. Data were entered on the daily basis by the research team in the computer and data were analyzed using the SPSS program.

## **Results**

Out of 35,320 new cases visiting the outpatient department of Nepal Eye Hospital from 1st of August 2003 to the end of March 2004, 72 cases of intermediate uveitis were identified which were approximately 2.04 cases per thousand.

The minimum age of the patient in this study was found to be six years where as the maximum was seventy years and the mean age was 29.72 with standard deviation 12.933.

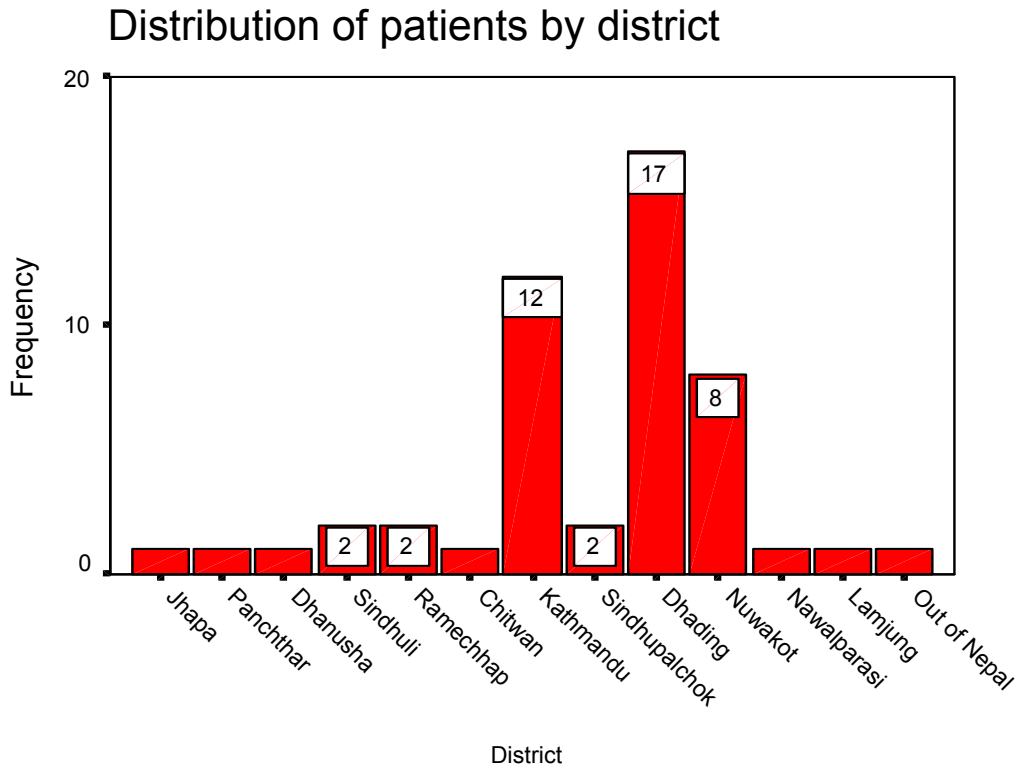
Intermediate uveitis was seen more in 20 to 29 years age group (38%, n=19) and least common before 10 years and after 50 years.

The distribution of male and female patients having intermediate uveitis was almost equal with slightly more male preponderance (52%).

The disease was noted to be more common among farmers (36%, n=18) followed by housewives (28%, n=14) and students (28%, n=14). People of business class and labors were found to be significantly less affected.

Among the study population, Mongoloids were found to be mostly affected (30%, n=15) followed by Brahmins (28%, n=14). Newars (20%, n=10) and Chhettris (18%, n=9) were found to be in almost equal proportion whereas other than these four ethnic group, were found to be in significantly in low proportion.

Figure:1



Intermediate uveitis was found to be in highest proportion in residents of Dhading district (34%, n=17) among the study population.

Forty two percent had bilateral involvement of the eye while 58% had unilateral involvement.

90 percent of the patients reported blurring of vision and 72% patients reported floaters. Only 12% of patients complained of pain. Similarly, only 5% of patients had photophobia.

60% of patients presented in less than one month of the onset of symptoms.

Among the patient included in the study no other associated diseases were found except pulmonary tuberculosis in 8% of cases.

Anterior segment affection with keratic precipitates and anterior chamber cells were noted in 72% of cases. All patients had normal intraocular pressure. Vitreous cells were noted in all the affected eyes.

Table: 1

#### Vitreous-Snow Balls

	Right eye	Left eye
No	47(94%)	47(94%)
Yes	3(6%)	3(6%)
Total	50(100%)	50(100%)

Among the study population, vitreous snowballs were observed in equal proportion in both the eyes (6% in each eye).

**Table: 2**

**Vitreous-Snowbanking**

	Right eye	Left eye
No	48(96%)	48(96%)
Yes	2(4%)	2(4%)
Total	50(100%)	50(100%)

Among the study population, vitreous snowbanking was observed in 4% of cases in both the eyes.

**Table: 3**

**Retina**

	Right eye	Left eye
Normal	47(94%)	49(98%)
Abnormal	3(6%)	1(2%)
Total	50(100%)	50(100%)

It was found that retina was normal in most of the cases (94% in right eye and 98% in left eye). Laboratory findings of the patients were not significant.

**Management of Intermediate Uveitis**

Of all the patients, 96% received topical steroid, 54% received posterior subtenons steroid injection among which 26% received both the topical and periocular injections; only 4% received systemic corticosteroid. No patient required antimetabolites/ immunosuppressives or laser photocoagulation except one patient who received cryotherapy.

Cystoid macular oedema was noted in one patient on presentation. Complicated cataract was noted in one patient on presentation. Similarly, three patients had mild vitreous haemorrhage which resolved spontaneously.

The visual acuity improved in 52% of cases and remained static in 46% while deteriorated in 2%.

**Discussion**

Pars planitis is an inflammatory disease, usually affecting healthy young people, commonly within

Regarding chest x-ray in posterior /anterior view, among the patients, 8% had abnormal findings.

first three decades of life. In our study the disease was noticed to be more common in 20 to 29 years age group, least common before 10 years and after 50 years. This finding is consistent with other reports that this disease commonly affects young adults ranging from 2nd to 4th decade although age at presentation may vary from 5 years to over 65 years. Albert and Jakobiec had stated that the age of onset of intermediate uveitis ranges from 5- 65 years of age with the mean and median occurring in the 3rd decade of life<sup>13</sup>. Intermediate uveitis occurring in childhood (below 15 years) have a worse visual acuity both at the initial diagnosis and at follow up than those presenting at adulthood<sup>14</sup>. But this is not the same in our study.

As reported by Arellanes Garcia L et al we also noticed slightly more occurrence of intermediate uveitis in males compared to female (52% vs. 42%)<sup>15</sup>.

The literature reviewed didn't show increased prevalence of intermediate uveitis in any specific community or ethnic group. Hegan first reported familial occurrence of intermediate uveitis in 1963 and many other families have been documented since then<sup>16,17</sup>. In our study, individuals of Mongoloid origin were noticed to be more commonly affected (30%), followed by Brahmin (28%) and Newar community (20%). Regarding the laterality of the disease, bilateral involvement was observed in 80% of cases by M Nagpal et al whereas our study showed bilateral involvement in only 42% of cases<sup>2</sup>.

The most common mode of presentation in our study was blurring of vision (90%), followed by floaters (72%) and pain (12%). Photophobia was the least common mode of presentation (10%). This finding is consistent with the available reports on intermediate uveitis<sup>13</sup>.

The anterior segment manifestations in the involved eyes were keratic precipitates (72%, n=36) and anterior chamber cells (72%, n=36). Vitreous cells were present in all the affected eyes which included 64% right eye and 70% left eye. The vitreous snowbanking (4% in each eye) and snowballs (6% in each eye) were less frequent in our study. Periphlebitis and neovascularization at vitreous base were present in 6%, of cases leading to vitreous haemorrhage. These features are not consistent with the other reports on intermediate uveitis where snowbanking, phlebitis are more common<sup>15</sup>.

Complication of the disease was present in five cases, of which one was cystoid macular oedema, second, complicated cataract and 3 cases of vitreous haemorrhage which differ from the cases reported in the literature. Prieto et al have reported the complications of intermediate uveitis as macular oedema 47.7%, vitreous opacities 38.6%, papillitis 38.6%, vasculitis 36.4% and cataract 20.5%<sup>18</sup>.

The treatment modalities followed in our study were corticosteroids in 98% of cases (topical, systemic and/or periocular injection) and cryotherapy in 2% of cases. As most of the patients presented early to the hospital, the above-mentioned treatment modalities only were sufficient.

In our study, the visual outcome improved in 52% of cases and remained static in 46% while 2% had deteriorated visual acuity. A. Nagpal et al quoted that visual acuity improved in 30.6%, remained stable in 39.3% and deteriorated in 16.11% in an analysis done in 608 eyes of intermediate uveitis in Indian patients<sup>19</sup>.

## Conclusion

Significantly high number of patients with intermediate uveitis has been reported from the central development region, mainly from Dhading, Kathmandu and Nuwakot districts. People in their third decade were found to be commonly involved and Mongoloid origin were more commonly involved. Anterior chamber spill over was seen in higher percentage of patients than described in literature. As the patients presented in milder forms, visual acuity improved in 52% of cases with the treatment protocol followed.

## Acknowledgement

The authors would like to extend their heartiest gratitude to Nepal Health Research Council for providing grant to conduct this research. We would like to acknowledge Dr. Keshab Prasad Adhikari, Member Secretary of Nepal Eye Hospital, Executive Board for consenting to conduct this study in the hospital. Similarly, we would like to thank Mr. Susan Man Shrestha, Bio-Statistician of Nepal Health Research Council and Ms Rakhee Joshi, Librarian of Nepal Health Research Council for contributing in data analysis and literature search respectively.

## References

1. J. K.Kanski; Principles of Ophthalmology; 2002, Fourth Edition; 306-308.
2. Manish Nagpal, Kamal Nagpal, PN Nagpal: Pars Planitis: Current Review; Ophthalmology Today; Volume 1; Number 1; November-December 2000; 24-26.
3. Karki DB et al; Analysis of 400 cases of posterior segment diseases visiting retina clinic of Nepal Eye Hospital; Kathmandu University medical Journal; Volume 1; Number 3; July- Sept 2003; 161-165.
4. Schepens CL; Examination of the ora serrata region: Its clinical practice; Chicago; Year book Medical; 1989.
5. Schpens Cl; L'inflammation de la region de l' "ora serrata" et ses sequelles; Bull Mem Soc Franc Ophthalmol 1950; 63: 113.
6. Schpens Cl; A new ophthalmoscopic demonstration; Trans Am Acad Ophthalmol Otolaryngol 1947; 51: 289.
7. Brockhurst RJ, Schepens Cl, Okamura ID. Uveitis. I : Gonioscopy. AM J Ophthalmol 1956; 42: 545.
8. Brockhurst RJ, Schepens Cl, Okamura ID. Uveitis .II. Peripheral uveitis, Clinical description and differential diagnosis, Am J Ophthalmol 1960; 49: 1257.
9. Brockhurst RJ, Schepens Cl, Okamura ID. Uveitis. III. Peripheral Uveitis. Pathogenesis,

- aetiology and treatment. *Am J Ophthalmol* 1961; 51: 19.
10. Kimura SJ, Hogan MJ. Chronic cyclitis. *Arch Ophthalmol* 1964; 71:193.
  11. Welsh RB, Maumenee AE, Whalen HE. Peripheral posterior segment inflammation, vitreous opacities, and oedema of the posterior pole; *Arch Ophthalmol* 1960; 64:540.
  12. Bolch-Michel E, Nussenblatt R. International Uveitis Study Group recommendations for the evaluation of intra-ocular inflammatory disease. *Am J Ophthalmol* 1987; 103:234.
  13. Albert and Jakobiec: Principles and practice of Ophthalmology; Second Edition; 2000; 1225-1235.
  14. Guest S, Funkhouser E, Lightman S. Pars planitis: a comparison of childhood onset and adult onset disease. *Clin Experiment Ophthalmol*. 2001 Apr; 29(2): 81-4.
  15. Arellanes- Gracia L, Navarro-Lopez L, Recillas- Gispert C; Pars planitis in the Mexican Mestizo population: ocular findings, treatment, and visual outcome; *Ocul Immunol Inflamm*. 2003 Mar; 11(1): 53-60.
  16. Kimura SJ, Hogan MJ. Chronic cyclitis. *Arch Ophthalmol* 1964;71:193.
  17. Witmer R, Korner G. Uveitis in kindesalter. *Ophthalmologica* 1966; 152:277.
  18. Prieto JF, Dios E, Gutierrez JM, Mayo Aet all: Pars planitis: epidemiology, treatment, and association with multiple sclerosis; *Ocul Immunol Inflamm*.2001 Jun; 9(2): 93-102.
  19. A. Nagpal et all: Intermediate uveitis- a long term follow up study; 61st Annual Conference of All India Ophthalmological Society Joint Meeting with Nepal Ophthalmic Society; January 2003; 275.