

Odontogenic origin of necrotizing fasciitis of head and neck - a case report

KC Toran¹, Nath S², Shrestha S¹, Rana BBS JB³

¹Asst. Professor, Dept. of ENT-HNS, ²Professor, Dept. of Surgery, ³Consultant, Dept. of Medicine, KMCTH

Abstract

Necrotizing fasciitis (NF) of head and neck is a fulminant infection associated with necrosis of connective tissue which spreads along the fascial planes with high mortality rate. It is usually polymicrobial, odontogenic and occurs more frequently in immunocompromised patients. Because of the rarity of the disease, early diagnosis and early management is often delayed. We present a diabetic patient who developed NF of head and neck following tooth extraction. Because of vigorous teamwork he could be saved from the fatal disease but required extensive plastic repair. Every clinician should be aware of such a disease, particularly in immunocompromised patients and necessitates earliest diagnosis and intervention to save their life.

Keywords: Necrotizing fasciitis, necrotizing soft tissue infections,

NF of the head and neck is a multimicrobial, uncommon soft tissue infection that spreads very quickly. It is characterized by the formation of large necrotic lesions and gas, located in the subcutaneous tissue and superficial fascia. As the disease progresses, muscles and skin involvement develops, giving rise to myonecrosis, that pass through the infected fascia. If the NF does not receive early surgical care, generalized toxicity occurs with multisystem organ failure.¹

Immunosuppressed states of peripheral vascular disease like diabetes mellitus have been reported the most common predisposing factors, although the illness has also been detected in healthy patients.^{2,3} Treatment should be started earlier with broad spectrum antibiotics, surgical care and rectification of the underlying cause.

It is important that airway be maintained open, since they may be compromised as a result of inflammation. Intubation may be difficult and tracheostomy may be required.⁴

Case report

A 32 years old male was referred to us from the dental department with 5 days history of severe pain and swelling of the right face, neck and upper part of the chest following extraction of the right lower molar tooth. He was an insulin dependant diabetic who had not revealed the uncontrolled status of his blood sugar.

On examination he was very ill looking and toxic and crying in agony. He was tachypnoic but without stridor. The right side of the face, neck and upper part

of the chest were swollen with tense, warm skin and crepitus could be felt. Per oral examination was not possible because of severe trismus and pain.

His random blood sugar was 418mg/dl. There was leucocytosis and raised polymorphs. His serum renal parameters were normal except slightly elevated blood urea (50mg/dl). Urine sugar was 3plus without any signs of nephropathy. Blood culture was sterile. X-ray soft tissue neck was masqueraded by discrete opaque shadows due to the presence of subcutaneous gas. Chest x-ray and ECG were unremarkable except sinus tachycardia.

CT scan of the neck and skull base revealed soft tissue swelling and abscess formation in the right sided parapharyngeal, retropharyngeal, parotid, masseteric spaces with plenty of gas shadows. Pharynx and air columns were pushed to the opposite side.

Antibiotics were changed to intravenous ceftriaxone, cloxacillin and metronidazole. Intravenous hydration was started. Ryle's tube was not inserted at the moment because of the high chance of perforating the pharyngeal abscess leading to aspiration. Medical consultation was sought regarding his uncontrolled diabetes and soluble insulin was started with frequent monitoring of blood and urine sugar and serum electrolytes.

Correspondence

Dr. Toran KC
Consultant, Department of ENT,
Kathmandu Medical College

Following informed consent he was operated on the very next day under general anaesthesia. Prior to this, tracheostomy was done under local anaesthetic and Ryle's tube was inserted. The infection was approached through right modified Blair's incision with Rusch extension. There was plenty of dirty gray very foul smelling pus in almost all the cavities of the neck extending above up to the zygomatic space. Pus was sent for Gram staining and culture sensitivity. This later revealed mixed flora without any growth.

On the next day of surgery the whole overlying skin had turned black with patchy slough. All the dead tissues were debrided. He was labelled as suffering from necrotizing fasciitis and transferred to the isolation room.

Vigorous debridement and dressing was done every day with povidone iodine solution and Eusol[®]. On every second or third day he was taken to the Operation Theatre for extensive debridement. Tissue clearing was done including almost a centimetre of a healthy margin. After 6 weeks of regular surgical and medical management the wound started becoming better and granulation tissue started spouting, but leaving facial paralysis and a very large tissue defect in the head and neck requiring plastic repair.

Most of the cheek defect was covered with the deltopectoral flap. Multiple tiny burr holes were made on the bare parietal bone without perforating the inner table so that granulation tissue would grow. And these regions were later grafted with partial thickness skin graft in different sitting. At the mean time, as no general anaesthesia would require, he was decannulated. Following complete recovery he was discharged after 5 months of hospital stay.

Fig. 1 At the recovery stage following deltopectoral pedicle and superficial thickness skin grafting.

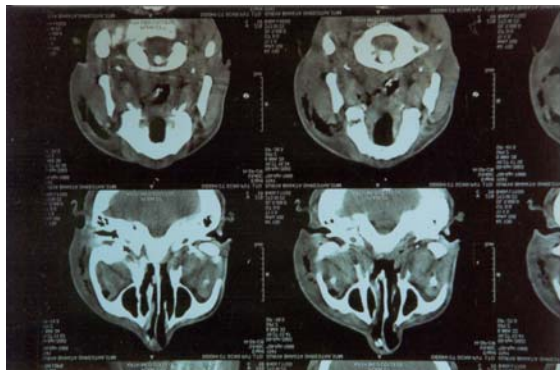
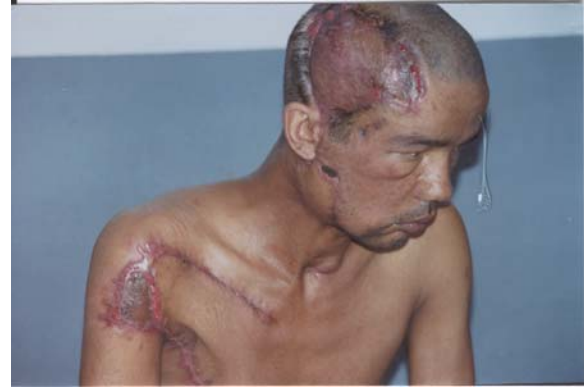

Fig 2. CT in axial cuts showing infections with gas shadows in right head and neck spaces.



Discussion

The pathological changes of NF include thrombosis of blood vessels, suppuration and necrosis of the superficial fascia with subcutaneous fat.⁵ Although many underlying disease processes predispose patients to NF, three common factors are invariably present: (1) impairment of immune system (e.g., diabetes mellitus, malignancy, alcoholism); (2) compromise of the fascial blood vessels; and (3) the presence of micro organisms that are able to proliferate within this area.⁶

The most common source of NF of the head and neck is odontogenic infection in immune compromised patient.^{7,8,1,2} In our case also lower molar tooth was extracted in an uncontrolled diabetic patient somewhere else. NF usually starts with local inflammation and fever that advances rapidly along the fascial planes resulting in extensive tissue necrosis and skin changes over 24-48 hours hence lymphangitis and lymphadenitis are usually absent. Thrombosis of the cutaneous vessels leads to cutaneous ischemia, tissue gangrene, necrosis and sloughing. Presence of vesiculation, ecchymosis, crepitus, anaesthesia and necrosis are indicative of advance disease.⁹ Our case progressed to necrotic stage but without any organ dysfunction which is common for most of the cases.

NF is polymicrobial and less commonly monomicrobial infection. Aerobic micro organisms, particularly group A β -hemolytic streptococci and staphylococci were initially considered to be the causal agents in NF. It was later demonstrated that they are strict anaerobes played a very important role representing a mixed or synergistic infection. Micro organisms of the bacteroid groups; Proteus, Coli forms and Peptostreptococcus have been isolated as well as Enterobacter and Pseudomonas.^{1,2,3} The bacteriology in our case was always polymicrobes

and no growth could be obtained in any of the samples, probably due to the use of broad spectrum antibiotics.

The fulminating nature of the necrotic process is the result of symbiotic relationship between both types of bacteria, with an alternative of O₂ reduction potential and a micro environment that fosters the growth of anaerobic bacteria. Bacterial enzymes and cell wall components play an essential role in local tissue destruction of the infection and systemic toxicity. Cutaneous lesion is detected around 4th to 5th day.^{10,1,2,3} If necrotizing process continues to spread, it involves the neighbouring tissues and provokes local and systemic complications such as neck organ involvement, pneumonia, pulmonary abscess, vascular erosion, venous thrombosis and cranial neuropathies.¹⁰

Computerized tomography and magnetic resonance are the most useful imaging tools for the early diagnosis of NF.^{1,4} Even so over diagnostic tools like imaging, frozen section biopsies or ¹¹¹Indium labelled WBC scan are controversial and may delay the treatment.¹¹ But clinching the diagnosis of NF is not always easy and may be easily confused with cellulites of dental origin, erysipelas, deep neck space infections and gangrenous necrosis due to clostridium.⁷

Treatment of NF usually involves a combination of early and aggressive debridement, antibiotics and intensive supportive care, including modalities such as hyperbaric oxygen.¹² Despite of the best management the mortality due to NF ranges from 25 to 40%.^{11,13} Intensive rehabilitation is often necessary to return the patient to premorbid function once the acute infection is treated.

Conclusion

In view of the potentially catastrophic consequences of this life threatening infection, it would be prudent to include NF in the differential diagnosis, particularly in immunocompromised patients with unexplained pain and swelling. Early presentation and diagnosis, supportive measures, broad spectrum antibiotics prompt and aggressive surgical debridement and finally rehabilitation remains the cornerstone of good management.

References

1. Umeda M, Minamikawa T, Komalusubara H et al., Necrotizing Fasciitis caused by dental infection : a retrospective analysis of nine cases and a review of the literature.

2. Rapoport Y, Himelfarb MZ, Zikk D et al., Cervical Necrotizing Fasciitis of odontogenic origin. *Oral Surg Oral Med Oral Pathol.* 1991; 72: 15-18.
3. Chidzonga MM. Necrotizing Fasciitis of the cervical region in an AIDS patient: report of a case. *J Oral Maxillofac Surg.* 1996; 54:638-640.
4. Whitesides L, Cotto-Cumba C, Mayers RA. Cervical Necrotizing Fasciitis of odontogenic origin: a case report and review of twelve cases. *J Oral Maxillofac Surg.* 2000; 58: 144-151.
5. Howard JR, Surgical Infections. In: Schwartz SI, Shires TG, Spencer FC eds. *Principle of Surgery.* Mc Graw-Hill, 1999: 126-128.
6. Dunn DL. Infection. In: Greenfield LJ, Mullholland M, Oldham KT eds. *Surgery Scientific Principles and Practice.* Lippincot-Raven, Philadelphia, 1997: 173-174.
7. Jemenez Y, Bagan JV, Murillo J et al., Odontogenic infections, Complications, Systemic manifestations. *Med Oral Pathol Oral Cir Bucal.* 2004; 9suppl: 139-147.
8. Rubin MM, Cozzy GM. Fatal Necrotizing Mediastinitis as a complication of an odontogenic infection. *J Oral Maxillofac Surg.* 1987; 45: 529-533.
9. Darmstadt GL. Cutaneous bacterial infection. In Berham RE, Kliegman RG, Jenson HB eds. *Nelson Text book of Pediatrics.* Philadelphia: WB Saunders Company; 2000; 2028-2036.
10. Robertson JB, Harper JL, Jauch EC. Mortality associated with Cervico facial Necrotizing Fasciitis. *Oral Surg Oral Med Oral Pathol Oral Radiol Endol.* 1996; 82: 264-267.
11. Barie PS. The Laboratory risk Indicator for Necrotizing Fasciitis (RLINEC) Score: useful tool or paralysis by analysis? *Critic Care Med.* 2004; 32(7):1618-1619.
12. AK Lalwani, Kaplan MJ. Mediastinal and thoracic complication of Necrotizing Fasciitis of the Head and Neck. *Head and Neck.* 1991; 13: 531-539.
13. Skorina J, Kaufman D. Necrotizing Fasciitis originating from pinna polychondritis. *Otolaryngol Head Neck Surg.* 1995; 113: 467-469.

Photo Indices

- 1. CT in axial cuts showing infections with gas shadows in right head and neck spaces.**
- 2. At the recovery stage following Deltopectoral pedicle and superficial thickness skin grafting.**