

Sturge – Weber syndrome

Kumar V¹, Prasad BK²

¹Associate Professor & Head, Dept. of Pediatrics, ²Prof. & Head, Dept. of Forensic Medicine National Medical College & Teaching Hospital, Birgunj

Abstract

Sturge – Weber syndrome (SWS) is a rare disorder that occur with a frequency of approximately 1 per 50,000¹. It is a neurocutaneous syndrome, characterized by a facial vascular birthmark and neurological abnormalities. The hallmark is intracranial vascular angioma, most often involving the occipital and posterior parietal lobes, but it can also affect the other cortical regions². An ipsilateral facial cutaneous vascular malformation (port wine nevus) usually affects the upper face³. Other clinical findings associated with SWS are seizures, glaucoma, hemiparesis, mental retardation and delayed developmental milestones^{4,5}. This article reports a case of 8 years old boy who presented with weakness of right half of body since birth, mental retardation and delayed developmental milestones. Clinical examination revealed deep purple nevus on left lower face, and less power of left upper & lower limbs. X-ray skull showed calcification. C.T. Scan of brain revealed curvilinear calcification with focal atrophy.

Key words:- Port wine Nevus, Hemiparesis, curvilinear calcification.

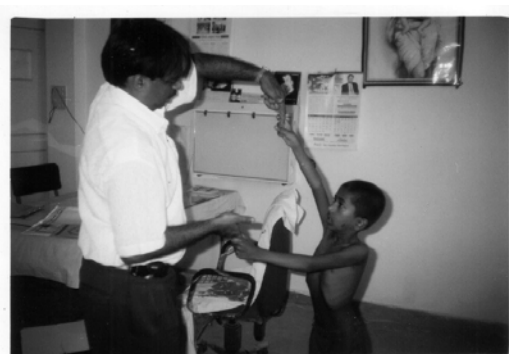Case report

M A 8 years, Muslim boy, resident of a tarai area of Nepal (Bara district) presented to our paediatric OPD with weakness of right half of the body since birth and unable to speak clearly. He was mentally subnormal and his developmental milestones were delayed. He had sitting with support at one year, walking with support at 2 years. He started to speak monosyllable sound at one year. At 4 years he was able to say small sentences but not clearly. His dental development was also delayed. There was no history of seizure. The boy was youngest among seven brothers. There was no similar problem in other family members. He was born at full term and delivered normally. Exclusive breast-feeding was given upto the age of one year.

On examination, the child was moderately built and nourished. He was alert and answering to questioning with difficulty. His weight, height and head circumference were 20 kg, 112 cm. & 40 cm. respectively. His heart rate was 86/min, respiratory rate was 20/min and blood pressure was 100/70 mm Hg. There was a deep purple nevus of 1.5 cm x 0.5 cm on left lower face. Eye examination revealed no glaucoma or any other significant finding. On central nervous system examination there was weakness of right half of body. Power of upper and lower limbs on left side was

5/5 but on right side was 4/5. Other CNS finding was normal.

His investigations revealed Hb, TLC and DLC of 11.2 gm/dl, 7200 cells/cmm, P58, and L34 respectively. His



Photograph 1 – Showing weakness of right upper limb.

ESR was 20 mm in 1st hour. CSF examination was normal. X-ray skull showed calcification. C.T. scan of brain revealed curvilinear calcification with focal atrophy.

Correspondence

Dr. Vijay Kumar, M.D. (Paediatrics)
Associate Professor & HOD, Department of Pediatrics, National Medical College & Teaching Hospital, Birgunj, Nepal, E-mail: drkumarvijay@hotmail.com

Discussion

Sturge – Weber syndrome presents with port-wine stain, seizures, hemi-paresis, intracranial calcification and mental retardation⁶. The basic lesion in SWS is congenital capillary hemangioma. This involves skin of face and cervical area. It is usually unilateral involvement. Overlying leptomeninges are richly vascular and underlying brain becomes atrophied and calcified⁷.

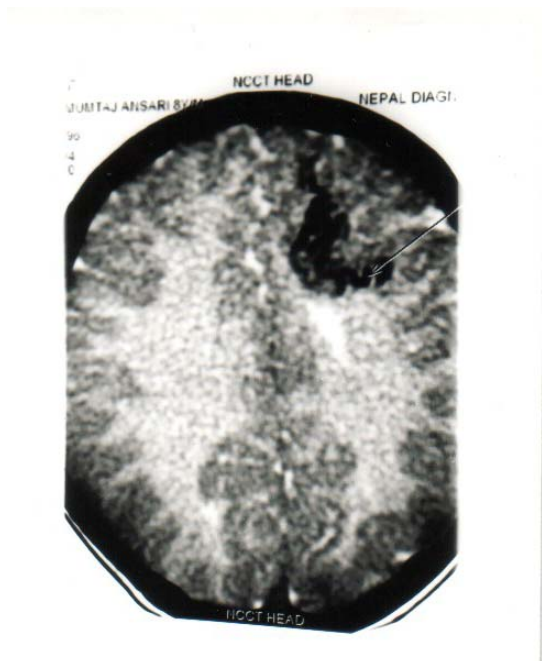
Most apparent symptom is a facial birthmark that is port-wine stain, which is present at birth and usually located on the upper face along ophthalmic branch of trigeminal nerve. Port-wine stain at lower face along mandibular branch of trigeminal nerve may occur but not so common. Glaucoma and epilepsy are present only if port-wine stain affects ophthalmic division of trigeminal nerve (upper face)⁹. Calcification in damaged cortical layer may become visible in X-ray skull and C.T. scan of brain. They are often curvilinear and rail road track pattern on ipsilateral to port-wine stain. Usual site of calcification is occipital and posterior

parietal lobes. But it can also affect other cortical regions and both cerebral hemispheres¹⁰.

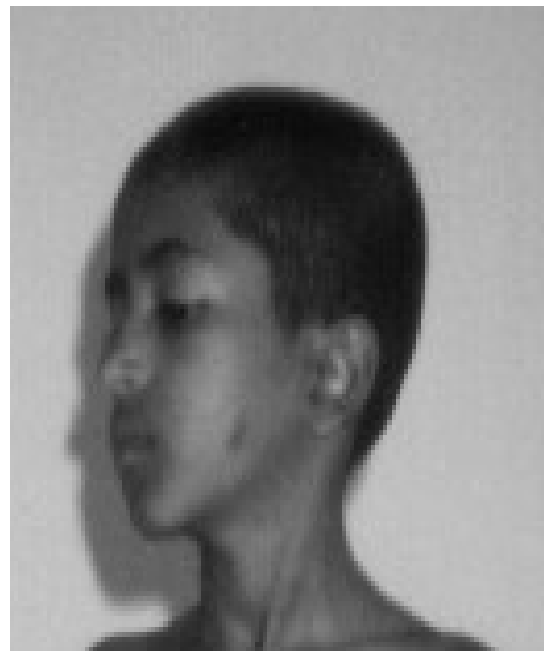
The clinical manifestations of cortical injury include hemi-paresis on opposite side of nevus, mental retardation and convulsion².

In our case, there was hemi-paresis of right half of the body since birth and port-wine stain on left lower face. C.T. scan showed calcification on frontal lobe. There was no glaucoma and no h/o convulsion. This type of presentation of SWS is very rare and only reported by Bioxeda et al in 1993⁸.

Conclusion Any child who is having facial nevus, hemiparesis, with or without seizure and glaucoma should make suspicion of Sturge Weber syndrome. X-ray skull and C.T. scan of brain should be done for confirmation of diagnosis



Photograph 2 – C.T. Scan of brain showing curvilinear calcification with focal atrophy.



Photograph 3 – Showing deep purple nevus on left side of face.

Reference

1. Rober H.A. Haslam sturge – Weber disease. In Nelson's Textbook of pediatrics (Eds Behrman RE, Kliegman Rm, Arvin AM) W.B. Saunders company, Philadelphia – 19. Eds – 17, 2004. 2017 – 2019.
2. Kristin A. Thomas – Sohl et al; sturge – Weber Syndrome. Pediatric Neurology – Vol. – 30, No.-5, 303 – 309.
3. Rivello JJ sturge – Weber syndrome. Emedicine. (Serial out line) 2001 Oct (cited 2002 Oct II); 1(1) [47 screens]
4. Bolt shauser E, Wilson J, Hoare R.D. Sturge – Weber syndrome with bilateral intracranial calcification. J neurol Neurosurg psychiatry 1976; 39; 429-35.
5. Bebin EM, Gomez MR. Prognosis in sturge – Weber disease; Comparison of unihemispheric and behemispheric involvement. J child Neurol 1988; 3; 181-4.
6. Maria BL, Neufeld BS, Rosainz LC, et al. High prevalence of bihemispheric structural and functional defects in sturge – weber syndrome J child neurol 1998;13;595 – 605.
7. Griffiths PD. Sturge – Weber syndrome revisited; The role of neuroradiology, Neuro pediatrics 1996; 27;284 – 94.
8. Bioxeda P, de Mesa RF, Arrazola JM. [Facial angioma and the sturge – Weber syndrome Likelihood a study of 121 Cases] Med clin (Barc) 1993 May 29, 101 (1); 1 – 4.
9. Tallmans B, Tan OT, Morelli JG, et al. Location of port wire stain and Likelihood of ophthalmic and / or central nervous system complications. Pediatrics 1991; 87; 323 – 7.
10. Maria BL Haong KBN, Robertson RL, Barnes PD, Drane WE, chugani HT. Imaging brain spucture and function in sturge – Weber syndrome. In bodensteiner JB, Roach ES, Eds. Sturge – Weber syndrome. Mount freedom, NJ; The sturge – Weber foundation, 1994; 43 – 69