

Huge Lipoma of Left Parotid Region with Intra-Parotid Extension

Amatya N, KC AK, Shrestha BL, Shrestha KS

Department of Otorhinolaryngology and Head and Neck Surgery

Kathmandu University School of Medical Sciences,

Dhulikhel, Kavre, Nepal.

Corresponding Author

Neha Amatya

Department of Otorhinolaryngology and Head and Neck Surgery

Kathmandu University School of Medical Sciences,

Dhulikhel, Kavre, Nepal.

E-mail: dr.nehaamatya@gmail.com

Citation

Amatya N, KCAK, Shrestha BL, Shrestha KS. Huge Lipoma of Left Parotid Region with Intra-Parotid Extension. *Kathmandu Univ Med J.* 2023;81(1):103-5.

INTRODUCTION

Lipoma is a benign mesenchymal tumor originating from adipose tissue cells which usually occurs in the abdomen, back, and shoulder, but can arise in any location where fat is normally present.^{1,2} The occurrence of this tumor in head and neck is less frequent and its involvement has ranged between 15 to 20%. Rarely they can arise in the oral cavity, pharynx, larynx, and parotid gland. They only accounts for 0.6 to 4% of neoplasm in the parotid gland therefore they are not often considered in the differential diagnosis of parotid tumors.³⁻⁵

These can occur both in the deep and the superficial lobe of the parotid.^{3,6} The most favored age group is from the fifth to sixth decade of life and is 10 times more common in the males.¹ Most lipomas grow slowly, painlessly and asymptotically, and they may affect surrounding structures. Due to the rarity of lipoma in the parotid gland regions, an accurate diagnostic method is required to make a conclusive diagnosis. A more accurate diagnosis of these tumors have been made possible by improved preoperative evaluation tools including magnetic resonance imaging (MRI) and fine needle aspiration

ABSTRACT

Lipoma is a benign mesenchymal tumor originating from adipose tissue. The occurrence of this tumor in head and neck is less frequent and it rarely involves parotid gland. These are asymptomatic and occur both in the deep and the superficial lobe of the parotid. The most favored age group is from the fifth to sixth decade of life and is 10 times more common in the males.

A 66-year-old male patient, with left parotid region lipoma is reported in this article. A fine-needle aspiration biopsy and ultrasonography were performed to establish the preoperative diagnosis and to plan the correct surgical approach. It was managed by surgical excision of lipoma with removal of cuff of superficial parotid tissue on superior aspect with preserving facial nerve. Follow-up examinations were planned to assess any facial nerve injury complications.

KEY WORDS

Adipose tissue, Lipoma, Parotid gland, Superficial lobe

biopsy (FNAB).^{3,7,8} A surgical procedure of these tumors is challenging because of the anatomical barrier where facial nerves cross throughout the parotid gland, thus increasing the risk of nerve injury and damage during surgery. A well-established surgical technique, special precautions, and attention to anatomical structures around the surgical area, as well as follow-up after surgery, are important to reduce and manage those risks. This case report presents the diagnostic method and surgical approach of a rare case of head and neck region lipoma in the parotid region.⁹

CASE REPORT

A 66 years old male presented to Dhulikhel Hospital ENT OPD with a history of noticing a swelling on the left lateral neck since 13 years. Onset was insidious and gradually progressive over the years. Initially, it was the size of a walnut and over the year it has increased to its present size as that of a squash (Fig. 1). It was painless. On examination, there was a 14x5x3 cm swelling on left parotid region extending to up to 4 cm below angle of mandible in the

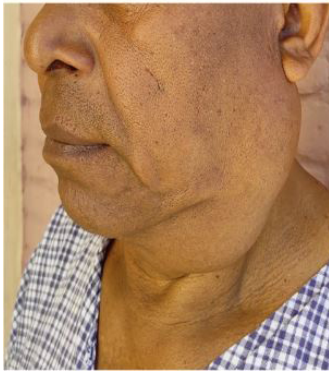

Figure 1. Clinical photograph showing the lipoma of left parotid gland.

midline. The skin overlying the swelling was normal. It was soft, mobile, and non-tender on palpation. It had a smooth and regular surface without central punctum. It was not adherent to the skin but was adherent to the underlying structure on the superior aspect. Neck examination revealed no cervical lymphadenopathy. His facial nerve was fully intact. A provisional diagnosis of lipoma or mixed tumor of parotid gland was made (Fig. 1). Ultrasonography revealed subtle ill-defined isoechoic lesion 149x46 mm in left lateral neck involving left submandibular region with infra-auricular region displacing the submandibular gland inferomedial and abutting the parotid gland above. There was no evidence of increased vascularity or calcification and was suggestive of intramuscular lipoma. The FNAB report revealed a distribution of epithelial cells with round-oval nuclei, fine chromatin, broad cytoplasm, and eosinophilic color with the background consisting of a distribution of erythrocyte cells, a few inflammatory lymphocyte cells, and fat droplets. The report showed no malignant cells and was suspected that the swelling was a benign lipomatous lesion.

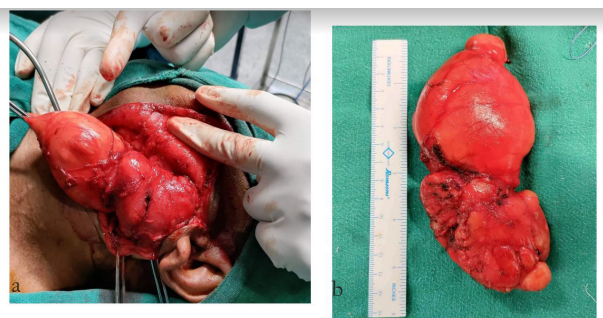


Figure 1 a. Intraoperative photograph of excision of lipoma of left parotid gland, **b.** Photograph of Excised lipoma of left parotid gland.

Under general anesthesia using a classic Blair's incision, excision of lipoma removal cuff of parotid tissue on superior aspect with preserving facial nerve was performed. The distal tumor extending deep to the superficial parotid gland was excised. The mass was removed while the facial nerve was preserved. The specimen was a single soft, yellowish, well-circumscribed encapsulated mass, measuring 14X5X2 cm (Fig. 2b). Histological sections showed partly

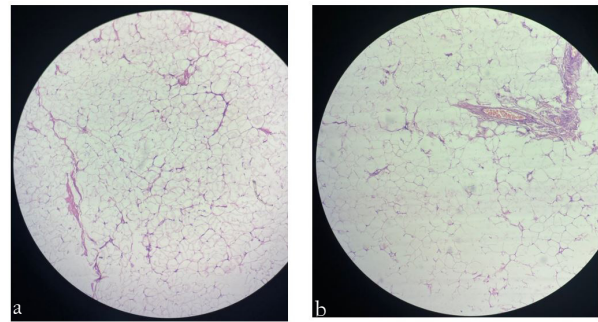


Figure 3 a. Photomicrograph showing sheets of lobules of adipocytes with individual cells have eccentrically pushed nuclei and abundant vacuolated cytoplasm, **b.** suggestive of a lipoma.

encapsulated tissue comprising of sheets of lobules of adipocytes. individual cells had eccentrically pushed nuclei and abundant vacuolated cytoplasm. Few blood vessels and area of hemorrhage. No atypia were seen and features were consistent with that of a lipoma. A final diagnosis of parotid gland lipoma was obtained based on the preceding microscopic characteristics.

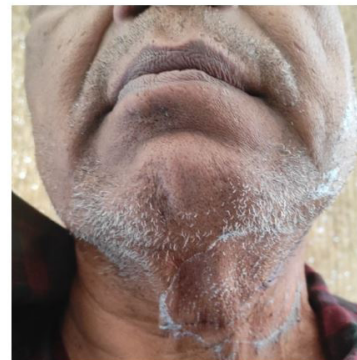

Figure 4. Post Operative photograph after excision the lipoma of left parotid gland.

During the hospital stay, the patient was given antibiotics to prevent postoperative infection, nonsteroidal anti-inflammatory drugs, and corticosteroid to reduce postoperative inflammation. The patient was discharged 7 days after the operation with a good prognosis assessment. Facial nerve function was checked clinically by asking the patient to wrinkle the forehead to observe any asymmetry, close the eyes tightly to observe lid closure competence, smile to observe asymmetry of the nasolabial fold, and contract the mouth to observe orbicularis oris functions. There was no facial nerve dysfunction found during the examination. Follow-ups were planned in 3 months, 6 months, 1 year, and 2 years after the operation to observe any disease recurrence and facial nerve functions.

DISCUSSION

The occurrence of an parotid lipoma is a rare entity. The solitary, ordinary lipoma, which is composed of mature fat, has evoked relatively little interest in the literature and only a few parotid lipoma have been reported. This is not entirely surprising when one considers that most grow insidiously and cause few symptoms other than the

effects of localized mass.^{4,10} Of the variety of lipomatous benign tumors that occur, over 80% are ordinary lipomas and about 13% of them occur in the head and neck, most commonly in the posterior neck. Rarely, lipomas can occur in the anterior neck, infratemporal fossa, oral cavity, pharynx, larynx, and parotid gland.¹⁰

Lipomas are rare in the first two decades of life, usually developing in the fifth and sixth decades when fat begins to accumulate in inactive, underexercised individuals.^{4,5} In general, the tumor is more common in obese people and can increase in size during a period of rapid weight gain; however, after the initial growth period most lipomas increase little in size. Numerous etiological factors were explored, such as inherited factors, trauma, diabetes, endocrine problems, corticosteroids, obesity, and radiation.^{10,12}

Due to the rarity and the low clinical suspicion index of lipomas, the clinical diagnoses are typically challenging and the procedure performed must be precise to establish a definitive diagnosis. Hence, a diagnosis of the parotid lipoma is challenging, and an FNAB accompanied by an MRI

determines its diagnosis preoperatively. In this case, an FNAB and USG were performed to establish a preoperative diagnosis and to plan the best surgical approach.⁹

An essential diagnostic technique for identifying parotid tumors is a FNAB. However, its accuracy is only approximately 50% in most parotid tumor cases.⁸ An FNAB of a lipoma is often reported other hand, an FNAB is highly accurate for the diagnosis of lipomatous tumors, with 96% accuracy for lipomas.⁷

Different surgical methods are used based on the topography, tumor size, pathology, and relationship to the surrounding areas. In the case of para-pharyngeal extension, a near complete parotidectomy is performed in addition to a superficial parotidectomy, extracapsular dissection, partial excision of the inferior part of the parotid gland, and superficial parotidectomy.^{3,13}

In this case, excision of the lipoma was performed along with removal of cuff of superficial parotid tissue on superior aspect with appropriate facial nerve dissection so that the entire lipoma could be excised without injuring the facial nerve.

REFERENCES

- Weiss SW, Goldblum JR. Chapter 16: "Benign Lipomatous Tumors". Enzinger and Weiss's soft tissue tumors, 4th ed. Mosby, St Louis. 2001;571.
- Baykul T, Aydın MA, Findik Y, Yildirim D. Huge lipoma of the right parotid gland: Case report and review of 42 cases. *Ear Nose Throat J*. 2016 Jan;95(1):E8-E13
- Mesolella M, Ricciardiello F, Oliva F, Abate T, di Lullo AM, Marino A. Parotid lipoma: a case report. *Case Rep Clin Med*. 2014;3(07): 437-42.
- Enzinger FM, Weiss SW. Soft tissue tumors. St. Louis: Mosby, 1983:199-241.
- Barnes L. Surgical pathology of the head and neck, Vol. 1. New York: Dekker, 1985:747-58.
- Siu Ngee CY, Kong MH, Mawaddah A, Tan GC, Affandi KA. Lipoma of the parotid gland. *Egypt J Ear Nose Throat Allied Sci*. 2019;20 (01):23-6.
- Houle A, Mandel L. Diagnosing the parotid lipoma: case report. *NY state Dent J*. 2015;81:48-50.
- Raju D, Srikanth G, Rashmitha A, Kistareddy S. A rare case of parotid gland lipoma arising from the superficial lobe of the parotid gland. *J Indian Acad Oral Med Radiol*. 2020;32(02):186-8.
- Paparo F, Massarelli M, Giuliani G. A rare case of parotid gland lipoma arising from the deep lobe of the parotid gland. *Ann Maxillofac Surg*. 2016;6(02):308-10.
- Som PM, Scherl MP, Rao VM, Biller HF. Rare presentations of ordinary lipomas of the head and neck: A review. *AJNR Am J Neuroradiol*. 1986;7(4):657-64.
- Batsakis JG. Tumors of the head and neck, clinical and pathological considerations, 2nd ed. Baltimore: Williams & Wilkins, 1979:360-64.
- Layfield LJ, Glasgow BJ, Goldstein N, Lufkin R. Lipomatous lesions of the parotid gland. Potential pitfalls in fine needle aspiration biopsy diagnosis. *Acta Cytol*. 1991 Sep-Oct;35(5):553-6. PMID: 1927198.
- El-Monem MH, Gaafar AH, Magdy EA. Lipomas of the head and neck: presentation variability and diagnostic work-up. *J Laryngol Otol*. 2006;120(01):47-55.