

# Capillary Haemangioma of Gingiva - A Rare Lesion

Manohar B,<sup>1</sup> Meena V,<sup>2</sup> Metgud R,<sup>3</sup> Bhuvaneshwari S,<sup>4</sup> Humagain M<sup>5</sup>

<sup>1</sup>Department of Periodontology,  
Kalinga Institute of Dental Sciences,  
KIIT Deemed to be University, Patia, Bhubaneswar,  
Odisha 751024, India.

<sup>2</sup>Periodontist Dental Speciality Centre,  
Trauma and Gum Care Clinic,  
Udaipur 313001, India.

<sup>3</sup>Department of Oral and Maxillo-facial Pathology,  
Pacific Dental College and Hospital,  
Debari, Udaipur 313024, India.

<sup>4</sup>Department of Oral Medicine and Radiology,  
Kalinga Institute of Dental Sciences,  
KIIT Deemed to be University, Patia, Bhubaneswar,  
Odisha 751024, India.

<sup>5</sup>Department of Periodontology and Oral Implantology,  
Kathmandu University School of Medical Sciences,  
Dhulikhel, Kavre, Nepal.

## Corresponding Author

Balaji Manohar

Department of Periodontology

Kalinga Institute of Dental Sciences, Patia,  
Bhubaneswar, Odisha 751024, India.

E-mail: manohar\_balaji@hotmail.com

## Citation

Manohar B, Meena V, Metgud R, Bhuvaneshwari S, Humagain M. Capillary Haemangioma of Gingiva - A Rare Lesion. *Kathmandu Univ Med J.* 2023;81(1):94-7.

## INTRODUCTION

Haemangioma was first described by Liston in 1843.<sup>1</sup> Classification of haemangioma has been described based on the type of blood vessels involved, whether they are capillary, juvenile, cavernous, and arteriovenous hemangioma.<sup>2</sup> Haemangioma is a clinically benign vascular lesion that is characterized by rapid proliferation of endothelial cells which precedes involution. The capillary haemangioma has innumerable small thin-walled vessels that are filled with blood and are proliferating; having a layer of endothelial cells that may be plump or flat surrounded by pericytes and reticular fibres that are discontinuous.

Capillary haemangioma present a proliferative phase as well as an involution phase, which is very distinctive.<sup>3</sup> Haemangiomas are soft tissue mass which may be smooth or lobulated, sessile or pedunculated of varying size.

## ABSTRACT

Capillary Haemangioma is a benign vascular tumour characterized by proliferation of blood vessels with a very striking similarity to pyogenic granuloma with a predilection to occur on the gingiva. Though the head and neck are the most common region of occurrence, but is considered to be rare occurring on the gingiva, intra-orally. The lesion clinically mimicked pyogenic granuloma but was histopathologically diagnosed as capillary haemangioma. It was surgically excised and followed up for 6 months without any recurrence.

## KEY WORDS

*Capillary haemangioma, Hamartoma, Haemangioma, Pyogenic granuloma, Telangiectasis*

Though, capillary haemangioma is described as a soft tissue tumor common to the of head and neck, but, is a rarely seen in the oral cavity.<sup>4</sup> And within the oral cavity, it occurring on the gingiva is extremely rare. It appears to grow from the interdental gingiva spreading laterally to involving the neighbouring tissues.<sup>5</sup> The aim of this paper is to report a rare case of gingival growth arising in the maxillary anterior region in a female patient with an emphasis on the diagnostic features and its management.

## CASE REPORT

A female patient aged 32 years, complained of a solitary swelling in the upper right front tooth region. It gradually increased in size and the patient had difficulty in mastication

and oral hygiene maintenance. There was no relevant medical history. Intraorally, a solitary, sessile, reddish enlargement having distinct borders and smooth surface was seen. The lesion measured approximately 3x2 cm and was on the labial surface of 11 and extended distobuccally to 14 (Fig. 1). The enlargement was soft and tender. The patient exhibited poor oral hygiene. Based on the clinical appearance a provisional diagnosis of pyogenic granuloma was made. Peripheral ossifying fibroma, peripheral giant cell granuloma, haemangioma and fibroma were considered as differential diagnosis.

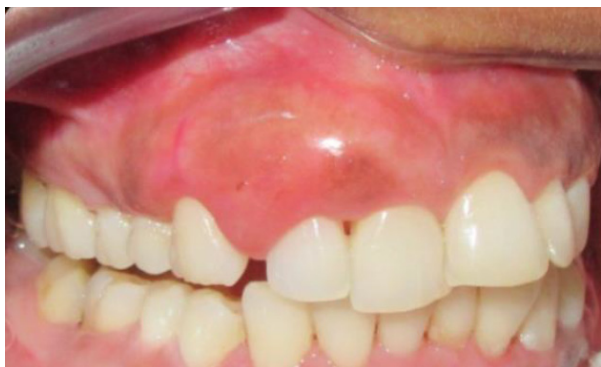

Figure 1. Preoperative view of the lesion

After obtaining a written consent, phase I therapy was instituted to the patient including instructions for maintenance of oral hygiene. After 1 week of phase I therapy, excision of the enlargement along with the surrounding gingival tissue was performed (Fig. 2). Thorough curettage was performed and haemostasis was achieved by application of pressure pack (Fig. 3). A non-eugenol based periodontal dressing was placed directly over the surgical site (Fig. 4) and postoperative instructions were given. A non-steroidal anti inflammatory analgesic (Diclofenac sodium 50 mg 2 times a day for 5 days) was prescribed to the patient for pain relief. The excised tissue was sent for histopathology (Fig. 5). The patient was recalled after 1 week post-operatively for removal of the pack and evaluation. The region showed satisfactory and uneventful healing after 1 month post-operatively (Fig. 6). The patient was followed up for over 6 months and there was no recurrence observed (Fig. 7).

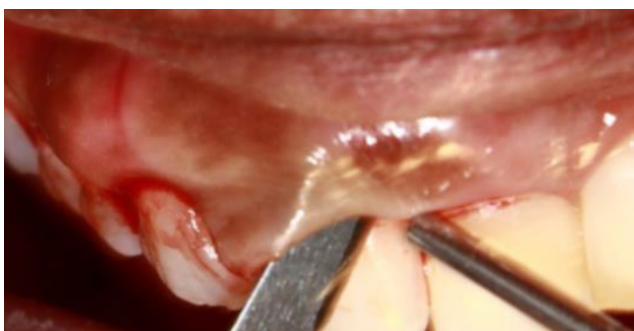

Figure 2. Surgical excision

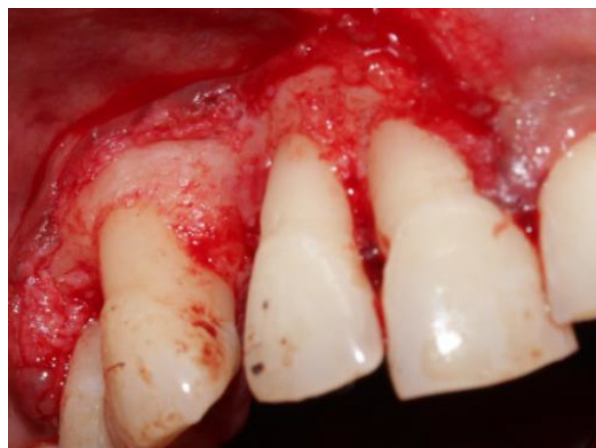

Figure 3. Immediate Postoperative view

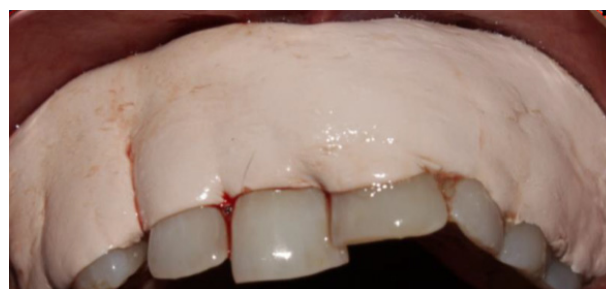

Figure 4. Placement of periodontal pack

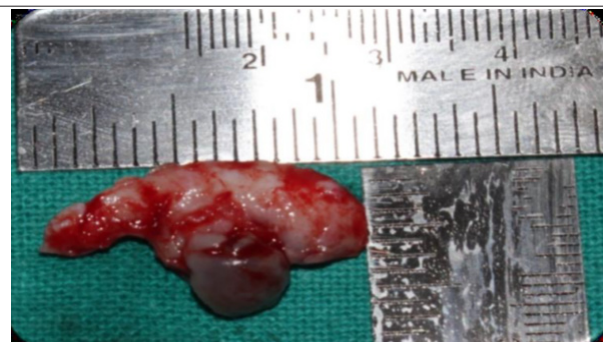


Figure 5. Tissue after surgical excision

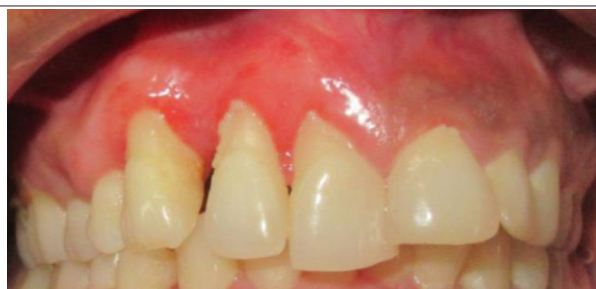

Figure 6. 1 month Postoperative view

Histopathology of the lesion in low power (100x) exhibited a nodular mass of tissue covered by hyperplastic stratified squamous epithelium overlying the connective tissue stroma, proliferating capillaries showing spongiosis. Connective tissue reveals numerous irregular and dilated endothelial lined vascular spaces. In high power (400x), a mass of fibrous tissue with several thin-walled blood vessels

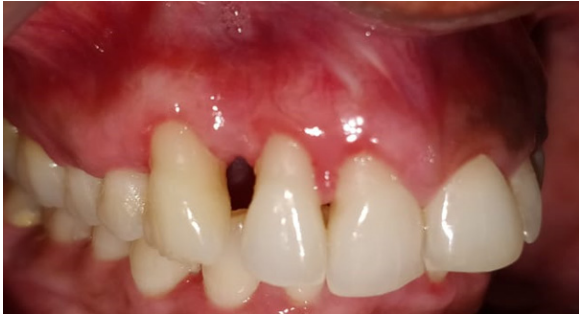

Figure 7. 6 month postoperative view

that were placed perpendicular to the epithelial surface were observed. Stroma revealed numerous irregular and dilated blood filled endothelial lined vascular channels of varying sizes and shapes, collagen fibres interspersed with fibroblasts and chronic inflammatory infiltrate. The overall features were suggestive of Capillary Haemangioma (Fig. 8 a,b).

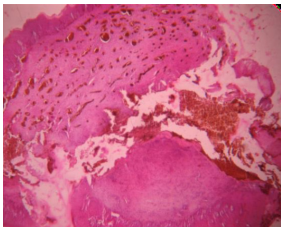


Figure 8a. H&E stain under low power magnification

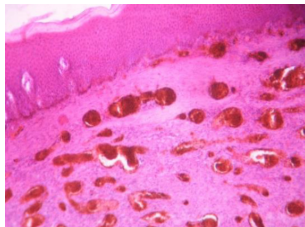


Figure 8b. H&E stain under high power magnification

## DISCUSSION

Haemangiomas though are vascular tumours are benign in nature. They can be histologically classified as capillary and cavernous type.<sup>6</sup> Capillary haemangiomas comprise of innumerable small capillaries that are lined by endothelial cells supported in the connective tissue stroma and depicts a growth phase that is very rapid and is followed by a slow involution.<sup>7-9</sup> The intraoral incidence of capillary haemangioma is extremely rare.<sup>10</sup> It varies from 0.5-1.0% of all intraoral neoplasms, especially with a 3:1 female predilection occurring in the second and third decades of

life.<sup>9,11,12</sup> The case reported here also is seen in a female patient in her early 4<sup>th</sup> decade of life. Matsumoto et al., in 31 cases of intra oral capillary haemangioma reported buccal mucosa (45.2%) as the most common region of occurrence. The tongue (35.5%), lip (9.7%), gingiva (6.5%), and the palate (3.2%) were the other areas where it occurred.<sup>12</sup> Haemangiomas, clinically, radiographically and histologically mimic other conditions which adds to the confusion. Intraoral haemangiomas are painless, soft, smooth or lobulated, sessile or pedunculated mass. The size is seen to be varying from a few millimetres to several centimetres.

The lesion in the periodontal region are painless and often arises in the interdental region and involves the adjacent tooth laterally.

The haemangiomas are classified based completely on the histological appearance. The histopathology is the most accurate method for diagnosis. As the clinical features of capillary haemangioma is very similar to pyogenic granuloma, biopsy and histopathology is a must for correct diagnosis.<sup>13</sup>

The treatment varies based on factors like the patient's age, the size and site of involvement, as well as the clinical nature of the haemangioma.<sup>14</sup> Surgical excision with or without ligation of vessels and embolization is the treatment of choice.<sup>15</sup> Newer treatment modalities include steroid therapy, electrosurgery, laser therapy and cryosurgery.

Surgical management is always executed with caution as the intra-operative and post-operative bleeding is always anticipated because of the vascular abnormality due to the aggregation and proliferation of the blood vessels.<sup>16</sup>

Capillary haemangioma clinically mimics pyogenic granuloma and often presents as a dilemma and is diagnosed based on the histological findings to facilitate proper management and prevent intra-operative and post operative complications. There is always an associated risk of recurrence of capillary haemangioma which necessitates follow up for a longer duration of time.

## REFERENCES

- Nandaprasad S, Sharada P, Vidya M, Karkera B, Hemanth M, Kage C. Hemangioma- a review. *Internet J Hematol*. 2008;16(2).
- da Silva WB, Ribeiro AL, de Menezes SA, de Jesus Viana Pinheiro J, de Melo Alves-Junior S. Oral capillary hemangioma: a clinical protocol of diagnosis and treatment in adults. *Oral Maxillofac Surg*. 2014 Dec;18(4):431-7. doi: 10.1007/s10006-013-0436-z. Epub 2013 Nov 22. PMID: 24263242.
- Mulliken JB, Glowacki J. Hemangiomas and vascular malformations in infants and children: A classification based on endothelial characteristics. *Plast Reconstr Surg*. 1982;63:412-22.
- Warner M, Suen JY, Dinehart S. Treatment of hemangiomas of the head and neck. *Laryngoscope*. 1992;102:1123-32.
- Carranza FA. Glickman's clinical periodontology. 1<sup>st</sup> ed. Philadelphia: WB Saunders Co.; 1990. p. 335-51.
- Mills SE, Cooper PH, Fechner RE. Lobular capillary hemangioma: The underlying lesion of pyogenic granuloma. A study of 73 cases from the oral and nasal mucous membrane. *Am J Surg Pathol*. 1980;4:470-9.
- Bayrak S, Dalci K, Tansel H. Capillary hemangioma of the palatal mucosa: Report of an unusual case. *SÜ Dishek Fak Derg*. 2010;19:87-9.
- Chen YK, Lin LM, Huang HC, Lin CC, Yan YH. A retrospective study of oral and maxillofacial biopsy lesions in a pediatric population from southern Taiwan. *Pediatr Dent*. 1998;20:404-10.
- Neville BW, Damm DD, Allen CM, Bouquet JE. Oral & Maxillofacial Pathology. Saunders Philadelphia, 2<sup>nd</sup> Ed, 2002;390-2.
- Dahlin DC, Unni KK. Bone tumours: General aspects and data on 542 cases. *Springfield Ill*. 1986;14:3-17.

11. Yih WY, Ma GS, Merrill RG, Sperry DW. Central hemangioma of the jaws. *J Oral Maxillofac Surg.* 1989;47:1154-60.
12. Matsumoto N, Tsuchiya M, Nomoto S, Matsue Y, Nishikawa Y, Takamura T, et al. CD105 expression in oral capillary hemangiomas and cavernous hemangiomas. *J Oral Sci.* 2015;57:45-53.
13. Vasantha Kumari VR, Vallabhan CG, Geetha S, Nair MS, Jacob TV. Atypical presentation of capillary hemangioma in Oral Cavity- A Case Report. *J Clin Diagn Res.* 2015;9:ZD26-ZD28
14. Rachappa MM, Triveni MN. Capillary hemangioma or pyogenic granuloma: A diagnostic dilemma. *Contemp Clin Dent.* 2010;12:119-22.
15. Açıkgöz A, Sakallıoğlu U, Ozdamar S, Uysal A. Rare benign tumours of oral cavity: Capillary hemangioma of palatal mucosa: A case report. *Int J Paediatr Dent.* 2000;10: 161-5.
16. Sharma SR, Mehra A, Karjodkar FR, Sansare KP. Atypical extra gingival occurrence of lobular capillary hemangioma: A report of two cases. *J Indian Soc Periodontol.* 2021;25:254-7.