

Simple Oncoplastic Breast Conserving Surgery for Breast Cancer in a University Hospital

Khanal S,¹ Singh N,² Singh YP³

¹Department of Surgical Oncology,
BP Koirala Memorial Cancer Hospital,
Bharatpur, Chitwan, Nepal.

²Cancer Research Associate,
Nepal Cancer Education Foundation, Tokha-4,
Dhapasi, Kathmandu, Nepal.

³Department of Surgery (Surgical Oncology),
Tribhuvan University Teaching Hospital,
Kathmandu, Nepal.

Corresponding Author

Suman Khanal

Department of Surgical Oncology,
BP Koirala Memorial Cancer Hospital,
Bharatpur, Chitwan, Nepal.

E-mail: suman81765@gmail.com

Citation

Khanal S, Singh N, Singh YP. Simple Oncoplastic Breast Conserving Surgery for Breast Cancer in a University Hospital. *Kathmandu Univ Med J.* 2023;83(3):250-3.

ABSTRACT

Background

The principle of oncoplastic surgery is the removal of tumors with negative margins as well as maintaining the contour of the breast. The goals are to achieve local control and best cosmesis.

Objective

The objective of this study was to assess patients' satisfaction with different techniques of simple oncoplastic breast conserving surgery (BCS) for early breast cancer.

Method

This was a retrospective study of early breast cancer cases operated during the period 2009 to 2017. All the patients were under regular follow up for at least five years after surgery. Original Harvard/NSABP/RTOG scale was used to evaluate cosmesis at one year after surgery.

Result

Median age of the patients was 43 years with median size of tumor being 2.5 cm. All of the patients had good to excellent cosmetic outcome. One patient (4.5%) had margin positivity. All patients were disease free and happy with the cosmesis at five years although one patient did not have whole breast radiotherapy.

Conclusion

Simple oncoplastic breast conserving surgery techniques in upper part of breast are simple, feasible and improve cosmetic outcome with low margin positivity and good disease-free five-year survival.

KEY WORDS

Breast cancer, Breast conserving surgery, Mammoplasty

INTRODUCTION

Since Halstead reported radical mastectomy in 1894, surgery for breast cancer has undergone de-escalation in its radicality, thanks to many landmark trials.¹⁻⁴ It is now established that BCS in eligible patients is as effective as mastectomy in terms of local tumor control, recurrence free survival (RFS) and overall survival.^{5,6} Paradoxically, a large cohort study even showed survival benefit compared to mastectomy in T1-2N0-2.⁷

As the oncological outcome has improved significantly with increased survival, when a woman is diagnosed with breast cancer today, her concern is not only to get rid of the disease but also about physical, emotional, and sexual concerns. So, every effort is made to preserve breast with breast conserving surgery (BCS). Breast conservation is associated with improved self-esteem, quality of life, body image and reduced psychological morbidity.⁸ However, BCS is highly underutilized in Nepal maybe because of limited access to radiotherapy, neoadjuvant chemotherapy, or the patient's desire to remove the breast in order to minimize the risk of local recurrence.⁹ The role of surgeon is thus important in allaying fear of patients by debunking the belief of inferiority of BCS compared to mastectomy, and maintaining the potential of cosmesis as far as possible.

However, BCS is associated with unsatisfactory cosmetic outcome in up to 40% of cases.^{10,11} To overcome unsatisfactory results of the BCS, oncoplastic surgery is being increasingly used.¹² Oncoplastic surgery enables generous excision of tumors with low margin positivity and improved aesthetic outcome. Simple oncoplastic BCS are level I techniques and can be done by the general surgeon or breast surgeon even in low-volume centers.¹³

METHODS

This study is a retrospective analysis of all 22 early breast cancer patients operated during the period of 2009 to 2017. These patients were managed with simple oncoplastic BCS at the Breast Unit of Tribhuvan University Teaching Hospital (TUTH), Kathmandu. Ethical approval was taken from Institutional Review Committee of TUTH. Informed consent was taken from all the patients and the data was collected in a standardized proforma.

The appropriate technique was selected according to the breast tumor location, tumor size, and size of the breast. Simple oncoplastic techniques like Radial Ellipse Segmentectomy (RES), Round Block Technique (RBT), and Batwing Technique (BT) were done. All patients underwent sentinel lymph node biopsy (SLNB) with methylene blue. Those cases which did not stain with methylene underwent axillary staging. The techniques are described in our previous reports.¹⁴⁻¹⁶ Original Harvard/NSABP/RTOG breast

cosmesis scale was used for grading the post-operative cosmetic outcome at one year, as the effects of adjuvant treatment subside, into excellent, good, fair and poor. Two surgeons independently graded the cosmetic outcome. If there was discrepancy, the lower grade was considered the final. All the patients were followed regularly for at least five years. Statistical analysis was done with R version 4.2.0.

RESULTS

The median age of the patients was 43 years (range 28 - 67 years). The median tumor size was 2.5 cm (range 1.5 - 4 cm). Tumors were equally distributed in left and right breasts. The variables under study are summarized in table 1. Sentinel lymph node positivity was seen in one patient for whom level I/II axillary lymph node dissection (ALND) was done. Two cases underwent axillary staging due to non-staining of lymph nodes, these turned out to be negative.

Table 1. Variables under study

Variable	Value
Age	28-67 years
Side	Left (11), Right (11)
Tumor site:	
UOQ	L(8), R(6)
UMQ	L(1), R(2)
UCQ	L(2), R(3)
Technique:	
UOQ	RES (14), RBT (0), BE (0)
UMQ	RES (2), RBT (0), BE (1)
UCQ	RES (1), RBT (3), BE (1)
Sentinel lymph node positivity	1
Margin positivity	1 (BT for 4 cm tumor)
Outcome:	
UOQ	Excellent (13), Good (1)
UMQ	Excellent (3)
UCQ	Excellent (4), Good (1)
Locoregional recurrence	0
5-year survival	100%

All the patients except the eldest 67-year-old received whole breast radiotherapy (WBRT). She denied WBRT, so was put on Tamoxifen only. 77% (17/22) cases underwent RES. All cases with tumors in UOQ were managed with RES. RBT was used exclusively to manage tumors in UCQ. All cases had excellent outcome except two cases who had good outcome: one RES done for UOQ and one RBT done for UCQ tumor (Fig. 1 (A and B) and 2). There was margin positivity seen in a case who underwent BT for 4 cm tumor, for which re-excision was required. Nipple sensation was preserved in all cases. All cases were satisfied with their cosmesis and were disease free at five years.

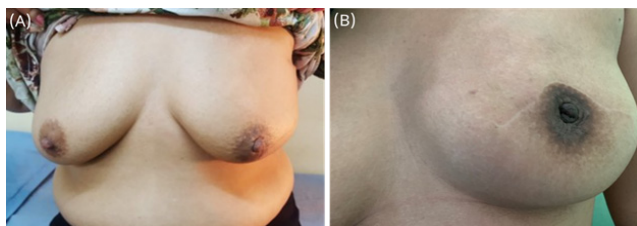


Figure 1. (A) Radial ellipse segmentectomy with excellent outcome (B) Batwing technique with excellent outcome

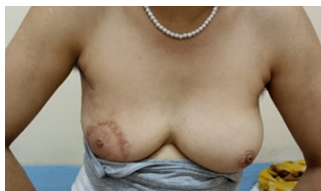

Figure 2. RBT with good cosmetic outcome

DISCUSSION

The majority of cases (14/22, 63.6%) had tumors in upper outer quadrant (UOQ) and half of these were more than 50 years of age. All these cases were managed by radial ellipse segmentectomy with sentinel lymph node biopsy. All had excellent outcome except the one who was the eldest (67 years) in UOQ cohort. After UOQ, second most common site was upper central quadrant (UCQ) similar to a study in Egypt.¹⁷ Although RES can be performed for any location within breast, its utility in UOQ lies in its ability to do sentinel lymph node biopsy from same incision which was indeed the case in this study.^{14,18}

Three of five cases with tumors in upper central quadrant underwent RBT or donut mastopexy for lesion removal while each of the rest underwent RES and BT. All cases had excellent outcome except for one with RBT. RBT gives consistent good results regardless of tumor location, nipple tumor distance for tumors with maximum tumor volume below 79.2 ml.¹⁹ One case had only good outcome despite tumor volume below this threshold. While shape and mound of breast was well maintained, there was scar expansion. In a good series of RBT, 52% had excellent outcome while it was 66.7% (2/3) in our study.²⁰ Our patients who underwent RBT were younger than the patients in the study by Mohsen et al. although the tumor size was similar (2-3 cm). RBT shows best results in small to medium sized breasts without major ptosis.²⁰ De-epithelialisation only between two rings and incision over tumor helps preserve sensation of nipple areola complex.²¹ In our case all who had undergone RBT had preserved nipple sensation possibly due to location of tumors in UCQ.

The tumors in upper medial quadrant were managed by RES and batwing technique (BT). This area despite being cosmetically susceptible to excision > 5-10%, we obtained excellent results.²² Care should be taken to hide the scar under the bra.¹⁸ The Batwing technique is a simple volume displacement technique used to remove tumors in upper part of breast superomedial or superolateral to nipple areola complex.^{18,23} The tumor was 3.5 cm in our case in BT. However even tumors sized 15 cm have been removed with good cosmetic outcome.¹⁶

While application of radio-opaque markers are indicated for facilitating radiation planning such markers were not applied in our case.¹⁸ All patients received WBRT. The relative risk of ipsilateral recurrence is three times in BCS who avoid radiotherapy.²⁴ While five year local recurrence in oncoplastic surgery ranges from 1-2.2%, none of our cases had recurrence.^{25,26} It was the case despite the fact that a patient had refused WBRT and only taken Tamoxifen. Specimen margin involvement in oncoplastic surgery can be seen in 10.5-20.9% of invasive breast cancers.²⁶ Only one patient (1/22, 4.5%) in our study who underwent BT for 4 cm tumor had margin positivity, requiring re-excision.

Simple oncoplastic techniques are those which involve tumor resection with volume displacement techniques that doesn't involve pedicle based reduction mammoplasty.^{13,27} RES, RBT, BT are simple techniques relatively easy to perform as it involves glandular tissue mobilization and rearrangement. Addition of radiotherapy in standard BCS can lead to deformity later but tissue rearrangement and obliteration of dead space in simple oncoplasty help prevent delayed deformity.¹⁰ 90.9% of our early breast cancer cases had excellent cosmetic outcome.

Our study is significant in that it is the first study to the best of our knowledge, to report the earliest use of oncoplasty in Nepal from 2009 and its outcome. Though the use of oncoplastic surgery is increasing, it is still underutilized in Nepal.¹⁴⁻¹⁶ In a prominent tertiary cancer center in 2018 with high volume cases, 99% of breast cancer cases were only mastectomies.⁹

Being a single center study with limited number of samples, more studies are needed to generalize the findings.

CONCLUSION

Simple oncoplastic breast conserving surgeries in upper part of breast are oncologically safe with good cosmetic outcome in early breast cancer.

REFERENCES

1. Bland CS. The Halsted Mastectomy: Present Illness and Past History. *West J Med.* 1981 Jun;134(6):549-55.
2. Litière S, Werutsky G, Fentiman IS, Rutgers E, Christiaens MR, Van Limbergen E, et al. Breast conserving therapy versus mastectomy for stage I–II breast cancer: 20 year follow-up of the EORTC 10801 phase 3 randomised trial. *Lancet Oncol.* 2012 Apr 1;13(4):412-9.
3. Fisher B, Anderson S, Bryant J, Margolese RG, Deutsch M, Fisher ER, et al. Twenty-year follow-up of a randomized trial comparing total mastectomy, lumpectomy, and lumpectomy plus irradiation for the treatment of invasive breast cancer. *N Engl J Med.* 2002 Oct 17;347(16):1233-41.
4. Fisher B, Dignam J, Wolmark N, Mamounas E, Costantino J, Poller W, et al. Lumpectomy and radiation therapy for the treatment of intraductal breast cancer: findings from National Surgical Adjuvant Breast and Bowel Project B-17. *J Clin Oncol Off J Am Soc Clin Oncol.* 1998 Feb;16(2):441-52.
5. Blichert-Toft M, Nielsen M, Düring M, Møller S, Rank F, Overgaard M, et al. Long-term results of breast conserving surgery vs. mastectomy for early stage invasive breast cancer: 20-year follow-up of the Danish randomized DBCG-82TM protocol. *Acta Oncol.* 2008 Jan 1;47(4):672–81.
6. Christiansen P, Mele M, Bodilsen A, Rocco N, Zachariae R. Breast-Conserving Surgery or Mastectomy? Impact on Survival. *Ann Surg Open.* 2022 Dec;3(4):e205.
7. de Boniface J, Szulkin R, Johansson ALV. Survival After Breast Conservation vs Mastectomy Adjusted for Comorbidity and Socioeconomic Status: A Swedish National 6-Year Follow-up of 48986 Women. *JAMA Surg.* 2021 Jul 1;156(7):628-37.
8. Margolis G, Goodman RL, Rubin A. Psychological effects of breast-conserving cancer treatment and mastectomy. *Psychosomatics.* 1990;31(1):33-9.
9. BP Koirala Memorial Cancer Hospital. BPKMCH Annual Report 2018 [Internet]. 2019 [cited 2023 Feb 13]. Available from: <http://archive.org/details/bpkmch-annual-report-2018>
10. Losken A, Hamdi M. Partial breast reconstruction: current perspectives. *Plast Reconstr Surg.* 2009 Sep;124(3):722-36.
11. Catsman CJLM, Beek MA, Voogd AC, Mulder PGH, Luiten EJT. The COSMAM TRIAL a prospective cohort study of quality of life and cosmetic outcome in patients undergoing breast conserving surgery. *BMC Cancer* [Internet]. 2018 [cited 2023 Feb 11];18.
12. Hadjittofi C, Almalki H, Mirshekar-Syahkal B, Pain S, Zechmeister K, Hussien M. Simple oncoplastic breast defect closure improves long-term cosmetic outcome of breast conserving surgery for breast cancer: A randomised controlled trial. *Breast Off J Eur Soc Mastology.* 2022 Jul 18;65:104-9.
13. Clough KB, Kaufman GJ, Nos C, Buccimazza I, Sarfati IM. Improving breast cancer surgery: a classification and quadrant per quadrant atlas for oncoplastic surgery. *Ann Surg Oncol.* 2010 May;17(5):1375-91.
14. Singh YP, Khanal S. Initial Experience with Simple Oncoplastic Breast Conserving Surgery in Nepal: A Case Report. *J Inst Med Nepal.* 2020;42(2):97-9.
15. Khanal S, Singh YP, Sharma R, Pandit K. Round block technique in management of breast lesions. *Kathmandu Univ Med J.* 2019;67(3):248-50.
16. Khanal S, Singh YP, Sharma R. Batwing Technique in Large Volume Excision of Breast Lesions: Case Report. *J Inst Med Nepal.* 2019 Dec 5;41(2):70-2.
17. Hashem T, Morsi A, Farahat A, Zaghoul T, Hamed A. Correlation of Specimen/Breast Volume Ratio to Cosmetic Outcome After Breast Conserving Surgery. *Indian J Surg Oncol.* 2019 Dec;10(4):668-72.
18. Holmes DR, Schooler W, Smith R. Oncoplastic Approaches to Breast Conservation. *Int J Breast Cancer.* 2011;2011:303879.
19. In SK, Kim YS, Kim HS, Park JH, Kim HI, Yi HS, et al. Retrospective review of 108 breast reconstructions using the round block technique after breast-conserving surgery: Indications, complications, and outcomes. *Arch Plast Surg.* 2020 Nov;47(6):574-82.
20. Mohsen SM, Marzouk MA. Round block technique in the management of early stages of breast cancer: an assessment of the technique, oncological safety, and cosmetic outcomes. *Egypt J Surg.* 2018 Sep;37(3):271.
21. Farina MA, Newby BG, Alani HM. Innervation of the nipple-areola complex. *Plast Reconstr Surg.* 1980 Oct;66(4):497-501.
22. Cochrane RA, Valasiadou P, Wilson ARM, Al-Ghazal SK, Macmillan RD. Cosmesis and satisfaction after breast-conserving surgery correlates with the percentage of breast volume excised. *Br J Surg.* 2003 Dec;90(12):1505-9.
23. Anderson BO, Masetti R, Silverstein MJ. Oncoplastic approaches to partial mastectomy: an overview of volume-displacement techniques. *Lancet Oncol.* 2005 Mar;6(3):145-57.
24. Vinh-Hung V, Verschraegen C. For The Breast Conserving Surgery Project. Breast-Conserving Surgery With or Without Radiotherapy: Pooled-Analysis for Risks of Ipsilateral Breast Tumor Recurrence and Mortality. *JNCI J Natl Cancer Inst.* 2004 Jan 21;96(2):115-21.
25. André C, Holsti C, Svenner A, Sackey H, Oikonomou I, Appelgren M, et al. Recurrence and survival after standard versus oncoplastic breast-conserving surgery for breast cancer. *BJS Open.* 2021 Jan 22;5(1):zraa013.
26. Clough KB, van la Parra RFD, Thygesen HH, Levy E, Russ E, Halabi NM, et al. Long-term Results After Oncoplastic Surgery for Breast Cancer: A 10-year Follow-up. *Ann Surg.* 2018 Jul;268(1):165-71.
27. Hoffmann J, Wallwiener D. Classifying breast cancer surgery: a novel, complexity-based system for oncological, oncoplastic and reconstructive procedures, and proof of principle by analysis of 1225 operations in 1166 patients. *BMC Cancer.* 2009;9:108.