

Does Choice of Different Surgical Intervention Play a Role in the Recurrence of Pterygium?

Yadav R,¹ Das SS,¹ Gupta S,¹ Agrawal N²

¹Sagarmatha Choudhary Eye Hospital,
Lahan, Nepal.

²Taparia Eye Hospital,
Biratnagar, Nepal.

Corresponding Author

Reena Yadav
Department of Cornea Clinic,
Sagarmatha Choudhary Eye Hospital,
Lahan, Siraha, Nepal.
E-mail: reena.yadav@erec-p.org

Citation

Yadav R, Das SS, Sharad G, Agrawal N. Does Choice of Different Surgical Intervention Play a Role in the Recurrence of Pterygium? *Kathmandu Univ Med J.* 2023;83(3):254-9.

ABSTRACT

Background

There are a wide range of pterygium excision techniques in practice. However, choosing the best possible option is an important factor to prevent its recurrence.

Objective

To compare the recurrence rate of different excision techniques and understand if a surgeon can alter the recurrence rate.

Method

A retrospective data of pterygium surgeries operated by a surgeon at Sagarmatha Choudhary Eye Hospital, Nepal from the year 2016 to 2018 was investigated for recurrence. The recurrence was measured by an independent Optometrist with the help of clinical photo and slit-lamp examination. A telephonic directory was maintained for every patient's follow up reminder.

Result

Altogether 916 individuals with mean age 56.20 years had undergone pterygium excision. Bare Sclera 280 (30.56%), Pterygium Extended Conjunctival Transplantation (PERFECT) 305 (33.29%), Conjunctival auto graft (CAG) 262 (28.60%), Simple Pterygium excision 60 (6.55%) and Amniotic Membrane Graft (AMG) 9 (0.98%), jointly formed the total study sample and surgical techniques. Recurrence for Bare sclera was 172 (61.42%), simple pterygium excision 34 (56.66%), Pterygium extended conjunctival transplantation 0 (0%), and conjunctival auto graft 2 (0.76%). Compared conjunctival auto graft with pterygium extended conjunctival transplantation and simple pterygium with bare sclera revealed similar recurrence rate comparatively. The p-value obtained were $p = 0.2148$ and $p = 0.8152$ ($p > 0.05$, 95% CI) respectively.

Conclusion

The loss of limbal stem cells in Bare sclera technique acts as stimulant for pterygium recurrence, in addition the remains of pterygial matter in simple pterygium excision acts as precursor for recurrence. Pterygium extended conjunctival transplantation indeed acts as barrier but needs fine surgical skills to perform. Conjunctival auto graft can be opted as an alternative technique for minimal recurrence as compared to Pterygium extended conjunctival transplantation.

KEY WORDS

Bare sclera, Conjunctival auto graft, Pterygium surgery, Recurrence

INTRODUCTION

Pterygium is a triangular benevolent development of fibrovascular tissue beginning from the conjunctiva, further spread towards corneal limbus and past which may influence visual keenness in various manners.¹ Pterygium can be split into head, neck, and body. Head is the main edge of the pterygia on the cornea.^{1,2} Surgical procedure ought to be performed if vision is restricted and/or diplopia is noticed due to the development of numerous adhesions.^{3,4} The predominance of pterygium shifts all around with 3% in Australians, 7% in Singaporean Chinese and Indians, 15% in Tibetans in China, 18% in Mongolians in China, 23% in blacks in United States, 9-12% in Indians, 30% in Japanese and 10.08% in Nepalese.⁵⁻¹⁵

The fibrovascular regrowth extending across limbus post pterygium excision is termed as 'recurrence'.¹⁶ Recurrence rates between 24% to 89% have been reported with bare sclera and primary closure techniques.^{17,18} With Conjunctival auto graft (CAG), the rates fluctuate between 2-35% whereas 0% has been reported for pterygium extended conjunctival transplantation (PERFECT).^{19,20}

Recurrent pterygium is problematic for vision and difficult to manage. There have been little studies done so far in Nepal exploring the reasons associated with recurrences. Thus, this study aimed to analyse whether recurrence is associated with any type of pterygium surgery or it's a surgeon factor.

METHODS

A retrospective cohort study with prospective follow up was conducted at Sagarmatha Choudhary Eye Hospital (SCEH), Lahan, Nepal between 24-01-2016 to 20-01-2018. The ethical permission (ref: 776) to conduct the study was obtained from SCEH. All the records (baseline photo, surgical data and complication photos) of primary pterygium surgeries performed by a surgeon at SCEH, were extracted retrospectively (24-01-2017 to 20-01-2018) from the patient database and surgeon archive at SCEH. This was the main criteria for inclusion whereas patients under 18 years and missed follow-up at one year were excluded. We adopted the same definition of pterygium's recurrence in this study as mentioned above. After explaining about the different types of surgeries available with their pros and cons, choice of surgery was made by patient themselves. As a part of pterygium excision, the surgeon had performed Simple Primary Closure/simple pterygium, Bare Sclera, Amniotic Membrane Graft (AMG), Conjunctival Auto Graft (CAG), and Pterygium Extended Removal Followed by Extended Conjunctival Transplant (P.E.R.F.E.C.T). All different types of surgeries for pterygium were performed as per standard followed elsewhere.

In the surgical procedure of CAG, the surgeon not just dissected the pterygia but also removed the underlying

tenon's (Fig. 1) making sure that there were very minimal underlying tissues below the conjunctiva, in and around but not too deep (near the canthus and below the horizontal rectus muscle) as PERFECT surgery. The limbal margin and pterygio-corneal adherence was smoothed to get rid of tiny pterygial tissues. A thin and large autograft was taken from the superior conjunctiva devoid of underlying tenons and put at the point of dissection nearby the limbus and sutured along the conjunctiva with 8-0 Vicryl suture.

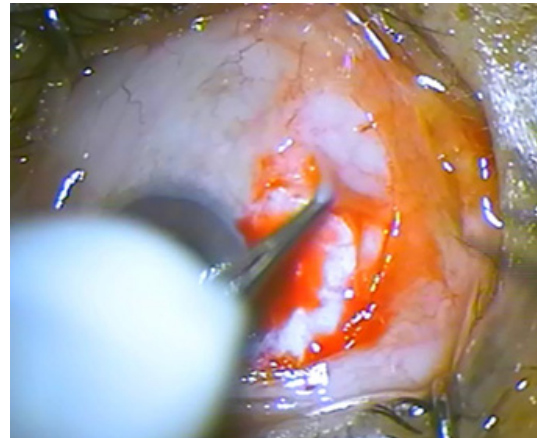


Figure 1. Surgical Removal of Tenon's

At one month follow up (scheduled for any pterygium surgery) patient was advised to follow up at 1 year in case no further problems noticed. At one year follow up patient was asked to sign a consent for the study followed by clinical photo and slit lamp examination (using SL imaging version 2.0,2.160 (92378)[®] 2012 camera inbuilt in SL 115 classic Carl Zeiss Meditec AG), performed by certified optometrist allocated for the study to limit the bias. Recurrence was measured with the help of a slit lamp, as done by Ang et al.¹⁶ In order to boost the follow-up rate, a closed loop was formed wherein at the end of every month, starting in January 2017, patient was given a telephonic reminder and recommended to visit the hospital if they had missed the 1 year follow up.

The data was entered into Microsoft excel spreadsheet which was further analyzed by 2X2 Chi-Square contingency table using trail version of GraphPad software (online version) for data analysis. The two-tailed Fisher's exact test was used to compare the recurrence rates of different surgical techniques to obtain a p value ($p < 0.05$ with 95% CI) with 5% margin of error. The analyzed data was further tabulated and plotted.

RESULTS

Out of 929 patients just 916 met the consideration criteria and were enrolled into the study. Of the 916 enrolled, 522 were female and 394 were male of mean age 56.20 (SD \pm 13.45) years, who had undergone primary pterygium excision a year ago. Different surgical techniques combinedly created the total study sample for which Bare

Sclera constitute 280 (30.56%), PERFECT 305 (33.29%), CAG 262 (28.60%), Simple Pterygium excision 60 (6.55%) and AMG 9 (0.98%) (Fig. 2).

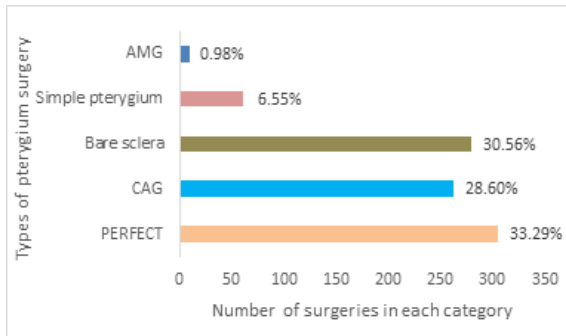


Figure 2. Overview of pterygium surgery performed between 2016 – 2018.

Bare sclera was found to be the most recurrent in the category of pterygium surgery. From a total of 280 eyes, 172 (61.42%) were noted as confirmed recurrence (Fig. 3) within a year span. Following the trend of recurrence Simple Pterygium excision was the second in the list of recurrence even though the number of Surgery (n=60) was less in this category but the recurrence of 34 (56.66%) was noted. Amniotic membrane graft (AMG) was performed less, and the numbers are not huge measurably. Of the total nine surgeries done, none of them had any recurrence within a year. Different surgical techniques and their recurrence rates are tabulated in table 1.

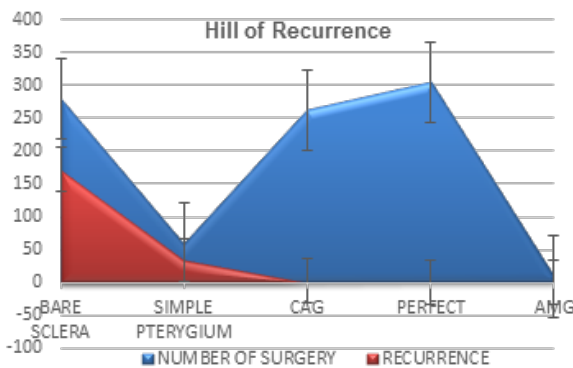


Figure 3. Recurrence profile of surgically excised pterygium with baseline surgical data

Table 1. List of different surgical techniques of pterygium excision and their recurrence percentage

Surgical techniques	Number of surgery (%)	Recurrence (%)
PERFECT	305(33.29)	0
CAG	262(28.60)	0.76
Bare sclera	280(30.56)	61.42
Simple pterygium	60(6.55)	56.66
AMG*	9(.98)	0

*Was excluded in the statistical analysis

We compared CAG and PERFECT with one another just because the recurrence rate was neck to neck and very promising. We found that both the surgeries have equal result in recurrence statistically. The two-tailed Fisher’s exact test p value equals 0.2148 ($p > 0.05$ with 95% CI), suggests the difference in recurrence rate of CAG and PERFECT surgical technique is not statistically significant. Patients from both the groups had come for follow up in which none from the PERFECT group at 12th month was noted to have recurrence whereas 2 cases of recurrence (Fig. 4) from CAG group at 11th and 12th month from the date of surgery were reported. Also, we compared Bare sclera and simple closure pterygium with one another as they had a greater number of recurrences. The fisher’s exact test revealed the p value of 0.81 ($p > 0.05$), which is statistically not significant, meaning both bare sclera and simple closure do not have difference in recurrence. The overall comparison of recurrence in different surgical groups is tabulated in table 2.

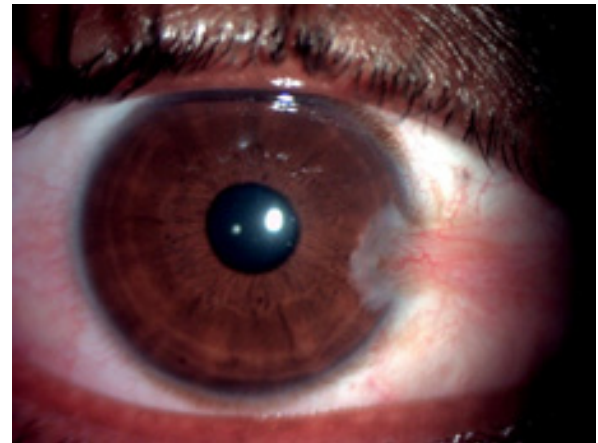


Figure 4. A 38-year male had undergone CAG surgery, presented with recurrence at 1 year follow up.

Table 2. Highest and Lowest Recurrence Surgery Groups with Group Totals

Type of Surgery	Numbers of Surgery (A)	Number of Recurrence (B)	Row Total	Column Total	p-value
A+B					
PERFECT	a 305	e 0	305	a+b 567	
CAG	b 262	f 2	264	e+f 2	0.2148
Bare sclera	c 280	g 172	452	c+d 340	
Simple Pterygium Excision	d 60	h 34	94	g+h 206	0.8152

Complications

The donor sites healed with no major complication, apart from three cases, which demonstrated granuloma (Fig. 5) formation at the donor site and recipient site which was excised surgically. Granuloma development is not uncommon in pterygium excision. Because of over the top

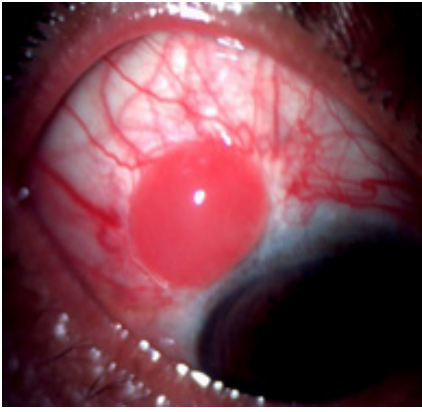

Figure 5. Non pyogenic granuloma formation at donor site followed by CAG surgery at 1 week

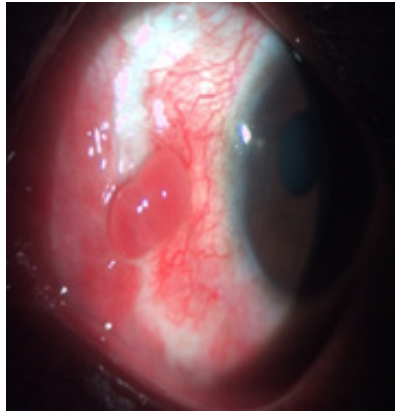


Figure 6. Non pyogenic granuloma formation at recipient site followed by CAG surgery at 1 week

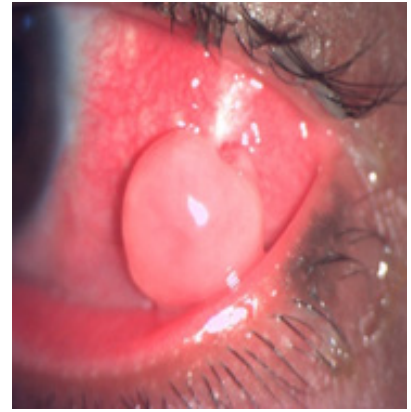


Figure 7. Non pyogenic granuloma formation at recipient site followed by PERFECT surgery at 1 week

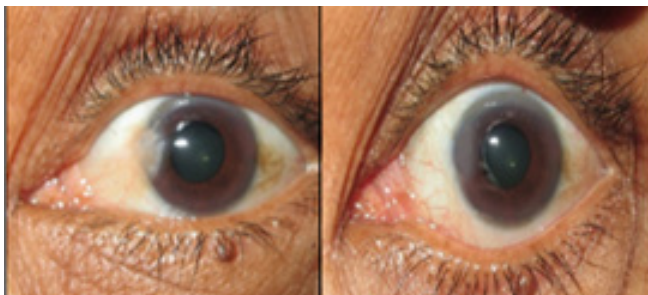


Figure 8. 45 years female, undergone PERFECT (before) surgery at 1 year follow up (after)

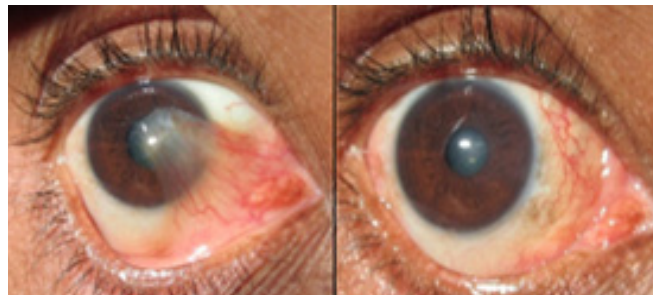


Figure 9. 39 years male, undergone CAG (before) surgery at 1 year follow up (after)

aggravation and confined bothering at the site of uncovered Tenon's tissue, granulomas can happen at donor site or harvest site.²¹ Two granulomas formed post-CAG (Fig. 5 and 6) surgery while the one was observed after PERFECT (Fig. 7) surgery.

Baseline and 1 year follow up picture of pterygium excised eyes of two different patients are illustrated in figure 8 and figure 9.

DISCUSSION

Bare sclera would be the least preferred surgery by any surgeon since it has the chance to infect the sclera due to its exposed nature. The recurrence rate reported in many studies from the past is way high for this procedure i.e., 24-89%.^{17,18,22,23} Our result revealed 61.42% which is in between the range set by other studies. Despite so many disadvantages, numbers are higher for this is just because of its economic surgery cost. Since the sclera is exposed (let it re-epithelize on its own) and there is nothing to restrict (no guarding mechanism is present) the cell proliferation, also there is a lot of inflammation around, which can results in recurrence of numerous blood vessels along with new ingrowth of pterygial tissue.²⁴ There is evidence of dropping the recurrence rate of bare sclera by splitting and rotating the pterygium head away from the cornea.²⁵ Similarly, simple pterygium excision also has suture related complications and its frequent recurrence

due to underlying tenon's bed and inflammatory mediated regrowth makes it less likely to perform if any surgeon is given chance to opt for.²⁴ AMG could be a good choice, but it needs skilled manpower, availability of amniotic membrane, higher cost, more time with great surgical skill, graft related complications, etc. are some challenges to it. It is difficult to assure the recurrence of AMG since the number of surgeries performed in this category was quite a few. Literature suggests the recurrence of AMG as 3.8% which is reasonably less.²⁶

Looking at our result, PERFECT was so far the best surgery in pterygium excision. The use of a diamond burr and deep dissection of tenon's as well as underlying fibrotic tissue keeping the muscle (medial rectus/lateral rectus) secure makes it unmatched. Our result for recurrence in the category of PERFECT surgery is 0% which corresponds to that of Hirst et al. 2009.²⁰ Although the name given is PERFECT so as the outcome but when it comes to implementation it counts to be under perfect for various reasons like, it needs meticulous attention with high level of surgical skill, it takes higher chair time, and it can be performed only in primary pterygium unless the surgeon has mastered the technique.²⁷ CAG was the next adventure to showcase the surgical skill of a surgeon. Our results for recurrence post CAG are very less which supports the study done by Hovanesian et al in the year 2017.²⁸ The cosmesis was as good as that of PERFECT and except two none of them was noted to have a recurrence. With the recurrence

rates of two to 35 percent, as stated by Simona et al in 1990, our results were much superior and promising with PERFECT having 0% and CAG (2/262) 0.76% recurrence, which clinically makes no difference between each other.¹⁹ It would not be wrong to quote that same surgery done by different surgeons may have variable outcome which can be well illustrated from a surgeon to surgeon variation in pterygium recurrence demonstrated by Ti et al.²⁹ The least recurrence of a surgeon reported by them was five percent, still an elevated range for us comparatively. Other most impactful point to note during CAG surgery is the graft size, larger the graft size less is the possibility of recurrence and replacing the limbal stem cell up to the maximum possibility from superior or inferior conjunctiva along with the graft acts as stopper for recurrence.^{30,31}

It is observed that retrospective studies have poor follow up rates but, in our case, the lost to follow up were minimized with telephonic reminders and motivation. The observer (optometrist) was not aware about the surgery type before surgery which minimizes the bias on reporting the recurrence. Amniotic membrane graft (AMG) was least performed among the pterygium surgeries. So, it is difficult to draw a clear conclusion for the same. Only one surgeon's surgical outcome was analyzed. Inter-surgeon variation of

surgical outcome for different pterygium surgeries could be the future scope.

CONCLUSION

This study shows PERFECT surgery has the best result among the other available surgical options for pterygium, but it is a time taking procedure and requires expertise. Bare sclera and the simple pterygium excision method have higher recurrence rates. However, CAG can be an alternate surgical choice for patients choosing bare sclera or simple pterygium surgery, provided the adjustment in the difference in surgical cost will be a challenge to explore further.

ACKNOWLEDGEMENT

The authors would like to thank Sagarmatha Choudhary Eye Hospital team for helping in every aspect of this research. We are thankful to Dr. Sanjay Kumar Singh and Mr. Abhishek Roshan for their administrative support in this study. We also acknowledge the support of cornea team Mr. Avinash Chaudhary, Mr. Rabi Shankar Sah, and Mr. Kamlesh Yadav in the management of study logistics.

REFERENCES

- Aminlari A, Singh R, Liang D. Management of pterygium. *Eye Net* [Internet][cited 2017 Dec 12] Available from:[https://www.aao.org/eyenet/article/management-of-ptyerium-2]. 2010.
- Shusko A, Hovanesian JA. Pterygium excision with conjunctival autograft and subconjunctival amniotic membrane as antirecurrence agents. *Can J Ophthalmol*. 2016;51(6):412-6.
- Youngson RM. Recurrence of pterygium after excision. *Br J Ophthalmol*. 1972 Feb;56(2):120-5.
- Zauberan H. Pterygium and its recurrence. *Am J Ophthalmol*. 1967 Jun;63(6):1780-6.
- Coroneo MT. Pterygium as an early indicator of ultraviolet insolation: a hypothesis. *Br J Ophthalmol*. 1993 Nov;77(11):734-9.
- Sharma R, Kjeldstad B, Espy P. UV Index and Total Ozone Column Climatology of Nepal Himalaya Using TOMS and OMI Data. *J Hydrol Meteorol*. 2015;9(1):45-59.
- McCarty CA, Fu CL, Taylor HR. Epidemiology of pterygium in Victoria, Australia. *Br J Ophthalmol*. 2000;84(3):289-92.
- Luthra R, Nemesure BB, Wu SY, Xie SH, Leske MC. Barbados Eye Studies Group. Frequency and risk factors for pterygium in the Barbados Eye Study. *Arch Ophthalmol*. 2001 Dec;119(12):1827-32.
- Lu P, Chen X, Kang Y, Ke L, Wei X, Zhang W. Pterygium in Tibetans: a population-based study in China. *Clin Exp Ophthalmol*. 2007 Dec;35(9):828-33. doi: 10.1111/j.1442-9071.2007.01630.x. PMID: 18173411.
- Lu J, Wang Z, Lu P, Chen X, Zhang W, Shi K, et al. Pterygium in an aged Mongolian population: a population-based study in China. *Eye*. 2009;23(2):421-7.
- Shiroma H, Higa A, Sawaguchi S, Iwase A, Tomidokoro A, Amano S, et al. Prevalence and risk factors of pterygium in a southwestern island of Japan: the Kumejima Study. *Am J Ophthalmol*. 2009 Nov;148(5):766-771.e1.
- Ang M, Li X, Wong W, Zheng Y, Chua D, Rahman A, et al. Prevalence of and racial differences in pterygium: a multiethnic population study in Asians. *Ophthalmology*. 2012 Aug;119(8):1509-15.
- Marmamula S, Khanna RC, Rao GN. Population-based assessment of prevalence and risk factors for pterygium in the South Indian state of Andhra Pradesh: the Andhra Pradesh Eye Disease Study. *Invest Ophthalmol Vis Sci*. 2013 Aug 9;54(8):5359-66.
- Nangia V, Jonas JB, Nair D, Saini N, Nangia P, Panda-Jonas S. Prevalence and associated factors for pterygium in rural agrarian central India. The central India eye and medical study. *PLoS One*. 2013 Dec 4;8(12):e82439.
- Maharjan IM, Shreshth E, Gurung B, Karmacharya S. Prevalence of and associated risk factors for pterygium in the high altitude communities of Upper Mustang, Nepal. *NEJOPH*. 2014 Jan 1;6(11):65-70.
- Ang LP, Chua JL, Tan DT. Current concepts and techniques in pterygium treatment. *Curr Opin Ophthalmol*. 2007 Jul;18(4):308-13.
- Zolli CL. Experience with the avulsion technique in pterygium surgery. *Ann Ophthalmol*. 1979 Oct;11(10):1569-76.
- Sebban A, Hirst LW. Pterygium recurrence rate at the Princess Alexandra Hospital. *Aust N Z J Ophthalmol*. 1991 Aug;19(3):203-6.
- Simona F, Tabatabay CA, Leuenberger PM. Résultats préliminaires de la technique d'excision du ptérygion avec autogreffe conjonctivale [Preliminary results of the pterygium excision technic with conjunctival autograft]. *Klin Monbl Augenheilkd*. 1990 May;196(5):295-7.
- Hirst LW. Recurrent pterygium surgery using pterygium extended removal followed by extended conjunctival transplant: recurrence rate and cosmesis. *Ophthalmology*. 2009;116(7):1278-86.
- Bhatia J, Varghese M, Narayanadas B, Bhatia A. Cut-and-place technique of pterygium excision with autograft without using sutures or glue: Our experience. *Oman J Ophthalmol*. 2017 May-Aug;10(2):81-6.

22. Chen PP, Ariyasu RG, Kaza V, LaBree LD, McDonnell PJ. A randomized trial comparing mitomycin C and conjunctival autograft after excision of primary pterygium. *Am J Ophthalmol*. 1995 Aug;120(2):151-60.
23. Jaros PA, DeLuise VP. Pingueculae and pterygia. *Surv Ophthalmol*. 1988 Jul-Aug;33(1):41-9. doi: 10.1016/0039-6257(88)90071-9. PMID: 3051468.
24. Van Acker SI, Haagdoorens M, Roelant E, Rozema J, Possemiers T, Van Gerwen V, et al. Pterygium Pathology: A Prospective Case-Control Study on Tear Film Cytokine Levels. *Mediators Inflamm*. 2019 Nov 12;2019:9416262.
25. Johnson RD, Pai VC, Hoft RH. Historical approaches to pterygium surgery, including bare sclera and adjunctive beta radiation techniques. *Pterygium: Techniques and Technologies for Surgical Success*. 2012;2012:27-36.
26. Ma DH, See LC, Liu SB, Tsai RJ. Amniotic membrane graft for primary pterygium: comparison with conjunctival autograft and topical mitomycin C treatment. *Br J Ophthalmol*. 2000 Sep;84(9):973-8.
27. Ophthalmology AAO. P.E.R.F.E.C.T. pterygium removal technique appears near perfect: AAO; JAN 23 2013 [Available from: <https://www.aao.org/editors-choice/perfect-terygium-removal-technique-appears-near>].
28. Hovanesian JA, Starr CE, Vroman DT, Mah FS, Gomes JAP, Farid M, et al. Surgical techniques and adjuvants for the management of primary and recurrent pterygia. *J Cataract Refract Surg*. 2017 Mar;43(3):405-19.
29. Ti S, Chee S, Dear K, Tan D. Analysis of variation in success rates in conjunctival autografting for primary and recurrent pterygium. *Br J Ophthalmol*. 2000;84(4):385-9.
30. Hirst LW. Recurrence and complications after 1,000 surgeries using pterygium extended removal followed by extended conjunctival transplant. *Ophthalmology*. 2012 Nov;119(11):2205-10.
31. Al Fayed MF. Limbal versus conjunctival autograft transplantation for advanced and recurrent pterygium. *Ophthalmology*. 2002 Sep;109(9):1752-5.