

# Endoscopic Transcanal Atticoplasty: How we do it?

Shrestha BL, KC AK, Karmacharya S

Department of ENT-HNS

Dhulikhel Hospital, Kathmandu University Hospital,  
Kathmandu University School of Medical Sciences.

Dhulikhel, Kavre, Nepal.

## Corresponding Author

Bikash Lal Shrestha

Department of ENT-HNS

Dhulikhel Hospital, Kathmandu University Hospital,  
Kathmandu University School of Medical Sciences.

Dhulikhel, Kavre, Nepal.

E-mail: bikashotology267602@gmail.com

## Citation

Shrestha BL, KC AK, Karmacharya S. Endoscopic transcanal atticoplasty: How we do it? *Kathmandu Univ Med J.* 2023;83(3):331-2.

## INTRODUCTION

The attic retraction pocket and cholesteatoma are primarily caused by defective ventilation of the attic. Untreated, they can lead to serious complications. Treatment options include conventional microscopic and the newer endoscopic approaches. Unlike a microscope, a 0-degree nasal endoscope, 4 mm in diameter and 18 cm in length, provides a panoramic and magnified view on a monitor, making surgery more comfortable for the surgeon. Our experience with over 1200 endoscopic ear surgeries since 2012 shows that a transcanal endoscopic approach to the middle ear and epitympanum provides adequate access to the attic and all vital middle ear structures. This viewpoint describes our endoscopic atticoplasty technique and preliminary results of the first 20 transcanal endoscopic atticoplasties performed at our institution. We highly recommend that otologists interested in using endoscopy for atticoplasty acquire adequate experience in all aspects of total endoscopic ear surgery for middle ear disorders.<sup>2</sup>

### Surgical procedure (endoscopic Atticoplasty)

#### Preparation of the external auditory canal

The patient is kept on supine position with the head turned towards opposite side. The operating ear is examined by 0 degree nasal endoscope. The ear canal is slowly

## ABSTRACT

Endoscopic otological surgery has revolutionized ear surgery. Endoscopes are frequently used in myringoplasty and tympanoplasty, and their use in attic reconstruction (atticoplasty) is gaining popularity. While microscopic surgery for limited attic cholesteatoma and attic retraction (grade III and IV) is difficult especially anterior area, the endoscope has emerged as a new treatment option, offering a 360-degree view of the attic and facilitating the complete removal of diseased tissue.<sup>1</sup> We had performed atticoplasty with rigid nasal endoscopes (Karl Storz) of 4 mm diameter and 18-cm length. Our preliminary results showed that transcanal endoscopic atticoplasty is a reliable and safe technique for the surgical management either attic retraction pocket (grade III or IV) or limited attic cholesteatoma.

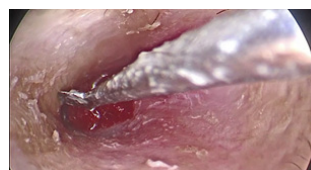
## KEY WORDS

*Atticoplasty, Attic retraction, Endoscope, Ear surgery*

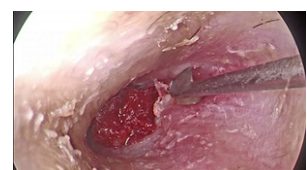infiltrated with 2% lignocaine with 1:2,00,000 adrenaline solution in all the four quadrants. It is necessary to perform the infiltration slowly to avoid blister formation in the canal skin. After infiltration, the ear canal is packed with cottonoids soaked in 1:1000 adrenaline to reduce bleeding. The surgery is performed under general anesthesia.

#### Elevation of the tympano-meatal flap (fig. 1)

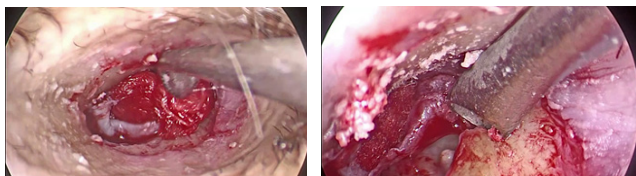
After sterile preparation and draping, the ear canal is examined with a 0-degree, 4-mm nasal endoscope. A canal incision is made at the 7 and 1 o'clock positions with a Plester knife (Fig. 1 and 2). The two incisions are then joined with a Rosen knife, and the tympanomeatal flap is elevated to the annulus (Fig. 3). Once the annulus is identified, the middle ear is entered, taking care to preserve the chorda tympani nerve. The crucial middle ear structures are then identified.



**Figure 1.** Canal incision at 7 o'clock position.



**Figure 2.** Canal incision at 1 o'clock position.



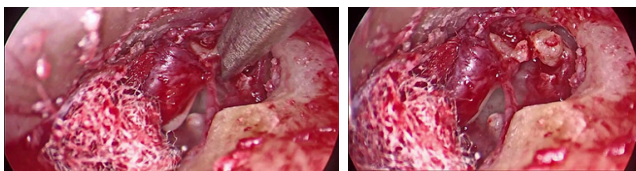
**Figure 3.** Elevation of tympanomeatal flap. **Figure 4.** Curretting posterior superior canal wall and attic.

#### Curretting posterior superior canal wall and attic

Next, the posterior bony canal wall and attic area are curretted to visualize the attic retraction pocket and/or attic cholesteatoma (Fig. 4). Curettage is continued until the lateral semicircular canal is visualized.

#### Dislocation of incudostapedial joint and removal of malleus head:

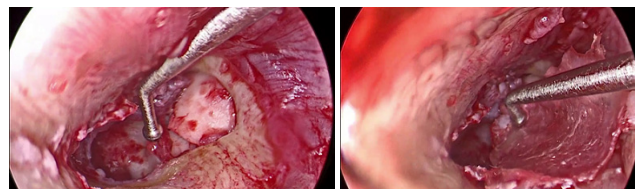
Meanwhile, the incus is separated from the malleus and the malleus head is removed to assess the anterior epitympanum (Fig. 5 and 6). Once all the epitympanic structures have been visualized, the retraction pocket and/or cholesteatoma is removed in toto.



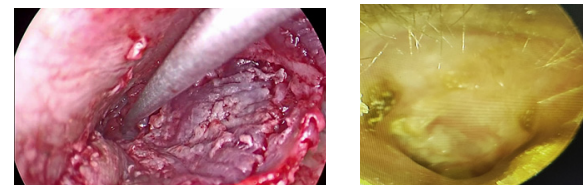
**Figure 5.** Cut and removal of malleus head. **Figure 6.** Cut and removal of malleus head.

#### Atticoplasty

The atticotomy defect is covered with slices of tragal cartilage (atticoplasty) (Fig. 7). The atticoplasty area and any defects in the pars flaccida and pars tensa are grafted with tragal perichondrium (Fig. 8). The tympanomeatal flap is repositioned (Fig. 9). At the end of the procedure, absorbable gel foam is placed to hold the graft in place, and the ear canal is packed with ribbon gauze soaked in ciprofloxacin ointment.



**Figure 7.** Attic defect covered with slices of tragal cartilage. **Figure 8.** Atticoplasty area grafted with tragal perichondrium.



**Figure 9.** Final reposition of tympanomeatal flap. **Figure 10.** Six months post-operative status of left ear.

## RESULTS

The surgery took an average of 90 minutes (range 70-100 minutes). Pure tone audiograms are performed 12 weeks postoperatively, and 6-months follow-up shows good graft uptake (Fig. 10.) and air-bone gaps (ABGs) within 10-15 dB. We did not observe any intraoperative or postoperative complications.

## CONCLUSION

Our preliminary results showed that endoscopic atticoplasty using a 0-degree nasal endoscope is rewarding and easy to perform in cases of limited attic cholesteatoma/attic retraction pocket (grade III and IV). The advantages of using endoscopes include a good quality panoramic image of the middle ear and epitympanic anatomy, and minimal handling of the chorda tympani nerve. The disadvantages include the need for a one-handed technique and the lack of depth perception. Therefore, surgeons who wish to perform endoscopic atticoplasty should have in-depth knowledge and experience in all forms of endoscopic middle ear surgery.

## REFERENCES

1. Tarabichi M. Endoscopic management of limited attic cholesteatoma. *Laryngoscope*. 2004 Jul;114(7):1157-62. doi: 10.1097/00005537-200407000-00005. PMID: 15235340.
2. Shrestha BL. Endoscopic Ear Surgery in Dhulikhel Hospital: A decade of Experience. *Kathmandu Univ Med J (KUMJ)*. 2022 Oct-Dec;20(80):518-521. PMID: 37795735.