

Custodial Death

Singh PK, Karki A

Department of Forensic Medicine

Kathmandu University School of Medical Sciences,
Dhulikhel, Kavre, Nepal.

Corresponding Author

Pankaj Kumar Singh

Department of Forensic Medicine

Kathmandu University School of Medical Sciences,
Dhulikhel, Kavre, Nepal

E-mail: drpankaj_s@yahoo.in

Citation

Singh PK, Karki A. Custodial Death. *Kathmandu Univ Med J.* 2023;84(4):453-5.

INTRODUCTION

International Committee of the Red Cross (ICRC) has defined custody as a beginning from the moment a person is apprehended, arrested or otherwise deprived of his/her liberty by agents of the State, or by agents of any other public or private entity or organisation, including in particular correctional or medical institutions or security companies, operating within the jurisdiction of that State.¹ Death of an individual who is in prison or while under custody which can be due to natural causes, violence, poisoning, or even accidents is known as custodial death.² We are presenting the case of a young boy who was in a rehabilitation center, taken to nearby hospital for some health emergency, at Kavrepalanchok, Nepal. This gentle man was declared brought dead at the hospital. As per the autopsy protocol, autopsy was requested by the investigating authority and complete medicolegal autopsy was conducted at Dhulikhel Hospital, KUSMS, Kavrepalanchok, Nepal. The postmortem examination revealed head injury sustained due to blunt force trauma as the cause of death with histo-pathological report suggesting the evidence of acute tubular necrosis. Informed written consent was obtained from the relatives of the deceased for the publication of this report and accompanying images.

ABSTRACT

The authors report a case of death of 16 years old boy in custody of a rehabilitation center. The young boy was taken to hospital for some health issues after severe torture where he was declared dead and brought for medicolegal autopsy under the requisition of investigating authority. Autopsy examination revealed multiple abrasions and intradermal contusions of ante-mortem origin and fresh at the time of death on various parts of the body including intradermal contusions on bilateral soles, subscalpal hematoma, subdural with minimal subarachnoid haemorrhages were observed. Histo-pathological examination of bilateral kidneys revealed features of acute tubular necrosis which is due to release of myoglobin as result of skeletal muscle necrosis sustained due to repeated blunt force trauma. The cause of death was attributed to head injury. Deceased was tortured by hitting over soles which is also known as falanga, and the second most common form of torture after beating the body. The fatal maltreatment and death of people who are detained against their will often raises controversy therefore nonpartisan information on cause of death is required to conclude that human rights were abused. So, medicolegal autopsy provides scientific basis for the occurrence of injury and establishing cause of death.

KEY WORDS

Autopsy, Custodial death, Necrosis, Torture

CASE REPORT

A boy of 16 years was in rehabilitation center for 18 months; on January 30 2022 he was taken to nearby hospital for medical emergency where he was declared brought dead, as per the protocol an autopsy was requested by the investigating authority. On external examination, abrasions were present on forehead at midline and contusions seen on both lips (fig. 1). Patterned abrasion was present on the medial aspect of left thigh (fig. 2). Abrasions with dark brown scab were present on posterior aspect of right lower arm, posterior and medial aspect of right elbow joint, posterior and medial aspect of right wrist joint, anterior and medial aspect of left leg, and contusions were present on both palms involving all fingers (fig. 3). Contusions were also seen on bilateral soles (fig. 4). Internally subscalpal hematoma over the occipital region (fig. 5) with subdural and minimal subarachnoid haemorrhage was observed. Other organs were intact and congested. X incision was given (fig. 3) on posterior surface of body from tip of bilateral shoulder joint to opposite bilateral iliac spine and ending at the base of 3rd toe on the sole of bilateral foot.³ After reflecting the skin, intradermal contusions were evident on the bilateral gluteal regions (fig. 6 and fig. 7),

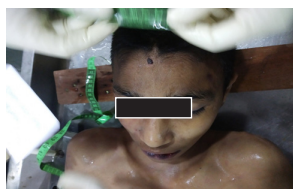

Figure 1. Abrasion with dark brown scab on forehead and contusion on both lips.

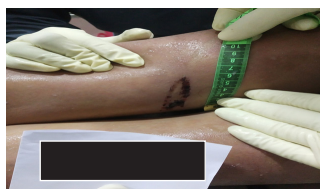

Figure 2. Patterned abrasion present on medial aspect of left thigh.

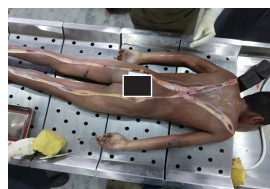

Figure 3. Demonstration of multiple abrasions and contusions on posterior body surface with X-incision.



Figure 4. Contusions present on bilateral soles, front of left leg and abrasion on left leg.

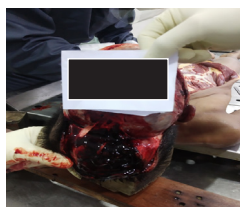

Figure 5. Subscalpal haematoma on occipital region.

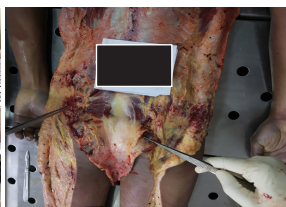


Figure 6. Contusions present on bilateral gluteal region.

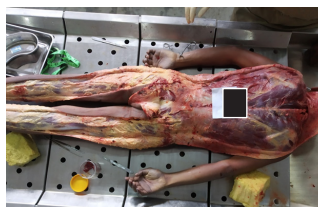

Figure 7. Intradermal contusions present on posterior aspect of left leg and thigh

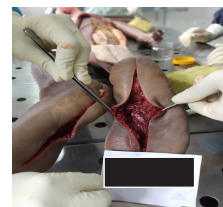

Figure 8. Intradermal contusions present on right sole.

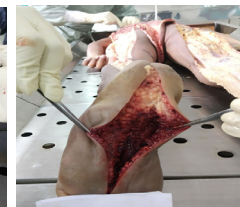

Figure 9. Intradermal contusion present on left sole.

posterior aspect of left leg and thigh (fig. 7), right sole (fig. 8) and left sole (fig. 9). Routine viscera for chemical analysis and a piece of white cloth soaked in deceased's blood were sealed, labeled and handed over to the investigating authority. Pieces of bilateral kidneys were sent for histopathological examination. Chemical analysis report of viscera is yet to be available till the date of reporting the case whereas histopathological examination of pieces of bilateral kidneys showed features of tubular necrosis.

DISCUSSION

Deliberate, systematic or wanton infliction of physical or mental suffering by one or more persons acting alone or on the orders of any authority, to force another person to yield information, to make a confession, or for any other reason is known as torture.⁴ A study has shown beating the body as the most common method of torture in 99% of cases followed by falanga (in 32% of cases) which is severe beating on the soles of the feet resulting in extreme pain and possibly causing fractures of bones, swelling of feet or the development of blisters.⁵

In a study conducted by Pollanen MS on 2017, the author found that multiple blunt impacts were common form of violence in torture. Head injuries along with diffuse subdural haemorrhage were observed commonly. Extensive soft tissue injuries were found frequently which necessitates performing complete musculocutaneous dissection of torso and limbs, which was followed by the author in this case.⁶

Thomsen JL, in 2000 observed fresh bruises and excoriations in a face of young man which was consistent with beating with a stick, similar were the findings observed by the author in this case.⁷ There were abrasion on forehead and contusion on both lips (fig.1) which were consistent with the use of blunt force.

On 2011, Byard WR and Singh B reported case of 27 years old male who was in police custody for 6 days and found bruising of face, ears, wrists, hands, upper limbs, thighs, knee joints and lower legs. Diffuse bruising over the soles and dorsa of both feet with soft tissue swelling were present which were typical of falanga where soles of feet are repetitively beaten with blunt objects. The subject died of traumatic brain haemorrhage.⁸ As reported by the author in fig. 4, fig. 8 and fig. 9, there were diffuse contusions over lower limbs which were consistent with the features present in cases of falanga.

In the case reported by author, subject has been physically abused as autopsy and histopathological findings are consistent with the application of blunt force. Histopathological examination revealing tubules with cellular edema, disrupted epithelium and areas of necrosis are suggestive of early ischemic acute tubular necrosis which is due to deposition of myoglobin in renal tubules, released from necrosed skeletal muscle as a result of multiple blunt force trauma inflicted on the deceased.^{9,10} The subject died as a result of head injury sustained due to blunt force trauma.

Custody means under the guardianship and death in custody can be considered as one of the cruelest forms of human kind and breaches the right to live.¹¹ Rehabilitation center itself is a form of custody where the death of anyone taking shelter warrants investigation and proper postmortem examination.

The definition of torture is restricted to apply only to nations and government-sponsored torture perpetrated directly or indirectly by government personnel, law enforcement personnel or military personnel and apparently excludes the pain and suffering inflicted by private institutions or other non-governmental organizations operating within the territory.¹² Author feels the need to revise the definition of torture.

The use of special dissection technique in medicolegal autopsy to search for musculocutaneous injury is crucial to provide scientific basis for the occurrence of injury and

establish cause of death. Also postmortem examination of victims of physical abuse is helpful to interpret and manage signs in living victims.¹³

REFERENCES

1. Advocacy Forum-Nepal. Custodial deaths in Nepal Towards a framework for Investigation and Prevention. *DKA Austria Hilfskathol Jungschan*. 2022 Jun 26;(1):9.
2. Wu S, Zhuo L, Qiu X, Ding Z, Yang M, Pan M, et al. Unexpected custodial death due to acute epiglottitis: A rare autopsy case report. *Medicine (Baltimore)*. 2018 Feb;97(7):e9941.
3. Hiss J, Kahana T. Medicolegal Investigation of Death in Custody: A Postmortem Procedure for Detection of Blunt Force Injuries: *Am J Forensic Med Pathol*. 1996 Dec;17(4):312-4.
4. Altun G, Durmus-Altun G. Confirmation of alleged falanga torture by bone scintigraphy? Case report. *Int J Legal Med*. 2003 Dec 1;117(6):365-6.
5. de Zoysa P, Fernando R. Methods and sequelae of torture: a study in Sri Lanka. *Torture*. 2007;17(1):53-6.
6. Pollanen MS. The Dead Detainee: The Autopsy in Cases of Torture. *Acad Forensic Pathol*. 2017 Sep;7(3):340-52.
7. Thomsen JL. The role of the pathologist in human rights abuses. *J Clin Pathol*. 2000 Aug 1;53(8):569-72.
8. Byard RW, Singh B. Falanga torture: characteristic features and diagnostic issues. *Forensic Sci Med Pathol*. 2012 Sep;8(3):320-2.
9. Malik GH, Sirwal LA, Reshi AR, Najjar MS, Tanvir M, Altaf M. Acute Renal Failure following Physical Torture. *Nephron*. 1993;63(4):434-7.
10. Hanif MO, Bali A, Ramphul K. Acute Renal Tubular Necrosis. 2023 Jul 4. In: StatPearls [Internet]. Treasure Island (FL): StatPearls Publishing; 2024 Jan--.
11. Pracheen R. Custodial Death Critical Analysis. *Xilkogretim Online - Elementary Educ Online*. 2021;20(5):1860-7.
12. Herath JC, Pollanen MS. Clinical Examination and Reporting of a Victim of Torture. *Acad Forensic Pathol*. 2017 Sep;7(3):330-9.
13. Pollanen MS. The pathology of torture. *Forensic Sci Int*. 2018 Mar;284:85-96.