

# Role of Intraoperative Cholangiogram in Major Liver Resection and Complex Bilio-enteric Bypass Surgery

Ghimire R, Pandey P, Acharya BP

Department of Gastrointestinal and General Surgery,  
Kathmandu Medical College Teaching Hospital,  
Kathmandu, Nepal.

## Corresponding Author

Roshan Ghimire

Department of Gastrointestinal and General Surgery,  
Kathmandu Medical College Teaching Hospital,  
Kathmandu, Nepal.

E-mail: roshanghimire194@gmail.com

## Citation

Ghimire R, Pandey P, Acharya BP. Role of Intraoperative Cholangiogram in Major Liver Resection and Complex Bilio-enteric Bypass Surgery. *Kathmandu Univ Med J.* **Online First.**

## ABSTRACT

### Background

Advances in surgery have decreased postoperative morbidities but bile leak is still a major issue. Intraoperative cholangiogram (IOC) is considered better in identifying bile leaks and anatomical delineation making its expanded use in hepato-biliary surgeries.

### Objective

To assess the role of intraoperative cholangiogram in major hepatectomy and complex bilio-enteric bypass surgery.

### Method

A single-centered, descriptive cross-sectional study between March 2022 to February 2023 among conveniently sampled 32 patients undergoing Hepato-biliary surgeries. One ampoule of meglumine diatrizoate was instilled into the biliary tract and intraoperative pictures were taken via C-arm to visualize the biliary tree and pre-operative and intra-operative pictures were compared.

### Result

A total of 32 patients were included in the study with a median age of 42 years and a male-female ratio of 1:1.67. During the bilio-enteric anastomosis, no intraoperative anastomotic leaks were detected. Two patients experienced postoperative bile leakage that was managed conservatively and eight cases had intraoperative bile leakage which was addressed during surgery. The average duration of hospital stay was 5 days.

### Conclusion

An intraoperative cholangiogram is useful to delineate the biliary tract anatomy, reassure anastomosis, and identify bile leaks in difficult bilio-enteric anastomosis and from liver resection margins intraoperatively.

## KEY WORDS

*Complex hepatobiliary surgery, Intraoperative cholangiogram, Liver resection*

## INTRODUCTION

Various preoperative imaging modalities having different sensitivity and specificity like MRCP, CT, Endoscopic Ultrasound, etc. which are used to evaluate the anatomy of the biliary tree and to look for any associated pathologies however even with preoperative delineation intraoperative confirmation or to overcome intraoperative difficulties intraoperative imaging modalities like intraoperative cholangiogram (IOC), ICG, etc. have a critical role.<sup>1</sup> A better understanding of liver and biliary tract anatomy and physiology with the help of advanced imaging equipment along with advances in surgical procedures have decreased the incidence of postoperative liver failure and other morbidities but the problem related to biliary leakage is still the same.<sup>2,3</sup> The incidence of biliary leakage after hepatic resection for various reasons like donor hepatectomy or tumor resection ranges from 4 to 9.8% and has remained almost constant in the last few decades which is still the most common major morbidity.<sup>4-6</sup> Various agents such as injection of methylene blue, indocyanine green or a contrast can be injected into the main bile duct through either the cystic duct (after cholecystectomy) or through the enterotomy (after bilio-enteric anastomosis) and used for early detection of bile leakage from anastomosis site or the resected liver margin. It can detect leakage in up to 19.7-80% of patients, however, IOC is better at detecting these leaks than any other methods.<sup>6</sup> Although the rate of postoperative mortality of HPB surgery has been decreasing, the operative mortality rates are still high and are reported up to 1.7%.<sup>7</sup>

Though IOC was previously used in detecting common bile duct stones, delineating the anatomy of the biliary ducts, and identifying other abnormalities like fistulas, cysts, and tumors of the biliary system, in our case we are evaluating its usefulness in anatomical assessment of complex bilio-enteric bypass surgery and identifying bile leaks from major liver resection margins or after a complex bilio-enteric bypass.<sup>8</sup> Many intraoperative investigative modalities like ICG, intraoperative USG, and IOC have been used to understand surgical anatomy to facilitate the surgical team to overcome difficulties but IOC has the advantage of easy availability, cost-effectiveness, easy handling, and pre-operative interpretation of imaging. Though the advancements in overall management are notable and have been associated with significant improvement in perioperative morbidity and mortality by delineation of intraoperative surgical anatomy this study aims at the role of IOC in anatomical assessment in bilio-enteric bypass surgery and to assess biliary leakage.

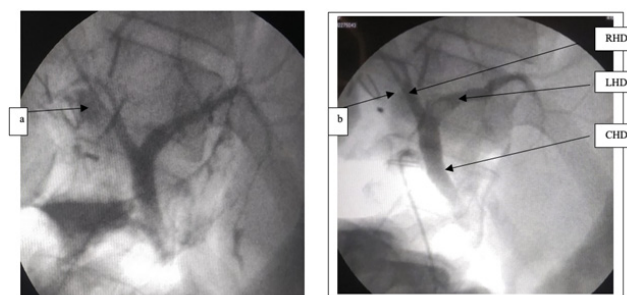
## METHODS

This study is a single-centered, descriptive cross-sectional study of 32 conveniently sampled patients who underwent

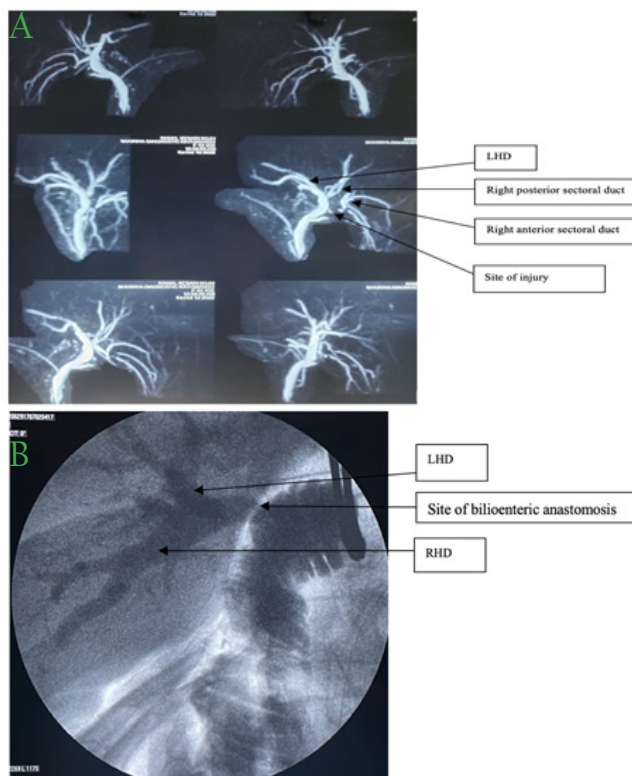
complex hepato-biliary surgeries in Kathmandu Medical College and Teaching Hospital from August 2022 to July 2023. All patients undergoing complex Hepato-biliary surgeries including major liver resections (segmentectomies) with or without bilio-enteric bypass and complex bilio-enteric anastomosis surgeries (resection of biliary tree above hilum with  $\geq 2$  bile ducts requiring hepatico-jejunostomy), during the study period were enrolled in the study. One ampoule of meglumine diatrizoate (Urografin 76%) was diluted in 250 ml of normal saline and was installed via trans-cystic, trans-ductal, or enterotomy routes before any vital structures were dissected and divided, and intraoperative pictures were taken via C-arm to visualize biliary tree and preoperative and intraoperative pictures were compared. A harmonic scalpel along with cautery was used for liver resection and polydioxanone sulfate 4-0 sutures were used for bilio-enteric anastomosis, using the simple interrupted suturing technique.

The ethical approval was taken from the institutional review committee of Kathmandu Medical College and Teaching Hospital (Ref No-13072022/04). Informed written consent was obtained from all patients for the utilization of their data for research purposes. The study population included all patients fulfilling the selection criteria which included patients undergoing complex HPB surgeries (Complex Hepatico-jejunostomy and major liver resections) who were more than 18 years of age and consented to the study. The exclusion criteria included patients allergic to contrast material and non-consenting to the study. The investigator did a sample size calculation using our previous year's data for calculating prevalence.

Only experienced consultant HPB surgeons were performing the surgery. Preoperative and intraoperative pictures were taken and compared. Another experienced surgeon from a different unit evaluated the photographs for internal validation. A self-structured questionnaire (proforma) was used where all the parameters needed for the study were included. Data were initially entered into MS Excel sheets and analyzed with the SPSS 20.0 version. Results were analyzed using appropriate statistical methods.



**Figure 1.** Resection of segment VII of liver with cholecystectomy {First image shows contrast leak from resection margin (a), second image: control of leak after reinforcement suture (b) (RHD- Right Hepatic duct; LHD- Left Hepatic Duct; CHD- Common Hepatic Duct)}



**Figure 2.** Right Anterior Sectoral Duct Injury S/P Lap turned Open Cholecystectomy (A) and IOC after HJ (B)

**RESULTS**

We included 32 patients who had undergone major liver resections with or without bilio-enteric bypass and complex bilio-enteric anastomosis surgeries, of which 12 were males and 20 were females with a male-female ratio of 1:1.67. The predominant age group was 40-50 with a median age of 46 (Table: 1).

**Table 1. Patient demographics**

Variables	Number (%)
<b>Age (years)</b>	
<30	2 (6.25)
31-50	19 (59.375)
51-70	7 (21.875)
>70	4 (12.5)
<b>Sex</b>	
Male	12 (37.5)
Female	20 (62.5)

The most common indication for surgery was hilar cholangiocarcinoma (n=7, 21.88%) followed by bile duct injury (Strasberg type E3 and above) (n=5, 15.63 %) and carcinoma gall bladder with intrahepatic extension and Hepaticolithiasis (n=4, 12.5 %). Other indications of surgery were giant hepatic hemangioma, hepatocellular carcinoma and hepatic hydatid cyst (n=3, 9.38% each), choledochal cyst type IVa (n=2, 6.25% each), and biliary cystadenoma (n=1, 3.125%) (Table:2).

**Table 2. Procedures performed**

Indications of surgery	Number (%)
Hilar cholangiocarcinoma	7 (21.88)
Bile Duct injury (Strasberg type E3 and above)	5 (15.63)
Hepaticolithiasis	4 (12.50)
Carcinoma GB with Intrahepatic Extension	4 (12.50)
Hepato cellular carcinoma	3 (9.37)
Giant hepatic hemangioma	3 (9.37)
Hepatic hydatid cyst	3 (9.37)
Choledochal cyst type IV	2 (6.25)
Biliary Cystadenoma	1 (3.13)

Surgeries performed include Extrahepatic biliary tract excision with HJ (more than 2 in number) (6/32, 18.75%), Right hemi hepatectomy (9/32, 28.125%), Left hemi-hepatectomy (4/32, 6.25%), Left hemi-hepatectomy with caudate lobectomy with Roux-en-Y HJ (3/32, 9.38%), Right hemi-hepatectomy with left HJ (4/32, 12.5%), Left hemi-hepatectomy with Roux-en-Y HJ (2/32, 6.25%) and extended cholecystectomy with HJ (4/32, 12.5%) (Table 3).

**Table 3. Procedures performed**

Procedures	Number (%)
Extrahepatic biliary tract excision with HJ (more than 2 HJ in number)	6 (18.75%)
Extended cholecystectomy with HJ	4 (12.5%)
Right hemihepatectomy with left HJ	4 (12.5%)
Left hemihepatectomy with caudate lobectomy with Roux-en-Y HJ	3 (9.38%)
Left hemihepatectomy	4(6.25%)
Right hemi hepatectomy	9 (8.125%)
Left hemihepatectomy with Roux-en-Y HJ	2 (6.25%)
Choledochal cyst type IV	2 (6.25)
Biliary Cystadenoma	1 (3.13)

The mean duration of hospital stay was 5 days with the duration of hospital stay ranging from 3 to 12 days. The average duration of abdominal drain continuation was 8 days, with the drain continued for a minimum of 4 days and a maximum of 14 days.

**Table 3. Morbidities**

Morbidities	Number	Clavien-Dindo Classification
Biliary fistula	2	2
Superficial SSI	2	1
Wound dehiscence	1	3a
Bilioma	1	3a
Post-operative blood transfusion	4	2

In cases of complex bilio-enteric anastomosis, the bile leak was identified intraoperatively in 4 cases and reinforcement sutures were taken and the absence of

bile leak was confirmed. However postoperative bile leak after intrahepatic biliary tract excision and bilio-enteric anastomosis was seen in 2 patients for which the drain was removed only after 12 and 14 days of surgery when drain output was minimal for 3 days and USG confirmed the absence of any intraperitoneal collection. Intraoperative contrast leakage from the liver resection margin after IOC was noticed in 8 out of 32 patients, and reinforcement sutures were taken intraoperatively and IOC was repeated to confirm control of contrast extravasation from the resection site. No extravasation of contrast was noted from the bilio-enteric bypass sites intraoperatively. Four patients of liver resection required blood transfusion in the postoperative period due to a drop in hemoglobin level. On follow-up, bilioma formation was noted in one patient which was managed conservatively with percutaneous catheter drain placement, and repeat hospital admission was required for both of the patients.

## DISCUSSION

In our study, per-operative cholangiogram detected bile leak from the resected liver margin in 8 (25%) patients with major hepatic resections which was controlled in the same setting with sutures, but 1 (3.15 %) patient later presented with bilioma. In cases of complex bilio-enteric anastomosis, no bile leak was identified intraoperatively but in 2 (10.5%) cases the drain was needed up to 2 weeks post-operatively without further complications.

Despite improvements in surgical techniques and the skills of the surgeon, leakage from the liver resection sites and bilio-enteric anastomosis sites are still common. Intraoperative diagnosis and management of these complications can prevent further morbidity and mortality in these patients.

The high incidence of bile leak in our study might be due to the gravity of surgery and the high risks associated with the patients like major hepatic resection and exposure of major biliary ducts demanded by the extensiveness of surgery. Furthermore, complex bilio-enteric anastomosis is also very vulnerable to major and minor leaks. The minor leaks in our study needed no further treatment except for the continuation of the intraabdominal drain.

Intraoperative cholangiogram is pivotal in enhancing anatomic delineation and patient safety providing real-time imaging of the anatomy and thus helping to identify bile ducts, biliary leakage, detect stones, and avoid bile duct injuries. IOC is particularly valuable in complex cases where anatomy may be altered or unclear, such as in patients with previous surgeries, tumors, or anatomical variations. The immediate visual perception allows surgeons to make informed decisions during the procedure, reducing the risk of complications and improving overall surgical outcomes.

The incidence of bile leak after liver resection with bilio-enteric anastomosis was demonstrated as 36.9%.<sup>9</sup> But in other studies, where partial liver resection has reported the incidence of bile leak to be between 3.6 and 12% similar to our study results.<sup>10,11</sup> A study done in Japan from in 1999-2006, reported a biliary complication (mostly biliary leakage) incidence of 7.5% in 731 patients of donor hepatectomy. In donor right hepatectomy, the incidence of biliary leakage was 9.9-11.1% and as a result of this, 29 patients underwent ERCP and stenting and 6 patients were reoperated.<sup>6</sup> Similar study from Germany concluded that the overall incidence of bile leaks in this cohort was 14.0% and the risk factors contributing to bile leaks included preoperative chemotherapy or biliary intervention, a diagnosis of hilar cholangiocarcinoma, colorectal metastasis, central minor liver resection, major hepatectomy, extended hepatectomy, or two-stage hepatectomy. Preoperative chemotherapy, major hepatectomy, and biliodigestive reconstruction are common risk factors for bile leaks.<sup>12,13</sup>

IOC has the distinct advantage of a short learning curve and also cost-effectiveness.<sup>14,15</sup> The cost of prolonged hospital stay, multiple interventions, cost of repair of BDI, and psychological stress to the patient are not comparable with the cost of use of IOC.<sup>16</sup> The only distinct disadvantage would be radiation exposure.

Several authors have documented using near-infrared fluorescent cholangiography in various hepatobiliary surgeries and their experiences suggest that fluorescent imaging is a safe and effective method for visualizing and identifying biliary anatomy supplementing white light imaging and the use of ICG fluorescence poses no radiation risk to patients, does not significantly extend operative time and has a short learning curve.<sup>17-21</sup> There is availability of indocyanine green cholangiography at our center which can be used but the cost is higher and the technology associated with it is not available everywhere.

Another important modality with high effectiveness in expert hands is intraoperative ultrasound for the real-time intraoperative visualization of hepatobiliary anatomy showing details images and improving the surgical efficacy by navigating the anatomical complexities with the detection of abnormalities.<sup>22-26</sup> This has gained popularity recently but could be a cornerstone shortly if surgeons are adequately trained.

The limitations of our study were that it was a single-center study with a small number of patients and a lack of randomization where our distinct surgical technique was used which might not be comparable to other centers and due to the small sample size number of events were also low. These flaws may be overcome by conducting a prospective multi-center trial with a high volume of subjects and with proper randomization.



IOC because of its usefulness in detecting major bile leaks in major hepatic resections and complex bilio-enteric anastomosis, especially in our settings must be more regularly used to identify the hepatobiliary anatomy and related complications, which is so crucial in the outcome of the patients.

## CONCLUSION

An intraoperative cholangiogram is useful to delineate the biliary tract anatomy and identify bile leaks in cases

of difficult biliary anastomosis and liver resection margins intraoperatively which can be controlled in the same setting thus helping to decrease the morbidity of patients.

## ACKNOWLEDGMENT

We would like to thank all the patients involved in this study and our colleagues who tremendously supported us during this period.

## REFERENCES

- Shojaiefard A, Esmaeilzadeh M, Ghafouri A, Mehrabi A. Various techniques for the surgical treatment of common bile duct stones: a meta review. *Gastroenterol Res Pract.* 2009;2009:840208.
- Capussotti L, Ferrero A, Viganò L, Sgotto E, Muratore A, Polastri R. Bile Leakage and Liver Resection Where Is the Risk? *Arch Surg.* 2006;141:690-4.
- Lo CM, Fan ST, Liu CL, Lai EC, Wong J. Biliary Complications After Hepatic Resection Risk Factors, Management, and Outcome. *Arch Surg.* 1998; 133:156-61.
- Nagano Y, Togo S, Tanaka K, et al. Risk factors and management of bile leakage after hepatic resection. *World J Surg.* 2003; 27(6):695-8.
- Guillaud A, Pery C, Campillo B, Lourdaïs A, Laurent S, Boudjema K. Incidence and predictive factors of clinically relevant bile leakage in the modern era of liver resections. *HPB.* 2013; 15(3):224-9.
- Tuysuz U, Aktas H, Batı IB, Emiroglu R. The role of Intraoperative cholangiography (IOC) and methylene blue tests in reducing bile leakage after living donor hepatectomy. *Asian J Surg.* 2021; 44(1): 147-52.
- Takagi K, Umeda Y, Yoshida R, et al. The Outcome of Complex Hepato-Pancreato-Biliary Surgery for Elderly Patients: A Propensity Score Matching Analysis. *Dig Surg.* 2019; 36(4):323-30.
- Kuster GGR, Gilroy S, Graefen M. Intraoperative cholangiography for laparoscopic cholecystectomy. *Surg Gynecol Obstet.* 1993; 176(5):411-7.
- Taguchi Y, Ebata T, Yokoyama Y, Igami T, Sugawara G, Kokuryo T, et al. The determination of bile leakage in complex hepatectomy based on the guidelines of the International Study Group of Liver Surgery. *World J Surg.* 2014 Jan;38(1):168-76.
- Yamashita Y, Hamatsu T, Rikimaru T, Tanaka S, Shirabe K, Shimada M, et al. Bile leakage after hepatic resection. *Ann Surg.* 2001 Jan;233(1):45-50.
- Reed DN, Vitale GC, Wrightson WR, Edwards M, McMasters K. Decreasing mortality of bile leaks after elective hepatic surgery. *Am J Surg.* 2003; 185(4):316-8.
- Spetzler VN, Schepers M, Pinnschmidt HO, Fischer L, Nashan B, Li J. The incidence and severity of post-hepatectomy bile leaks is affected by surgical indications, preoperative chemotherapy, and surgical procedures. *Hepatobiliary Surg Nutr.* 2019; 8(2):101.
- Martin AN, Narayanan S, Turrentine FE, Bauer TW, Adams RB, Stukenborg GJ, et al. Clinical Factors and Postoperative Impact of Bile Leak After Liver Resection. *J Gastrointest Surg.* 2018 Apr;22(4):661-7.
- Bednarsch J, Czigan Z, Heise D, Lang SA, Olde Damink SWM, Luedde T, et al. Leakage and Stenosis of the Hepaticojejunostomy Following Surgery for Perihilar Cholangiocarcinoma. *J Clin Med.* 2020 May 8;9(5):1392.
- Buddingh KT, Nieuwenhuijs VB, Van Buuren L, Hulscher JBF, De Jong JS, Van Dam GM. Intraoperative assessment of biliary anatomy for prevention of bile duct injury: a review of current and future patient safety interventions. *Surg Endosc.* 2011; 25(8):2449.
- Kleinubing DR, Riera R, Matos D, Linhares MM. Selective versus routine intraoperative cholangiography for cholecystectomy. *Cochrane Database Syst Rev.* 2018 Feb 26;2018(2):CD012971.
- Schols RM, Bouvy ND, Masclee AA, van Dam RM, Dejong CH, Stassen LP. Fluorescence cholangiography during laparoscopic cholecystectomy: a feasibility study on early biliary tract delineation. *Surg Endosc.* 2013 May;27(5):1530-6.
- Ishizawa T, Bandai Y, Ijichi M, Kaneko J, Hasagawa K, Kokudo N. Fluorescent cholangiography illuminating the biliary tree during laparoscopic cholecystectomy. *Br J Surg.* 2010;97:1369-77.
- Ishizawa T, Kaneko J, Inoue Y, Takemura N, Seyama Y, Aoki T, et al. Application of fluorescent cholangiography to single-incision laparoscopic cholecystectomy. *Surg Endosc.* 2011 Aug;25(8):2631-6.
- Ishizawa T, Bandai Y, Ijichi M, Kaneko J, Hasegawa K, Kokudo N. Fluorescent cholangiography illuminating the biliary tree during laparoscopic cholecystectomy. *Br J Surg.* 2010 Sep;97(9):1369-77.
- Buddingh KT, Nieuwenhuijs VB, Van Bururen L, Hulscher JB, Dejong JS, Van Dam GM. Intraoperative assessment of biliary anatomy for prevention of bile duct injury: a review of current and future patient safety interventions. *Surg Endosc.* 2011;25:2449-61.
- Jarnagin WR, Schwartz LH. Intraoperative ultrasound in the management of liver tumors. *Ann Surg.* 2001;234(3):290-300.
- Bismuth H, Castaing D. Intraoperative ultrasound in liver surgery. *Br J Surg.* 2002;89(4): 473-4.
- Torzilli G, Makuuchi M. Intraoperative ultrasonography in liver cancer. *Surg Oncol Clin N Am.* 2003 Jan;12(1):91-103.
- Cherqui D, Laurent A, Tayar C. Intraoperative ultrasound and vascular clamping for liver resections. *Am J Surg.* 2006;244(2):194-200.
- Conlon KC, Dougherty EC. Intraoperative ultrasound during hepatobiliary surgery: A review. *Am J Surg.* 2001;182(6):677-84.