

Philtral Column and Nostril Shape Pattern in Nepalese Population: Comparative Study between Two Ethnic Groups of Nepal

Chaurasia NK,¹ Upadhyaya C,¹ Mahantha S,² Upadhyaya S,³ Shakya M,¹ Upreti S,⁴ Bhandari A,¹ Baral I¹

¹Department of Oral and Maxillofacial Surgery

²Department of Community and Public Health Dentistry.

³Department of Pedodontics and Preventive Dentistry

Dhulikhel Hospital, Kathmandu University Hospital, Kathmandu University School of Medical Sciences, Dhulikhel, Kavre, Nepal.

⁴Department of Dentistry, Birta City Hospital, Birtamode, Nepal.

Corresponding Author

Nitesh Kumar Chaurasia

Department of Oral and Maxillofacial Surgery
Dhulikhel Hospital, Kathmandu University Hospital,
Kathmandu University School of Medical Sciences,
Dhulikhel, Kavre, Nepal.

E-mail: drniteshk@gmail.com

Citation

Chaurasia NK, Upadhyaya C, Mahantha S, Upadhyaya S, Shakya M, Upreti S, Bhandari A, Baral I. Philtral Column and Nostril Shape Pattern in Nepalese Population: Comparative Study between Two Ethnic Groups of Nepal. *Kathmandu Univ Med J*. **Online First**.

ABSTRACT

Background

Knowledge of the normal appearance of lip-nose complexes in a particular ethnicity or race helps to plan and modify surgical techniques for their deformity.

Objective

To determine the shape of the philtral column and nostril in children of two ethnic groups (Aryans and Mongoloids) of the Nepalese population and compare them to see if any variation exists.

Method

The present prospective study was carried out between December 2021 to January 2023 among 200 children of age 5-12 years. The children meeting our inclusion criteria were divided equally into Aryan and mongoloid groups based on the caste system in Nepal. Facial photographs were obtained in frontal and basal views. They were analyzed to determine the shape of the philtral column and nostril shape based on Mori's classification system.

Result

Out of 200 children, 123 were males and 77 were females. The most common type of philtral and nostril shape in the Nepalese population was triangular and teardrop respectively. Triangular and concave type philtral shape was predominant in Aryans whereas triangular and parallel type was predominant in Mongoloids however the variation was not significant. Similarly, teardrop nostrils were most common in both ethnic groups.

Conclusion

The results provide a morphological pattern and variation in the philtral and nostril shape in the two major ethnic group of Nepalese population.

KEY WORDS

Aryans, Mongoloids, Nostril shape, Philtral shape

INTRODUCTION

The upper lip nose complex is a major facial esthetic subunit and the shape of philtrum is the center of appearance in human beings. This contributes greatly to the facial appearance.¹ Philtrum is the central part of the upper lip and has an important role in the appearance of the lip and nostril. It has philtral ridge on both sides, philtral dimple, and a white roll between the two picks of the cupid bow.² Any changes in philtral column pattern and shape of the nostril greatly affect the appearance of the face.³ Congenital deformities such as clefts of the orofacial region alters the morphological appearance of these structures and lead to facial disfigurement.³ Knowledge of the normal appearance of the lip-nose complex in a particular ethnicity or race helps to plan and modify surgical techniques in their correction.⁴ Nepalese population broadly comprises two ethnic groups Indo-Aryan and Mongoloid.⁵⁻⁷ Numerous studies have been carried out to determine the upper lip-nose complex morphology in different populations.^{1,4,8} To the best of our knowledge, no such study comparing the two ethnic groups has been carried out in the Nepalese population.

Hence, the present study will determine the morphology of the philtral column and shape of the nostril in children of two ethnic groups of the Nepalese population and compare them to see if there exists any variation. This will help us to plan, modify or improve surgical techniques in the reconstruction of the upper lip-nose complex.

METHODS

The present study was carried out after obtaining ethical clearance from the institutional review board. The study was a prospective study carried out on Nepalese-born children of 5 to 12 years with both parents belonging to the same ethnic group. The study was carried out among children attending the Department of Oral and maxillofacial surgery and the Department of Pedodontics of Dhulikhel Hospital between the period of December 2021 to January 2023. The inclusion criteria were healthy Nepalese-born children with normal growth patterns without any history of trauma to lip nose complex, absence of congenital deformities of the oro-facial or craniofacial region, no existing or past pathology of lip-nose complex, no history of any surgery of lip-nose complex. The subjects not meeting the above criteria were not included in the study.

A simple random sampling method was used to select 200 Children meeting all the inclusion criteria. They were divided equally into two groups. Group A comprised children belonging to Nepalese mongoloid ethnicity and Group B comprised children belonging to Indo-Aryan ethnicity. Children in groups A and B were further divided into male and female categories. The two ethnic groups were identified based on the caste system followed in Nepal.⁶

After obtaining written consent from the parents of the children, digital photographs were taken in frontal and basal view. Frontal view photographs were used for the evaluation of philtrum shape. An evaluation was made by two maxillofacial surgeons blindly. Peaks of the cupid's bow (point cphi-cphi) and the origin of philtral column on either side were marked (point cphs-cphs) as shown in figure 1. The philtral shape was determined using these points. Philtral shape was grouped into four types as described by Mori et al.⁴ Type 1 is a triangle, Type 2 is parallel, Type 3 is concave and Type 4 is flat. Similarly, basal view photographs were used for the evaluation of nostril shape based upon the classification system of Mori et al.⁴ They classified nostril shape into four types teardrop types, heart-shaped types, round types, and triangular types. The demographic data including age, sex, and ethnicity were recorded. The shape of philtrum and nostril was also recorded in a tabulated form.

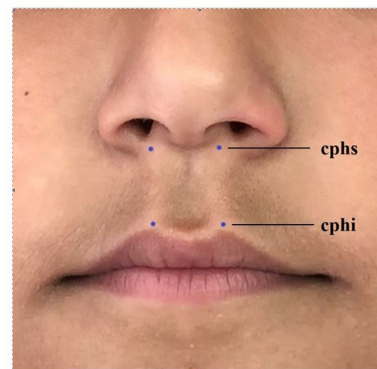


Figure 1. Markings of peak of cupid's bow (cphi) and origin of philtral column (cphs)

The data were entered in an Excel sheet and descriptive statistics were calculated. Statistical differences between the two genders and ethnic groups were analyzed using the chi-square test. P value < 0.05 was considered to be significant. IBM® SPSS statistics® version 25.0 for Windows was used for statistical analysis.

RESULTS

Out of 200 children, 123 were male and 77 were female. The total number of males in Aryan were 58 and female were 42. The number of males in mongoloid ethnic group was 65 and the number of females was

35. The mean age of children in Aryans and mongoloids were 8.55 ± 2.9 and 8.25 ± 2.8 years respectively. The most common pattern of philtral shape in the Nepalese population was triangular (47%) (Fig. 2) whereas teardrop shape nostril (58.5%) (Fig. 3) was the most common nostril shape. The distribution pattern of philtral and nostril shape is shown in table 1 and table 2 respectively. Similarly, in both ethnic groups triangular pattern of philtral shape and teardrop nostril was most common. When we compared both groups in terms of differences in philtral ridge pattern, there were no significant differences statistically. However,

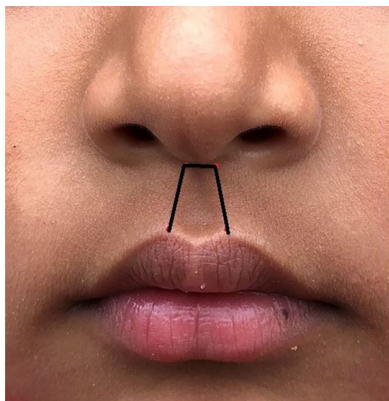


Figure 2. Triangular type of philtral shape

predominant type of philtral shape in Aryans were triangular and concave whereas those in mongoloids were triangular and parallel. The comparison of the distribution pattern of philtral shape in both ethnic groups is shown in table 3. Similarly, the predominant type of nostril shape in Aryans were teardrop followed by triangular whereas those in mongoloids were teardrop followed by round. However, these variations were statistically not significant. Comparison of nostril shape in both ethnic groups is shown in table 4.

Table 1. Distribution Pattern of philtral shape in Nepalese population

| Type of philtral shape | Frequency (N=200) | Percentage (%) |
|------------------------|-------------------|----------------|
| Concave | 48 | 24 |
| Triangular | 94 | 47 |
| Flat | 20 | 10 |
| Parallel | 38 | 19 |

*N = Total number of participants

Table 2. Distribution pattern of nostril shape in Nepalese population

| Type of nostril shape | Frequency (N=200) | Percentage (%) |
|-----------------------|-------------------|----------------|
| Tear drop | 117 | 58.5 |
| Heart-shaped | 19 | 9.5 |
| Triangular | 31 | 15.5 |
| Round | 33 | 16.5 |

*N = Total number of participants

Table 3. Comparison of philtral shape pattern between Aryan and Mongoloid

| Types of philtral shape | Aryans (n=100) | | Mongolians (n=100) | | P value |
|-------------------------|----------------|----|--------------------|----|---------|
| Concave | 27 | 27 | 21 | 21 | 0.305* |
| Triangular | 48 | 48 | 46 | 46 | |

n= Total number of participants in each ethnic group

*= Not significant

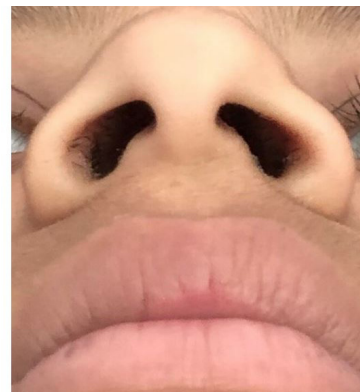

Figure 3. Teardrop shape of nostril

Table 4. Comparison of nostril shape pattern between Aryan and Mongoloid

| Types of nostril shape | Aryans (n=100) | | Mongolians (n=100) | | P value |
|------------------------|----------------|----|--------------------|----|---------|
| | Frequency | % | Frequency | % | |
| Tear drop | 63 | 63 | 54 | 54 | 0.138* |
| Heart shaped | 5 | 5 | 14 | 14 | |

*= Not significant

DISCUSSION

The knowledge of philtral and nostril shape in a particular population is important, especially in esthetic and functional surgery of lip and nose such as in the treatment of cleft lip and nose deformity. This is essential for maxillofacial surgeons, plastic surgeons, and other specialties who are involved in the treatment of upper lip nose deformity. One of the goals in surgery of upper lip nose complex deformity is to recreate a philtral and nostril shape similar to the contralateral side. As it is already known, pre-operative planning and markings are essential parts of cleft lip nose surgery. An ideal repair line should mirror the philtral ridge on the non-cleft side.⁹ Post-surgical philtral and nostril shape also depend on the surgical techniques used to repair the deformity. Rotation advancement techniques and their modifications almost produce the repair line mimicking that on the non-cleft side.¹⁰ These techniques can be further modified by operating surgeons by carefully selecting the markings and techniques to be performed for which the knowledge of philtral and nostril shape in a particular population is important. Various techniques such as laser scanning technique, the use of facial plaster models, photographic analysis, measurements using 3D computed tomography techniques, etc. have been described in the literature.^{1,4} Out of all these techniques, we used photographic assessment due to ease of availability and less expensive. As photographs are 2-dimensional views and magnification varies based on the lens, they have the disadvantage of being less accurate in recording absolute measurements. However, in the present study, we were recording form and shape so the use of 2-D photographs can be justified.

Different studies have found that facial structures race specific characteristics and variation in philtral and nostril shape exists in different population.^{5,11,12} Variations in facial structures can occur between different ethnic groups within the same population.^{5,11} A study conducted in the Japanese population found that the parallel shape of philtral ridge was most common followed by a triangular shape.⁴ Whereas similar study conducted in the Japanese population by different researcher, found that the triangular types were common in males and parallel types were more common in females.³ They concluded that there was a difference in philtral shape patterns in males and females.³ Similarly, a study on the Korean population conducted by Shin et al. also found the parallel type to be most common followed by the triangular type.¹¹

They also found variation in philtral shape between males and females.¹¹ Our results show that there was some variation in philtral shape pattern between males and females of each ethnic group but those variations were not significant.

Recently, a morphometric analysis on medical undergraduates of Nepal was carried out to assess nasal parameters, nostril shape, and philtral shape.¹³ The authors concluded that the triangular shape of philtral column was the most common type.¹³ They did not consider the ethnicity of the involved participants.¹³ Our results are similar to them but our aim was not only to assess the type of philtral and nostril shape in growing children but also to see if there is any variation between the two major ethnic groups of Nepal.

The result of our study is in contrast to the study by Mori et al.⁴ However in terms of philtral shape, there are some similarities to the results by Kishi et al.³ The results of present study did not show significant variation between the Aryans and mongoloids in terms of philtral shape as the triangular type was most common in both of them. Further, the second most common type of philtral shape was concave in Aryans where as it was parallel type in Mongoloids. Although the variation was not statistically significant, the difference existed between the two ethnic groups. Similarly, Bagheri et al. also conducted a study to analyze the philtral shape digitally in their population.¹⁴

They found that the concave type was common in males and both parallel as well as triangular types had an equal incidence in females.¹⁴ The results of the present study are again in contrast to them. Our results are similar to the study conducted by Ibrahim et al in the Nigerian population and Reham et al. in the Jordanian population.^{1,15} They also found that the triangular shape of philtrum was more common in their population.

The shape of nostrils also varies between populations and ethnic groups. The results of our study in terms of nostril shape are not different from the studies conducted on the Japanese and Nigerian populations.^{1,4}

Both the ethnic group in our study had similar results but round shape nostril was the second most common type in mongoloids whereas a triangular type was seen more commonly after the teardrop type in Aryans.

Thus, the study presents the pattern of philtral and nostril shape in our population which will help many surgeons involved in treating upper lip nose complex deformity.

There are some limitations of the present study. The study used contact type point measurements on digital 2-Dimensional photographs. Newer advances like 3-Dimensional photographs, non-contact type measurements using light probe, ultrasonic techniques have shown to be more accurate. The present study did not evaluate the vermilion volume and size of nostril. These parameters are also important in management of upper lip nose complex deformity.

CONCLUSION

One of the greatest challenges for a surgeon involved in the management of upper lip-nose complex deformity is to create a near-normal appearing upper lip and nose. The present study has provided with a morphological pattern and variation in philtral and nostril shape in the Nepalese population taking into consideration both the Aryans and mongoloids ethnic groups in Nepal. We hope that the result of the present study will be beneficial for surgeons in the coming days.

REFERENCES

1. Abdurashed I, Eneye AM. Philtral columns and nostril shapes in nigerian children: a morphometric and aesthetic analysis. *Plast Surg Int.* 2013 June; 2013:382754.
2. Cho BC, Baik BS. Formation of philtral column using vertical interdigitation of orbicularis oris muscle flaps in secondary cleft lip. *Plast Reconstr Surg.* 2000 Oct;106(5):980-6.
3. Kishi N, Tanaka S, Iida S, Kogo M. The morphological features and developmental changes of the philtral dimple: a guide to surgical intervention in cases of cleft lip. *J Cranio-Maxillo-fac Surg.* 2012 Apr;40(3):215-22.
4. Mori A, Nakajima T, Kaneko T, Sakuma H, Aoki Y. Analysis of 109 Japanese children's lip and nose shapes using 3-dimensional digitizer. *Br J Plast Surg.* 2005 Apr;58(3):318-29.
5. Sharma JN. Steiner's cephalometric norms for the Nepalese population. *J Orthod.* 2011 Mar;38(1):21-31.
6. Nepal people, culture and information about sherpas, thakali, kumal, magar, drokpa, brahmin and chhetris, kirati, tamang [Internet]. Nepal:2010. [cited 2021 Aug 16]. Available from: https://www.visitnepal.com/nepal_information/people.php.

7. Pradhan R, Shrestha A. Ethnic and Caste Diversity: Implications for Development. Asian development bank [Internet]. Nepal:2005[cited 2021 Aug 16]. Available from: <https://www.adb.org/sites/default/files/publication/28686/wp4.pdf>
8. Hijazeen RA, Al-Bdour N, Al Jaabary MW, Saayegh O, Al shobakee FM, Ammar H. The Shape of Philtrum Column In Jordanian Population For Its Application In Geometric. *JRMS*. 2019 Dec;26(3):37-47.
9. Fisher DM. Unilateral cleft lip repair: an anatomical subunit approximation technique. *Plast Reconstr Surg*. 2005 Jul;116(1):61-71.
10. Hakim SG, Aschoff HH, Jacobsen HC, Sieg P. Unilateral cleft lip/nose repair using an equal bows /straight line advancement technique – A preliminary report and postoperative symmetry-based anthropometry. *J Cranio-Maxillofac Surg*. 2014 Apr;42(3):e39-45.
11. Shin KJ, Gil YC, Song WC, Koh KS, Choi HG. Morphometric analysis of the upper lip in Koreans. *Facial Plast Surg*. 2014 Oct;30(5):587-92.
12. Farkas LG. Accuracy of anthropometric measurements: past, present, and future. *Cleft Palate-Craniofacial*. 1996 Jan;33(1):19-22.
13. Chalise U, Dhungel S, Chaulagain R. Nasal Parameters, Nostrils Shapes and Philtral Column Shape: A Morphometric Analysis in Nepalese Medical Undergraduate Students. *J Nepal Health Res Counc*. 2019 Jan 28;16(41):462-6.
14. Bagheri H, Sirinturk S, Govsa F, Pinar Y, Ozer MA. Digitalized analysis of philtral anatomy for planning individual treatment. *Surg Radiol Anat*. 2017 Nov;39(11):1183-9.
15. Reham AH, Nayef A, Walaa MA, Odai MS, Fahed A, Hamad A. The Shape of Philtrum Column in Jordanian Population for Its Application In Geometric. *J R Med Serv*. 2019;26(3):37-47.